



**HAL**  
open science

## **Pregnancy after oocyte donation in a patient with NLRP7 gene mutations and recurrent molar hydatidiform pregnancies**

Claire Cozette, Florence Scheffler, Melyne Lombart, Jerome Massardier, Pierre-Adrien Bolze, Touria Hajri, Francois Golfier, Isabelle Toutilou, Cecile Rittore, Jean Gondry, et al.

### ► To cite this version:

Claire Cozette, Florence Scheffler, Melyne Lombart, Jerome Massardier, Pierre-Adrien Bolze, et al.. Pregnancy after oocyte donation in a patient with NLRP7 gene mutations and recurrent molar hydatidiform pregnancies. *Journal of Assisted Reproduction and Genetics*, 2020, 37 (9), pp.2273-2277. 10.1007/s10815-020-01861-z . hal-03548051

**HAL Id: hal-03548051**

**<https://u-picardie.hal.science/hal-03548051>**

Submitted on 13 Jun 2023

**HAL** is a multi-disciplinary open access archive for the deposit and dissemination of scientific research documents, whether they are published or not. The documents may come from teaching and research institutions in France or abroad, or from public or private research centers.

L'archive ouverte pluridisciplinaire **HAL**, est destinée au dépôt et à la diffusion de documents scientifiques de niveau recherche, publiés ou non, émanant des établissements d'enseignement et de recherche français ou étrangers, des laboratoires publics ou privés.

# **Pregnancy after oocyte donation in a patient with NLRP7 gene mutations and recurrent molar hydatidiform pregnancies**

Claire Cozette<sup>1</sup> & Florence Scheffler<sup>1,2</sup> & Melyne Lombart<sup>1</sup> & Jerome Massardier<sup>3</sup> & Pierre-Adrien Bolze<sup>3</sup> & Touria Hajri<sup>3</sup> & Francois Golfier<sup>3</sup> & Isabelle Touitou<sup>4</sup> & Cecile Rittore<sup>4</sup> & Jean Gondry<sup>1</sup> & Philippe Merviel<sup>5</sup> & Moncef Benkhalifa<sup>1,2</sup> & Rosalie Cabry<sup>1,2</sup>

\* Claire Cozette [Cozette.Claire@chu-amiens.fr](mailto:Cozette.Claire@chu-amiens.fr); Florence Scheffler [scheffler.florence@chu-amiens.fr](mailto:scheffler.florence@chu-amiens.fr); Melyne Lombart [lombart.melyne@chu-amiens.fr](mailto:lombart.melyne@chu-amiens.fr); Jerome Massardier [jerome.massardier@chu-lyon.fr](mailto:jerome.massardier@chu-lyon.fr); Pierre-Adrien Bolze [pierre-adrien.bolze@chu-lyon.fr](mailto:pierre-adrien.bolze@chu-lyon.fr); Touria Hajri [touria.hajri@chu-lyon.fr](mailto:touria.hajri@chu-lyon.fr); Francois Golfier [francois.golfier@chu-lyon.fr](mailto:francois.golfier@chu-lyon.fr); Isabelle Touitou [isabelle.touitou@inserm.fr](mailto:isabelle.touitou@inserm.fr); Cecile Rittore [cecile.rittore@inserm.fr](mailto:cecile.rittore@inserm.fr); Jean Gondry [Gondry.jean@chu-amiens.fr](mailto:Gondry.jean@chu-amiens.fr); Philippe Merviel [philippe.merviel@chu-brest.fr](mailto:philippe.merviel@chu-brest.fr); Moncef Benkhalifa [benkhalifamoncef78@gmail.com](mailto:benkhalifamoncef78@gmail.com); Rosalie Cabry [cabry.rosalie@chu-amiens.fr](mailto:cabry.rosalie@chu-amiens.fr).

1 Centre Hospitalier Amiens Sud, Amiens Cedex 1, France

2 Peritox-INERIS, UMR-I 01, Joint Research Centre, Picardie University Jules Verne, Amiens, France

3 Centre Hospitalier Lyon Sud, Lyon, France

4 CHRU, Montpellier, France

5 CHRU, Brest, France

## **Keywords**

Trophoblastic disease . Recurrent hydatidiformmole . Oocyte donation . NLRP7 gene mutation

--

# Abstract

Molar pregnancies are benign trophoblastic diseases associated with a risk of malignant transformation. If aetiology remains mostly unknown, the risk of recurrent molar pregnancy is around 1.5% after one molar pregnancy and around 25% after 2 molar pregnancies. In the later situation, genetic mutations have been described, increasing hugely this risk. In case of mutations, probability to obtain a normal pregnancy is estimated around 1.8%. We report the case of a Caucasian 30-year-old woman whose previous five spontaneous pregnancies had a negative outcome: a spontaneous miscarriage and then 4 complete hydatidiform moles. Genetic testing revealed that the patient carried two heterozygous mutations in the NLRP7 gene (c.2982-2A > G and Y318CfsX7). According to this, counselling was conducted to advocate for oocyte donation in order to obtain a normal pregnancy. This technique enabled a complication-free, singleton pregnancy that resulted in a healthy term live birth of a 2900 g female. Few months after delivery, the patient presented a new complete hydatidiform mole. Women presented with mutations in the NLRP7, KHDC3L or PADI6 genes are unlikely to obtain normal pregnancies, with a major risk of reproductive failure. In such a context, oocyte donation may be the best option. Only 4 normal pregnancies and deliveries have been published in this situation through this technique to our knowledge.

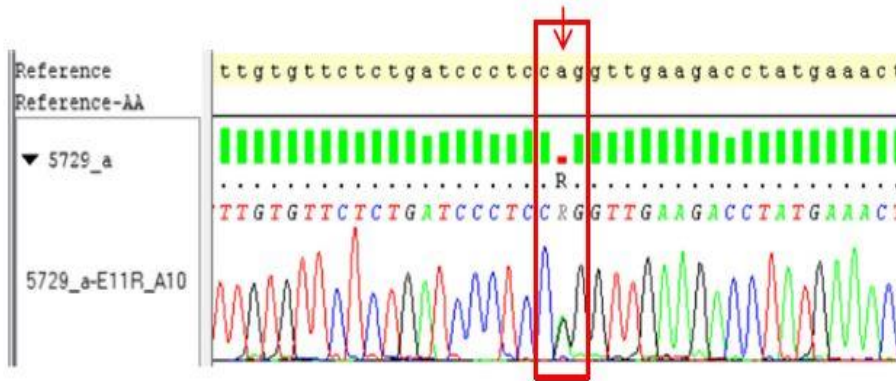
## Introduction

Gestational trophoblastic disease corresponds to a set of placental pathologies characterized by abnormal trophoblastic proliferation and maturation [1]. Within this class of disease, partial and complete hydatidiform moles are considered to be benign conditions. Malignant forms (gestational trophoblastic tumours) include invasive moles, choriocarcinoma, implantation site tumours and epithelioid tumours. It is estimated that around 15% of complete moles and less than 5% of the partial moles will undergo malignant transformation [2]; this is why the fall in (and then disappearance of) blood hCG levels must always be monitored closely after a molar pregnancy has been evacuated [3]. If aetiology remains mostly unknown, the risk of recurrent molar pregnancy is around 1.5% after one molar pregnancy and around 25% after 2 molar pregnancies [4]. In the later situation, genetic mutations have been described, increasing hugely this risk.

## Case report

Here, we report on a 30-year-old French woman (G6P1) whose first pregnancy had ended in a spontaneous miscarriage. The next three pregnancies were marked by the presence of complete hydatidiform moles. These diagnoses were confirmed by an expert pathologist from a reference centre. The mesenchyme and the villous trophoblast stained negative in an immunohistochemical analysis with an anti-p57 antibody. During the course of molar pregnancies, our centre did not have access to molecular genotyping techniques; hence, we were unable to assess the mono- or biparental nature of the molar cells. A survey of the woman's family did not highlight a history of recurrent pregnancy failures.

**NLRP7 (NM\_001127255.1): variant c.2982-2A>G**



**NLRP7 (NM\_001127255.1): variant c.939\_952dup14 p.(Tyr318Cysfs\*7)**

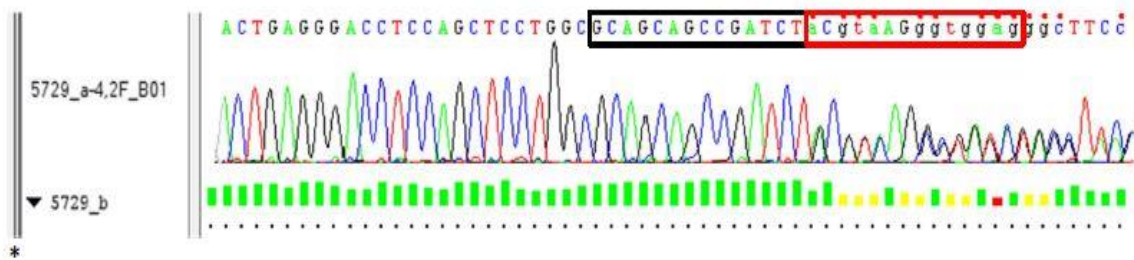


Fig. 1 Sanger sequencing electropherogram: two mutations of NLRP7. At the top is the reference sequence (wild type). The left panel shows the heterozygous change from A (green) to G (black). The right panel shows a duplication of 14 nucleotides resulting in a reading frameshift and a series of superimposed peaks

Sanger sequencing of all exons and intronic boundaries of the NLRP7 gene (known to be associated with a rare, recessive form of recurrent hydatidiform mole) revealed two variants of uncertain significance: c.2982-2A>G with substitution of adenine for guanine predicted to affect splicing and Y318CfsX7 with fourteen base pair duplication in the fourth exon, responsible for a frame shift and premature stop codon (Fig. 1). The parents were not available to ascertain the phase of the two variants (cis or trans).

The partner's sperm parameters were normal. The couple joined an oocyte donation program in our department and was assigned with four mature oocytes. After ICSI, two embryos (rated as 7.2.2 and 6.2.2, according Terrious score) were transferred on day 3. The third embryo was maintained in culture but did not yield blastocyst suitable for freezing. A normal singleton pregnancy was obtained after the embryo transfer. There were no complications, and the pregnancy resulted in the birth (by caesarean section, after the failure of induction) of a baby girl (birthweight, 2.895 kg; term, 41 + 2 weeks of amenorrhea). The patient developed postpartum pre-eclampsia, which resolved without complications after treatment with oral antihypertensive medication. After the delivery, a pathology assessment of the placenta gave normal results. The time course of the postpartum fall in the blood HCG level was normal.

A few months after birth, the female patient presented with a spontaneous pregnancy and the recurrence of a complete hydatidiform mole (confirmed by a pathological analysis). The couple is now waiting for another oocyte donation, after having made a further request.

## Discussion

Complete hydatidiform moles exhibit a diploid karyotype: 46,XX in 75–85% of cases and 46,XY in the remaining cases [5]. In general, a single spermatozoid fertilizes an oocyte having lost its genetic material; the spermatozoid's genetic material is then duplicated (corresponding to diandry). In rare cases, an empty oocyte can be fertilized by two spermatozoids (dispermy) or chromosomal material duplicates in the spermatozoid prior to fertilization (diplospermy) [6].

In the Western countries, the incidences of complete and partial moles are respectively 1 per 1000 and 3 per 1000 pregnancies [7], whereas in South East Asia, the average rate of both disorders are around 8 per 1000 pregnancies [8]. Moreover, one of the main known risk factors for a molar pregnancy is the mother's age (particularly young or advanced) [8]. To date, more than 30 families with recurrent forms of molar pregnancy have been reported [8].

A biparental contribution is observed in these recurrent cases; the woman carries an autosomal recessive mutation that causes the development of complete hydatidiform moles during pregnancy [9]. Homozygous mutations in the NLRP7 [10–12], KHDC3L [13] and PADI6 [14] genes have been identified in this context. The gene products are found in the oocyte cytoskeleton, which explains their complementary roles in oogenesis and embryonic development [15].

The nucleotide-binding oligomerization domain, leucine rich repeat and pyrin domain containing 7 (NLRP7) protein is abundantly expressed in the immune and reproductive systems [16]. Although NLRP7's mechanisms of action are still ill-defined, it appears that the protein regulates the secretion of interleukin 1 $\beta$ —a cytokine involved in folliculogenesis, ovulation, blastocyst implantation and normal placental development [9, 17, 18] and which has an essential role in oocyte imprinting [19, 20]. Parental imprinting enables the exclusive expression of the paternal or maternal allele of a gene, due to particular DNA methylation and histone modification profiles. In fact, it has been shown that paternal allele expression induces trophoblastic proliferation, whereas maternal allele expression counters this influence [21]. Thus, in biparental moles with an NLRP7 or KHDC3L mutation, defective genome imprinting silences maternal gene expression which causes embryo development blocking and defective trophoblast proliferation [8].

It has been shown that biparental complete hydatidiform moles carrying NLRP7 gene mutations have the same morphology, the same immunohistochemistry profile and the same prognosis as conventional diandric complete hydatidiform moles [22]. According to the literature data, there is no risk of malignant degeneration in recurrent forms of complete hydatidiform moles. Moreover, the presence of mutations in a male's NLRP7 gene does not alter spermatogenesis [23]. Lastly, it appears that the presence of a heterozygous NLRP7 mutation also affects a woman's reproductive function by increasing the risk of early spontaneous miscarriage [16, 23, 24].

In female patients with a history of recurrent complete hydatidiform moles, the likelihood of a normal pregnancy is low [25]. However, two spontaneously conceived pregnancies in women with NLRP7 mutations have been reported in the literature; one of the women had a recessive homozygous p.N913S mutation, and the other carried two heterozygous mutations (including p.N913S) on two different chromosomes [26]. Akoury et al. suggested that the occurrence of ongoing pregnancies in these women was related to the type of mutation and the mutations' impact on the NLRP7 protein [26]. However, these cases remain anecdotal, and oocyte donation appears to be the best option for women in this context [27].

The first live birth after oocyte donation was reported in 2011 for a 29-year-old woman carrying a compound heterozygous mutation in the NLRP7 gene and who had previously experienced a miscarriage and three complete molar pregnancies [25]. Successful pregnancies following oocyte donation have also been reported in two women of Indian origin [26]: the first patient (aged 27, carrying a homozygous NLRP7 mutation) became pregnant with twins following the transfer of three embryos. The second patient (aged 26, carrying two heterozygous NLRP7 mutations) achieved a singleton pregnancy. The course of pregnancy was normal in both cases, and both resulted in healthy live births. Recently, an Iranian team described a new homozygote NLRP7 mutation in a woman who had 5 molar pregnancies in her history, in whom oocyte donation allowed successful pregnancy and child birth [28].

## Conclusion

Oocyte donation appears to be the best option for a normal, successful pregnancy in women with a history of recurrent complete hydatidiform moles.

In view of recent advances in molecular genetics, one can hope that in situ gene correction within oocyte's germinal vesicle will one day become an option for managing recurrent hydatidiform moles of biparental origin [29].

### Compliance with ethical standards

Conflict of interest The authors declare that they have no conflict of interest.

## References

1. Gestational trophoblastic diseases. Report of a WHO Scientific Group. World Health Organ Tech Rep Ser. 1983;692:7–81.
2. Lurain JR. Gestational trophoblastic disease I: epidemiology, pathology, clinical presentation and diagnosis of gestational trophoblastic disease, and management of hydatidiform mole. *Am J Obstet Gynecol.* 2010;203:531–9.
3. Bolze P-A, Attia J, Massardier J, Seckl MJ, Massuger L, van Trommel N, et al. Formalised consensus of the European Organisation for Treatment of Trophoblastic Diseases on management of gestational trophoblastic diseases. *Eur J Cancer.* 2015;51(13):1725–31.
4. Allias F, Bolze P-A, Gaillot-Durand L, Devouassoux-Shisheboran M. Gestational trophoblastic disease. *Ann Pathol.* 2014;34(6):434–47.

5. Lawler SD, Fisher RA, Dent J. A prospective genetic study of complete and partial hydatidiform moles. *Am J Obstet Gynecol.* 1991;164(5 Pt 1):1270–7.
6. Fisher RA, Newlands ES. Gestational trophoblastic disease. Molecular and genetic studies. *J Reprod Med.* 1998;43(1):87–97.
7. Seckl MJ, Sebire NJ, Berkowitz RS. Gestational trophoblastic disease. *Lancet.* 2010;376(9742):717–29.
8. Hui P, Buza N, Murphy KM, Ronnett BM. Hydatidiform moles: genetic basis and precision diagnosis. *Annu Rev Pathol.* 2017;12: 449–85.
9. Williams D, Hodgetts V, Gupta J. Recurrent hydatidiform moles. *Eur J Obstet Gynecol Reprod Biol.* 2010;150(1):3–7.
10. Murdoch S, Djuric U, Mazhar B, Seoud M, Khan R, Kuick R, et al. Mutations in NALP7 cause recurrent hydatidiform moles and reproductive wastage in humans. *Nat Genet.* 2006;38(3):300–2.
11. Wang CM, Dixon PH, Decordova S, Hodges MD, Sebire NJ, Ozalp S, et al. Identification of 13 novel NLRP7 mutations in 20 families with recurrent hydatidiform mole; missense mutations cluster in the leucine-rich region. *J Med Genet.* 2009;46(8):569–75.
12. Muhlstein J, Golfier F, Rittore C, Hajri T, Philibert L, Abel F, et al. The spectrum of NLRP7 mutations in French patients with recurrent hydatidiform mole. *Eur J Obstet Gynecol Reprod Biol.* 2011;157(2):197–9.
13. Parry DA, Logan CV, Hayward BE, Shires M, Landolsi H, Diggle C, et al. Mutations causing familial biparental hydatidiform mole implicate c6orf221 as a possible regulator of genomic imprinting in the human oocyte. *Am J Hum Genet.* 2011;89(3):451–8.
14. Qian J, Nguyen NMP, Rezaei M, Huang B, Tao Y, Zhang X, et al. Biallelic PADI6 variants linking infertility, miscarriages, and hydatidiform moles. *Eur J Hum Genet.* 2018;26(7):1007–13.
15. Akoury E, Zhang L, Ao A, Slim R. NLRP7 and KHDC3L, the two maternal-effect proteins responsible for recurrent hydatidiform moles, co-localize to the oocyte cytoskeleton. *Hum Reprod.* 2015;30(1):159–69.
16. Slim R, Wallace EP. NLRP7 and the genetics of hydatidiform moles: recent advances and new challenges. *Front Immunol.* 2013;4:242.
17. Kinoshita T, Wang Y, Hasegawa M, Imamura R, Suda T. PYPAF3, a PYRIN-containing APAF-1-like protein, is a feedback regulator of caspase-1-dependent interleukin-1beta secretion. *J Biol Chem.* 2005;280(23):21720–5.
18. Messaed C, Akoury E, Djuric U, Zeng J, Saleh M, Gilbert L, et al. NLRP7, a nucleotide oligomerization domain-like receptor protein, is required for normal cytokine secretion and co-localizes with Golgi and the microtubule-organizing center. *J Biol Chem.* 2011;286(50):43313–23.

19. Judson H, Hayward BE, Sheridan E, Bonthron DT. A global disorder of imprinting in the human female germ line. *Nature*. 2002;416(6880):539–42.
20. Van den Veyver IB, Al-Hussaini TK. Biparental hydatidiform moles: a maternal effect mutation affecting imprinting in the offspring. *Hum Reprod Update*. 2006;12(3):233–42.
21. Slim R, Mehio A. The genetics of hydatidiform moles: new lights on an ancient disease. *Clin Genet*. 2007;71(1):25–34.
22. Sebire NJ, Savage PM, Seckl MJ, Fisher RA. Histopathological features of biparental complete hydatidiform moles in women with NLRP7 mutations. *Placenta*. 2013;34(1):50–6.
23. Qian J, Deveault C, Bagga R, Xie X, Slim R. Women heterozygous for NLRP7/NLRP7 mutations are at risk for reproductive wastage: report of two novel mutations. *Hum Mutat*. 2007;28(7):741.
24. Soellner L, Begemann M, Degenhardt F, Geipel A, Eggermann T, Mangold E. Maternal heterozygous NLRP7 variant results in recurrent reproductive failure and imprinting disturbances in the offspring. *Eur J Hum Genet*. 2017;25(8):924–9.
25. Fisher RA, Lavery SA, Carby A, Abu-Hayyeh S, Swingler R, Sebire NJ, et al. What a difference an egg makes. *Lancet*. 2011;378(9807):1974.
26. Akoury E, Gupta N, Bagga R, Brown S, Déry C, Kabra M, et al. Live births in women with recurrent hydatidiform mole and two NLRP7 mutations. *Reprod BioMed Online*. 2015;31(1):120–4.
27. Sills ES, Obregon-Tito AJ, Gao H, McWilliams TK, Gordon AT, Adams CA, et al. Pathogenic variant in NLRP7 (19q13.42) associated with recurrent gestational trophoblastic disease: data from early embryo development observed during in vitro fertilization. *Clin Exp Reprod Med*. 2017;44(1):40–6.
28. Fallahi J, Razban V, Momtahan M, Akbarzadeh-Jahromi M, Namavar-Jahromi B, Anvar Z, et al. A novel mutation in NLRP7 related to recurrent hydatidiform mole and reproductive failure. *Int J Fertil Steril*. 2019;13(2):135–8.
29. Kalogiannidis I, Kalinderi K, Kalinderis M, Miliaras D, Tarlatzis B, Athanasiadis A. Recurrent complete hydatidiform mole: where we are, is there a safe gestational horizon? Opinion and mini-review. *J Assist Reprod Genet*. 2018;35(6):967–73.