



Long-term follow-up of a patient with type 2 Timothy syndrome and the partial efficacy of mexiletine

Alexis Hermida, Guillaume Jedraszak, Maciej Kubala, Amel Mathiron, Pascal Berna, Youssef Bennis, Jean-Sylvain Hermida

► To cite this version:

Alexis Hermida, Guillaume Jedraszak, Maciej Kubala, Amel Mathiron, Pascal Berna, et al.. Long-term follow-up of a patient with type 2 Timothy syndrome and the partial efficacy of mexiletine. Gene, 2021, 777, 10.1016/j.gene.2021.145465 . hal-03564793

HAL Id: hal-03564793

<https://u-picardie.hal.science/hal-03564793>

Submitted on 13 Feb 2023

HAL is a multi-disciplinary open access archive for the deposit and dissemination of scientific research documents, whether they are published or not. The documents may come from teaching and research institutions in France or abroad, or from public or private research centers.

L'archive ouverte pluridisciplinaire **HAL**, est destinée au dépôt et à la diffusion de documents scientifiques de niveau recherche, publiés ou non, émanant des établissements d'enseignement et de recherche français ou étrangers, des laboratoires publics ou privés.



Distributed under a Creative Commons Attribution - NonCommercial 4.0 International License

Long-Term Follow-up of a Patient with Type 2 Timothy Syndrome and the Partial Efficacy of Mexiletine

Alexis Hermida MD^a, Guillaume Jedraszak MD, PhD^{b,c}, Maciej Kubala, MD, PhD^a, Amel Mathiron MD^d, Pascal Berna MD^e, Youssef Bennis MD^f, and Jean-Sylvain Hermida MD^a

^aCardiology, Arrhythmia, and Cardiac Stimulation Service, Amiens-Picardie University Hospital, Amiens, France

^bMolecular Genetics Laboratory, Amiens-Picardie University Hospital, Amiens, France

^cEA4666 HEMATIM, University of Picardie-Jules Verne, Amiens, France

^dPediatric Cardiology Department, Amiens-Picardie University Hospital, Amiens, France

^eDepartment of Thoracic Surgery Service, Amiens-Picardie University Hospital, Amiens, France

^fLaboratory of Pharmacology and Toxicology, Amiens-Picardie University Hospital, Amiens, France

Corresponding Author

Dr Alexis HERMIDA Cardiology, Arrhythmia, and Cardiac Stimulation Service, Amiens-Picardie University Hospital, Amiens, France

1, Rue du Professeur Christian Cabrol 80480 Amiens, France

Phone: +33 322 45 58 75

Fax: +33 322 45 56 58

Email: a.hermida.jarry@gmail.com

Conflict of interest: none declared

ABSTRACT

We report a detailed case of type 2 TS due to a p.(Gly402Ser) mutation in exon 8 of the *CACNA1C* gene. The patient shows a marked prolongation of repolarization with a mean QTc of 540 ms. He shows no structural heart disease, syndactyly, or cranio-facial abnormalities. However, he shows developmental delays, without autism, and dental abnormalities. The cardiac phenotype is very severe, with a resuscitated cardiac arrest at 2.5 years of age, followed by 26 appropriate shocks during nine years of follow-up. Adding mexiletine to nadolol resulted in a reduction of the QTc and a slight decrease in the number of appropriate shocks.

KEYWORDS

Left cardiac sympathetic denervation

Long QT Syndrome

Mexiletine

Timothy Syndrome

INTRODUCTION

A severe variant of Timothy syndrome (TS), type 2 TS, was described in two patients who presented with long-QT syndrome, but without syndactyly, in 2005¹. One carried a p.(Gly406Arg) and the other a p.(Gly402Ser) mutation in exon 8 of the cardiac L-type calcium channel (*CACNA1C*) gene.

Type 2 TS is extremely rare and current knowledge is based on reported clinical cases. We have followed a young patient with the type 2 TS p.(Gly402Ser) mutation for nine years at the Amiens University Hospital. During this long-term follow up, the patient has received various treatments combined with very close monitoring, making it possible to obtain highly precise data.

We obtained parental permission to report this exceptional case.

CLINICAL CASE

Initial presentation

In December 2010, a 32-month-old boy had a resuscitated cardiac arrest at home. Cardiovascular examination upon entry to the intensive care unit and echocardiography were normal. An ECG showed an incomplete right bundle branch block. The QT corrected by Bazett's formula (QTcB) was between 460 and 475 ms, leading to the diagnosis of congenital long-QT syndrome. On day 2, beta-blocker treatment was initiated by the administration of nadolol (Nad). The patient showed clinical anoxic sequelae confirmed by cerebral MRI.

Etiological inquiry

The patient was born at term. He is the second child of a non-related couple originating from the Maghreb.

On examination, the child showed no dysmorphic features, and the extremities were normal. There was no history of heart disease, channelopathy, or sudden cardiac death in his family. A 2-mm ST-segment elevation was temporarily recorded through lead V1 (Figure 1A) in January 2011, evoking a Brugada ECG aspect and the diagnosis of an overlapping type 3 long-QT syndrome. The *SCN5A* gene was thus genotyped by the Sanger method in 2011 but no *SCN5A* mutation was found. This ST-segment elevation could have been caused by transient myocardial ischemia resulting from the initial resuscitation from cardiac arrest. In 2016, next-generation sequencing was performed with a 51-gene panel. The mutation c.1204G>A; p.(Gly402Ser) was identified in the heterozygous state in exon 8 of the *CACNA1C* gene, leading to the diagnosis of type 2 TS. This mutation was present in the blood and saliva.

Family Inquiry

ECGs of the father, mother, paternal grandparents, younger brother, and half-sister did not show prolongation of the QT interval or Brugada type ST elevation.

We did not identify a p.(Gly402Ser) mutation in the *CACNA1C* gene or any other mutation in the 51-gene panel, neither for the father nor the mother. Analyses were performed on DNA extracted from blood and saliva samples and allowed us to also exclude a low level of mosaicism for the p.(Gly402Ser) mutation. The parents do not carry the mutation in the two tissues studied and no family member had similar cardiological features. Thus, the mutation was considered to be de novo.

Treatment and phenotypic evolution during follow up (Figure 2)

After the initial cardiac arrest, the patient was treated with Nad and a cardioverter defibrillator (ICD) was implanted after a sternotomy. Two atrial electrodes were attached to the right atria and two ventricular electrodes to the right ventricle. An endothoracic coil was positioned and fixed in the left intercostal space. After 22 months on Nad alone, we added flecainide (Fleca). This drug was rapidly discontinued and mexiletine (Mex) introduced and used for 11 months, until the end of 2013, at which point we decided to perform left cardiac sympathetic denervation (LCSD). At the same time, we initiated atrial overdrive pacing at 100/min and left the child on Nad alone. In September 2015, Mex was reintroduced to the ongoing Nad therapy, which was still the treatment received by the child at the last follow-up.

Late psychomotor acquisition was noted by neurologists and attributed both to the type 2 TS and the initial anoxic harm to the brain. The neurological disorders worsened over time, necessitating care of the child in increasingly specialized educational structures. There was no sign of autism.

1 Gingival abnormalities and those of implantation of the teeth have appeared with age
2 and may correspond to dysmorphic features linked to the syndrome.

3 We observed an increase in the PR interval over time, with an initial value of 140 ms,
4 which is currently 240 ms. The patient has never shown a high-degree AV block.

5

Effectiveness of the various therapies

In total, the patient received 26 appropriate shocks (Figure 1B) since the first implantation during a follow up period of nine years.

The mean QTcB on Nad + Mex (Figure 1C) was 550 ± 17 ms, shorter than when he was on Nad alone (575 ± 18 ms, $p < 0.001$) or Nad + Fleca (566 ± 12 ms, $p = 0.002$).

The patient received one shock every 3.7 months when he was on Nad alone (2 periods of 22 months), whereas he received one shock every five months while on Nad + Mex (one period of 11 months and one period of 50 months). While on Fleca, the patient received two shocks over four months.

Before the LCSD, the patient received one shock every three months, whereas he received one shock every five months after the procedure.

DISCUSSION

Reported cases of type 2 TS with the p.(Gly402Ser) mutation

The first described case¹ of type 2 TS with the p.(Gly402Ser) mutation in exon 8A was that of a man with long-QT syndrome, mental retardation, and cranio-facial abnormalities. He experienced a first cardiac arrest at four years of age, leading to the diagnosis of long-QT syndrome. He then experienced three additional cardiac arrests over the next six years. A pacemaker was implanted and then upgraded to a defibrillator at 11 years of age after another cardiac arrest. Significant brain damage remained after this episode. By the age of 21 years, the patient had received more than 20 appropriate shocks. Only a small mutant peak was detected in oral mucosa DNA, indicating mosaicism, which could explain the milder phenotype of this individual. The patient is alive at 30 years of age.

Two sibling carriers of the p.(Gly402Ser) mutation were described in 2014 by Fröhler et al.². The mutation was inherited from their father, a mosaic mutation carrier. Patient 1 presented cardiac arrest at the age of two months and a defibrillator was implanted at the age of four years. He had received two appropriate shocks since then and was eight years old at the time of publication. Patient 2 developed ventricular fibrillation at the age of three years and a defibrillator was immediately implanted. By six years of age, he had already received more than 40 appropriate shocks.

A fourth case of type 2 TS with the p.(Gly402Ser) mutation was reported in 2015 by Hiippala et al.³, with a teenage patient resuscitated from VF at the age of 13. She was treated with an implantable cardioverter defibrillator. She has no syndactyly and showed normal neurodevelopment. Surprisingly, the QTc interval only ranged from between 440 and 480 ms and the patient did not receive any therapy during 3.5 years of follow-up. This mild phenotype cannot be explained by mosaicism.

1 The case we report, the fifth mentioned in the literature, presents a severe cardiac
2 phenotype and developmental delays, without autism. The patient is alive and is currently 12
3 years of age. Neurological disorders can also be of post anoxic origin, and, thus, this case
4 could be considered as one of aborted TS.

5

6

Therapeutic management in TS

A positive effect of Mex in type 1 TS was first reported by Gao et al.⁴ Such an effect of Mex is explained by its action on late sodium current ($I_{Na,L}$) inhibition. A second case was reported in 2017 by Tunca et al.⁵, showing significant shortening of repolarization with Mex (15 mg/kg/d) in a type 1 TS patient. We observed shortening of the QTc in our patient on Mex. The patient appeared to present less ventricular arrhythmia with Mex than with Nad alone, but the number of shocks remained high (1 shock every 5 months vs. 1 shock every 3.7 months).

Ranolazine inhibits $I_{Na,L}$ and $I_{Ca,L}$ and its in vitro efficacy was reported in 2007.⁶ A case report was later published by Shah et al. in 2012⁷, in which a type 2 TS patient with the p.(Gly402Ser) mutation was successfully treated with ranolazine. This drug has not yet been tested in the case we present here.

LCSD appears to have been effective in our patient but was not reported in the four other cases of type 2 TS found in the literature. We can hypothesize that bilateral sympathetic denervation could have been even more efficient, as demonstrated for electrical storm, but decided to temporize the treatment, as the number of events is currently acceptable.

Atrial pacing was started to shorten repolarization and test overdrive suppression. The effect of atrial overdriving pacing is difficult to estimate as it was initiated after the LCSD and in the context of Mexiletine treatment. However, at the time of the ICD replacement, sinus bradycardia was observed during the short period of time in which the ICD was disconnected during its replacement, rapidly followed by the onset of VF, which was defibrillated. We thus decided to continue atrial pacing.

1 This type of rare syndrome presents numerous challenges to keeping the patient alive.
2 First, it is necessary to establish the correct diagnosis, which is facilitated by next-generation
3 sequencing. It is also important to know whether there is a degree of mosaicism, as it has an
4 impact on the phenotype. Second, there is the technical challenge of the ICD implantation.
5 Third, the clinician needs to find the correct association for therapeutic management by
6 combining drugs (beta blockers, mexiletine) and eventually atrial pacing and/or LCSD.
7 Patients and their families should be informed about the difficulties encountered in
8 successfully completing these steps. We hope that this case will help clinicians faced with this
9 type of rare inherited cardiac disease, in particular, calmodulinopathies (CALM), in which
10 aberrant calcium influx through compromised voltage-gated L-type calcium channels
11 (Cav1.2) leads to an increased duration of the action potential and a long QT-syndrome
12 phenotype. Thus, certain CALM patients have features similar to those with TS, with the
13 same difficulties of management.

CONCLUSION

We report a detailed case of type 2 TS due to a p.(Gly402Ser) mutation in exon 8 of the *CACNA1C* gene. The cardiac phenotype is very severe. Adding mexiletine to nadolol resulted in a reduction of the QTc and a slight decrease in the number of appropriate shocks during a long-term follow up of nine years.

FUNDING

No funding sources.

1 REFERENCES

- 2 1. Splawski I, Timothy KW, Decher N, et al. Severe arrhythmia disorder caused by cardiac
3 L-type calcium channel mutations. *Proc Natl Acad Sci USA*. 2005;102(23):8089-8096;
4 discussion 8086-8088. doi:10.1073/pnas.0502506102
- 5 2. Fröhler S, Kieslich M, Langnick C, et al. Exome sequencing helped the fine diagnosis of
6 two siblings afflicted with atypical Timothy syndrome (TS2). *BMC Med Genet*.
7 2014;15:48. doi:10.1186/1471-2350-15-48
- 8 3. Hiippala A, Tallila J, Myllykangas S, Koskenvuo JW, Alastalo T-P. Expanding the
9 phenotype of Timothy syndrome type 2: an adolescent with ventricular fibrillation but
10 normal development. *Am J Med Genet A*. 2015;167A(3):629-634.
11 doi:10.1002/ajmg.a.36924
- 12 4. Gao Y, Xue X, Hu D, et al. Inhibition of late sodium current by mexiletine: a novel
13 pharmacotherapeutical approach in timothy syndrome. *Circ Arrhythm Electrophysiol*.
14 2013;6(3):614-622. doi:10.1161/CIRCEP.113.000092
- 15 5. Tunca Sahin G, Ergul Y. A case report: Is mexiletine usage effective in the shortening of
16 QTC interval and improving the T-wave alternans in Timothy syndrome? *Ann*
17 *Noninvasive Electrocardiol*. 2018;23(3):e12522. doi:10.1111/anec.12522
- 18 6. Sicouri S, Timothy KW, Zygmunt AC, et al. Cellular basis for the electrocardiographic
19 and arrhythmic manifestations of Timothy syndrome: effects of ranolazine. *Heart Rhythm*.
20 2007;4(5):638-647. doi:10.1016/j.hrthm.2006.12.046
- 21 7. Shah DP, Baez-Escudero JL, Weisberg IL, Beshai JF, Burke MC. Ranolazine safely
22 decreases ventricular and atrial fibrillation in Timothy syndrome (LQT8). *Pacing Clin*
23 *Electrophysiol*. 2012;35(3):e62-64. doi:10.1111/j.1540-8159.2010.02913.x

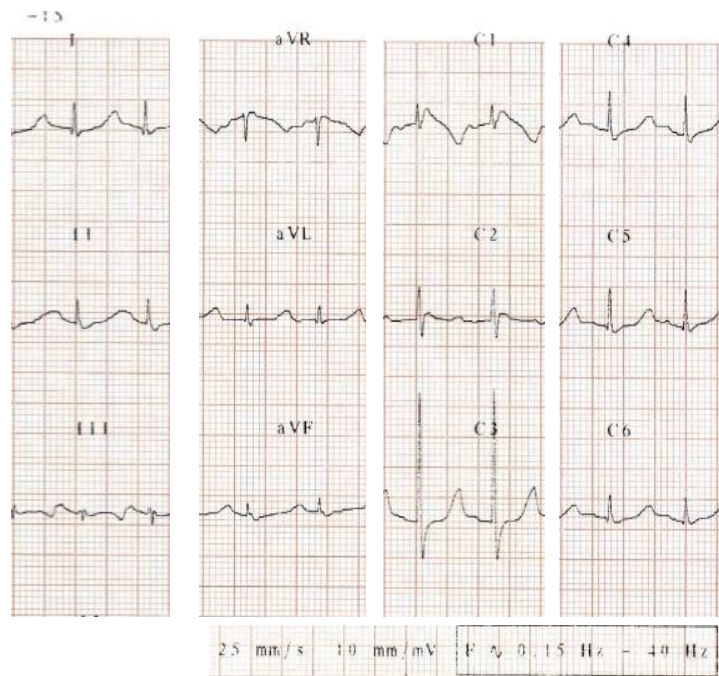
FIGURE LEGENDS

Figure 1. A. ECG recorded one month after the cardiac arrest. B. Example of the onset and appropriate treatment of a ventricular arrhythmia by the ICD. C. ECG on nadolol + mexiletine.

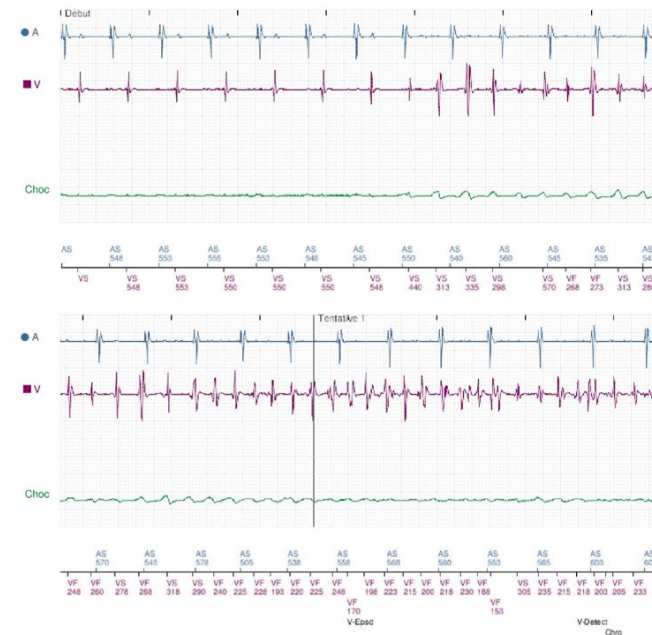
Figure 2. Timeline of the nine-year follow-up.

CA: cardiac arrest, Fleca: flecainide, ICD: implantable cardioverter defibrillator, LCSD: left cardiac sympathetic denervation, Mex: mexiletine, Nad: nadolol, ⚡: ICD discharge

A



B



C

