



HAL
open science

Basic ultrasound head-to-toe skills for intensivists in the general and neuro intensive care unit population: consensus and expert recommendations of the European Society of Intensive Care Medicine

Chiara Robba, Adrian Wong, Daniele Poole, Ashraf Al Tayar, Robert T. Arntfield, Michelle S. Chew, Francesco Corradi, Ghislaine Doufle, Alberto Goffi, Massimo Lamperti, et al.

► To cite this version:

Chiara Robba, Adrian Wong, Daniele Poole, Ashraf Al Tayar, Robert T. Arntfield, et al.. Basic ultrasound head-to-toe skills for intensivists in the general and neuro intensive care unit population: consensus and expert recommendations of the European Society of Intensive Care Medicine. *Intensive Care Medicine*, 2021, 47 (12), pp.1347-1367. 10.1007/s00134-021-06486-z . hal-03584064

HAL Id: hal-03584064

<https://u-picardie.hal.science/hal-03584064>

Submitted on 30 May 2022

HAL is a multi-disciplinary open access archive for the deposit and dissemination of scientific research documents, whether they are published or not. The documents may come from teaching and research institutions in France or abroad, or from public or private research centers.

L'archive ouverte pluridisciplinaire **HAL**, est destinée au dépôt et à la diffusion de documents scientifiques de niveau recherche, publiés ou non, émanant des établissements d'enseignement et de recherche français ou étrangers, des laboratoires publics ou privés.




Distributed under a Creative Commons Attribution - NonCommercial 4.0 International License

CONSENSUS AND EXPERT RECOMMENDATION



Basic ultrasound head-to-toe skills for intensivists in the general and neuro intensive care unit population: consensus and expert recommendations of the European Society of Intensive Care Medicine

Chiara Robba^{1,2*} , Adrian Wong³, Daniele Poole⁴, Ashraf Al Tayar⁵, Robert T. Arntfield⁶, Michelle S. Chew⁷, Francesco Corradi^{8,9}, Ghislaine Douflé¹⁰, Alberto Goffi¹¹, Massimo Lamperti¹², Paul Mayo¹³, Antonio Messina¹⁴, Silvia Mongodi¹⁵, Mangala Narasimhan¹⁶, Corina Puppo¹⁷, Aarti Sarwal¹⁸, Michel Slama¹⁹, Fabio S. Taccone²⁰, Philippe Vignon²¹, Antoine Vieillard-Baron^{22,23} and The European Society of Intensive Care Medicine task force for critical care ultrasonography^{*24*}

© 2021 The Author(s)

Abstract

Purpose: To provide consensus, and a list of experts' recommendations regarding the basic skills for head-to-toe ultrasonography in the intensive care setting.

Methods: The Executive Committee of the European Society of Intensive Care (ESICM) commissioned the project and supervised the methodology and structure of the consensus. We selected an international panel of 19 expert clinicians–researchers in intensive care unit (ICU) with expertise in critical care ultrasonography (US), plus a non-voting methodologist. The panel was divided into five subgroups (brain, lung, heart, abdomen and vascular ultrasound) which identified the domains and generated a list of questions to be addressed by the panel. A Delphi process based on an iterative approach was used to obtain the final consensus statements. Statements were classified as a strong recommendation (84% of agreement), weak recommendation (74% of agreement), and no recommendation (less than 74%), in favor or against.

Results: This consensus produced a total of 74 statements (7 for brain, 20 for lung, 20 for heart, 20 for abdomen, 7 for vascular Ultrasound). We obtained strong agreement in favor for 49 statements (66.2%), 8 weak in favor (10.8%), 3 weak against (4.1%), and no consensus in 14 cases (19.9%). In most cases when consensus was not obtained, it was felt that the skills were considered as too advanced. A research agenda and discussion on training programs were implemented from the results of the consensus.

Conclusions: This consensus provides guidance for the basic use of critical care US and paves the way for the development of training and research projects.

Keywords: Ultrasonography, Intensive care unit, Consensus, Brain ultrasound, Echocardiography, Lung ultrasound, Abdominal ultrasound, Vascular ultrasound

*Correspondence: European Society of Intensive Care Medicine (ESICM),
19 Rue Belliard, Brussels 1040, Belgium
Full author information is available at the end of the article

Introduction

Critical care ultrasonography (US) has become an essential component of the evaluation and clinical management of patients admitted to the intensive care unit (ICU) [1–5].

A wide number of training programs have been developed for different organ systems and clinical applications [4–7]. At present, however, the skills and competencies required for intensivists have not yet been established.

To address this issue, we created an international consensus of experts, commissioned by the European Society of Intensive Care Medicine (ESICM).

The aim of this consensus is to provide a list of experts' recommendations regarding the basic skills for “head to toes” ultrasonography in the intensive care setting. In particular, the experts were asked to consider the skills that each intensivist should acquire for a basic ultrasound-based evaluation of ICU patients, considering different clinical contexts of patients admitted to a mixed general-neuro ICU, including medical and surgical population, but excluding cardiac and major not cardiac surgery (such as thoracic surgery).

Methods

A multidisciplinary international consensus panel including 19 intensivists from 10 countries was selected and divided in 5 subgroups, each one addressing different competences: brain, heart, thoracic, abdominal and vascular ultrasound, plus a transversal subgroup dedicated to the teaching and training for each domain (Electronic Supplementary material 1(ESM)). We used a Delphi method structured with web-based questionnaires aimed at obtaining the opinions of the panel members. The objective of the consensus process was to reduce the heterogeneity of different points of view to reach, in the end, the highest possible degree of convergence. At the end of the voting process, the questions were converted into recommendations. After each round and before the next one, the aggregate results (percentage distribution for each question) were provided to the group to have a clear idea of the overall opinion on each question.

Details regarding the panel selection criteria, definition of the statements, Delphi process and methodology are presented in the ESM1. A summary of the statements is available in Fig. 5.

Results

A total of 74 statements were produced: 7 for brain, 20 for lung, 20 for heart, 20 for abdomen, 7 for vascular US (Table Suppl 1(a–c)).

It is important to highlight that the clinical application of US modalities in different settings and scenarios for different scenarios requires basic knowledge of physics of US and anatomy and training in US modalities, knowledge of standards of measure and competence in reporting and obtaining and interpreting high quality images. Limitations, main parameters to be assessed, key points, and required training as well as research agenda for each

Take-home message

Ultrasonography is an evolving skill in critically ill patients. We provide a large number of statements regarding the required ultrasonographic basic skills for the management of critically ill patients.

subgroup are presented in Tables 1, 2, and Tables S1–S4. Additional images and explanatory cases descriptions for each organ system are presented in ESM2–ESM6.

Brain

Item 1. Triage or clinical suspicion for intracranial hypertension (ESM 2, Video S1, Figure S1)

- We **recommend** B-mode Transcranial color-coded duplex (TCCD) insonation of the middle cerebral artery as basic skill for the qualitative waveforms analysis and to measure pulsatility index to rule out intracranial hypertension impairing cerebral perfusion (*weak recommendation*).
- We are **unable to provide recommendation** regarding the use of optic nerve sheath diameter (ONSD) as a basic skill for intensivists to rule out intracranial hypertension (*no recommendation*).

Background Intracranial hypertension (ICHT) is a frequent complication of brain injury and an important determinant of poor outcome [8]. Invasive monitoring of intracranial pressure requires time, organization, expertise for its placement, and may have some contraindications [9]. Non-invasive methods based on cerebral US could be used to rule out patients with ICHT (including the measurement of pulsatility index and diastolic flow velocities through transcranial Doppler, TCD, Transcranial color-coded duplex, TCCD, or ONSD) [9, 10]. The benefit of TCCD is that it allows visualization and identification of blood vessels for pulse Doppler gate placement. This can be performed by echo probes on a TCD preset available in most point of care ultrasound machines readily accessible in most ICUs (Fig. 1) (ESM1 Figure S1). Although ONSD is a promising technique for ICHT detection and some validation studies have been performed [9, 10], it was considered as a too advanced skill by some experts and no consensus was obtained.

Item 2. Clinical suspicion of brain death (ESM 2, Figure S2)

- We are **unable to provide recommendation** regarding the use of TCD/TCCD to recognize patterns suggesting impending cerebral circulatory arrest (*no recommendation*).

Background Brain death is a clinical diagnosis which requires the evidence of absent brain and brainstem func-

Table 1 Summary of studies assessing training programs to reach competence in basic* CCU

Ultrasound modality/ examined organs	Year, number of patients	Number of trainees/ background	Novice in US	Didactic teaching/ hands on	Number of examinations by trainee/ study duration	Training using computerized simulation	Agreement with expert
Basic TTE/ heart	2007 [16]	4 residents/ anesthesiology Medicine	Yes	3 h/5 h	Mean: 15 (range: 11–20) 6 months	No	LV systolic dysfunction: 0.76 ± 0.09 (0.59–0.93) ^b LV dilatation: 0.66 ± 0.12 (0.43–0.90) RV dilatation: 0.71 ± 0.12 (0.46–0.95) Pericardial effusion: 0.68 ± 0.18 (0.33–1.03)
	2011 [17]	6 residents/ anesthesiology Medicine	Yes	4 h/6 h 2 h cases	Mean: 33 (range: 29–38) 6 months	No	LV systolic function: 0.84 (0.76–0.92) ^b LV dilatation: 0.90 (0.80–1.0) RV dilatation: 0.76 (0.64–0.89) IVC dilatation: 0.79 (0.63–0.94) Respiratory variation of IVC size: 0.66 (0.43–0.89) Pericardial effusion: 0.79 (0.58–0.99) Tamponade: 1 (1–1)
	2016 [18] ^a	5 residents (program I) 6 residents (program II) Critical care	Yes	Program I: 1.5 h/2 h 1 h cases Program II: 1.5 h/3 h 2 h cases	Program I: Mean: 27 Program II: Mean: 26 12 months	No	Program I Program II LV systolic dysfunction: 0.75 (0.64–0.86) 0.77 (0.66–0.88) ^b Heterogeneous LV contraction: 0.55 (0.38–0.72) 0.49 (0.33–0.65) RV dilatation: 0.46 (0.27–0.65) 0.67 (0.54–0.80) Pericardial effusion: 0.83 (0.67–0.99) 0.76 (0.60–0.93) Respiratory variation of IVC size: 0.53 (0.30–0.77) 0.27 (0.09–0.45) Significant mitral regurgitation: 0.42 (0.01–0.84) 0.64 (0.40–0.87) Significant aortic regurgitation: -0.02 (–0.04 to 0) 1
	2020 [19] ^a	7 residents Critical care	Yes	38 h/30 tutored scans	Mean: 39 5 months	Yes	LV systolic dysfunction: 0.77 (0.65–0.89) ^b RV size: 0.76 (0.59–0.93) Pericardial effusion: 0.32 (0.09–0.56) IVC size: 0.56 (0.45–0.68)
	2018 [15]	12 residents (intervention group) 12 residents (control group) Anesthesiology Medicine	Yes	Both groups: 4 h/6 h 2 h cases Simulation: 12 h	Intervention group: Mean: 35 ± 3 Control group: Mean: 39 ± 3 6 months	Intervention group: yes Control group: no	Skills assessment score (maximal: 54 points; intervention vs control group): Month 1: 41.5 ± 5.0 vs 32.3 ± 3.7 ($p=0.0004$) Month 3: 45.8 ± 2.8 vs 42.3 ± 3.7 ($p=0.02$) Month 4: 49.7 ± 1.2 vs 50.0 ± 2.7 ($p=0.64$) Mean number of TTE for competency: 30 ± 9 vs 36 ± 7 ($p=0.01$) LV systolic function and size, homogeneity of LV contraction, RV systolic function and size, pericardial effusion, IVC size, left-sided valvular regurgitation
	2013 [21]	18 residents Critical care	Yes (72%)	8 h/15 h	21 ± 20	No (only for assessment of proficiency)	Skills assessment score (maximal: 40 points): mean 84% (range: 71–97%) LV systolic function (binary response), RV systolic function (binary response), pericardial effusion (binary response), volume status
	2013 [20] ^a	7 residents Critical care	Yes	5 h/3 h	Mean: 15 (range: 5–31) 1 month	No	LV systolic function: 0.67 ^b Regional wall motion abnormality: 0.49 Pericardial effusion: 0.60 Valvulopathy: 0.50–0.54
	2016 [22]	6 residents 36 ICU patients	Critical care	Yes	8 h/8 h	20 per trainee	No

Table 1 (continued)

Ultrasound modality/examined organs	Year, number of patients	Number of trainees/background	Novice in US	Didactic teaching/hands on	Number of examinations by trainee/study duration	Training using computerized simulation	Agreement with expert
	2005 [23] 90 ICU patients	6 physicians Critical care	Yes	10 h total	9 months	No	Agreement with expert for interpretation: 84% LV systolic function and size, regional wall motion abnormality, pericardial effusion
	2014 [24] 318 ICU patients	7 fellows Critical care	No	10 h/–	Median: 40 (range: 34–105) 12 months	No	Diagnosis capacity: predefined criteria for acceptability of the examination Average proportion of acceptable findings: 70% before 10 examinations to 92% after 30 examinations ($p < 0.001$) LV systolic function, severe acute core pulmonale, pericardial effusion, IVC size, mitral regurgitation
	2017 [25]	27 trainees (junior, senior, specialist) Critical care	Yes	–/4 h	< 10 to > 50	Yes	Appropriate diagnostic interpretation in 56% of trainees, and therapeutic suggestion in 52% of the time (vs 100% in experts); a cut-off of 40 and 50 studies allowed appropriate diagnosis and management respectively, with a 100% specificity and 40% sensitivity LV function and size, RV function and size, pericardial effusion and tamponade, IVC size and collapsibility
	2009 [26] 44 patients	– Critical care	Yes	2 h/4 h	–	No	LV systolic function: 0.72 (0.52–0.93) ^b
	2012 [27]	100 medical practitioners Anesthesiology Critical care	Yes	40 h tutorial/9 h	–	No	LV size: 91–100% of correct answers LV systolic function: 97–100% of correct answers RV size: 93–100% of correct answers RV systolic function: 90–100% of correct answers Haemodynamic state: 94–100% of correct answers Moderate-to-severe left-sided valvulopathy: 90 to 98% of correct answers Mild left-sided valvulopathy: 53–100% of correct answers
	2014 [28]	8 fellows Critical care	Yes	6 h/6 h	–	No	Cardiac US: increase of mean knowledge assessment score from 58 to 86% ($p = 0.05$) after training; increase of mean bedside skills assessment from 0 to 79% after training ($p < 0.0001$)
	2017 [8]	363 learners Critical care Various backgrounds	Yes	3-day training course	–	No	RV size: mean recognition from 68% (pretest) to 98% after training; practical skills from 17% (pretest) to 85% after training
	2014 [29] 48 patients	16 residents Anesthesiology Medicine	Yes ($n = 12$)	2 h/–	67 6 months	No	LV systolic function, RV dilatation, pericardial effusion, IVC respiratory variations; agreement with expert (0: no; 1: yes): 0.8 ± 0.4
Abdominal US and lung	2009 [30] 77 patients	8 residents Critical care	Yes	2.5/6	(73 overall)	No	Pleural effusion**: 0.3 (0.01–0.62) Thoracentesis feasibility: 0.65 (0.32–0.97) Intraperitoneal effusion: 0.44 (0.1–0.9) Abdacentesis feasibility: 0.82 (0.49–1.15) Obstructive uropathy: 0.77 (0.34–1.2) Chronic renal disease: 1 (1–1)

TTE transthoracic echocardiography, ICU intensive care unit, CCU coronary care unit, US ultrasound, LV left ventricle, RV right ventricle, IVC inferior vena cava, FAST focused abdominal sonography for trauma

* Studies providing no information on their training program are not mentioned. Although certain studies listed herein assessed a teaching program aimed at obtaining a field of competence larger than that initially proposed to define the basic level of CCUS [1], solely those in compliance with the basic level are summarized

**Cohen's Kappa coefficient with 95% confidence intervals

Table 2 Summary of current recommendations issued by scientific societies

Ultrasound modality/examined organs	Year/source	Targeted trainees	Theoretical program	Number of examinations/tutored examinations	Computerized simulation	Comments
Basic TTE/heart	2011 [1, 31–33] Critical care round table	Every ICU physician	≥ 10 h (lectures, illustrative didactic cases with image-based training)	≥ 30 fully supervised TTE examinations	–	Round table involving experts from 11 Critical Care Societies in 5 continents
Transcranial Doppler	American Academy of Neurology https://www.aan.com/siteassets/home-page/tools-and-resources/academic-neurologist-researchers/teaching-materials/aan-core-curricula-for-program-director/neuroimage-fellow_tr.pdf	Neurocritical care, neuroimaging fellows No recommendations for general critical care	–	100 performed and interpreted	–	–
Lung/Pleura	2014 Canadian recommendations in anesthesia/CCUS	Anesthesia/critical care	–	15 [34] to 20 [35]	–	–
FAST (Abdomen)	2020 Canadian anesthesia recommendation: expert consensus	Anesthesia trainee	–	20 [34]	–	–
Abdominal free fluid	2014 Canadian recommendations in CCUS: expert consensus	Critical care	–	10 [35]	–	–
Renal	2014 Canadian recommendations in CCUS: expert consensus	Critical care	–	25 [35]	–	–
Vascular	2014 Canadian recommendations in CCUS	Critical care	–	10	–	–
Abdominal Aorta	2014 Canadian recommendations in CCUS: expert consensus	Critical care	–	25 [35]	–	–
Deep vein thrombosis	2014 Canadian recommendations in CCUS: expert consensus	Critical care	–	25 [35]	–	–
Vascular access	2014 Canadian recommendations in CCUS: expert consensus	Critical care	–	10 [35]	–	–

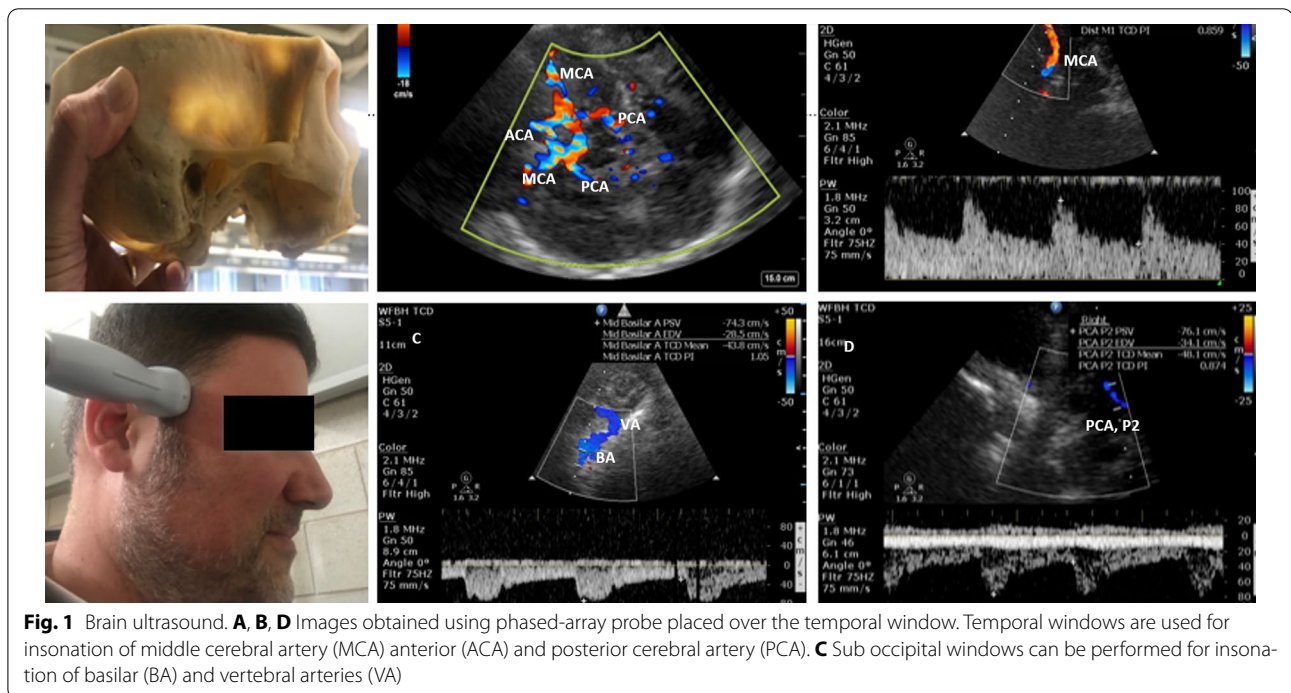
Table 2 (continued)

Ultrasound modality/examined organs	Year/source	Targeted trainees	Theoretical program	Number of examinations/tutored examinations	Computerized simulation	Comments
Each application	American College of Emergency Physicians https://www.acep.org/globalassets/new-pdfs/policy-statements/ultrasound-guidelines---emergency-point-of-care-and-clinical-ultrasound-guidelines-in-medicine.pdf	Emergency medicine	–	25	–	–

tion [11]. In patients with confounders for clinical exams, TCD/TCCD can be used as an ancillary test to confirm brain death [12]. The experts did not obtain agreement because of the specialized nature of patients with brain death, that are usually taken care of by neurointensive care physicians, or neurologists/neurophysiologists, using other available imaging techniques.

Item 3. Detection of cerebral vasospasm after subarachnoid haemorrhage (ESM2, Figure S3)

- We are **unable to provide recommendation** regarding the evaluation of increased flow velocities and Lindegaard ratio (defined as mean flow in the middle cerebral artery/internal carotid artery) through TCCD for the detection of vasospasm in patients with aneurysmal subarachnoid haemorrhage as basic skill for intensivists (*no recommendation*).



Background Patients with subarachnoid hemorrhage (SAH) can experience cerebral vasospasm 3–14 days after bleeding, which may result in ischemic injury [9]. TCD monitoring is a key component to identify patients at high risk for vasospasm. TCD imaging and TCCD have both been evaluated and seem to show greater sensitivity and specificity for middle cerebral artery compared to other vessels and higher sensitivity for TCCD compared to TCD [13]. However, a part of the panel felt that this was a too advanced skill requiring consulting neurologists and neurosurgeons to support clinical decision making.

Item 4. Evaluation of ischemic stroke (ESM 2, Figure S4)

- We are **unable to provide recommendation** regarding the evaluation of flow velocity waveform using TCCD to assess for intracranial thrombosis causing stenosis or emboli monitoring in patients with infective endocarditis or undergoing cardiological procedures to assess risk of cerebrovascular complications (*no recommendation*).

Background Evaluation and management of acute ischemic stroke have evolved over the last few years with image-guided identification of large vessel occlusion. Patients in medical, surgical and cardiothoracic intensive care units may have an underlying etiology increasing their risk of stroke and may benefit from TCD evaluation to assess cerebral hemodynamics [9] and complications. However, the question remains whether this skill is too advanced for basic ICU assessment.

Item 5. Cranial ultrasound for intracerebral pathology (ESM2, Figure S5)

- We are **unable to provide recommendation** regarding the use of B-mode assessment of brain parenchyma for the detection of major intracranial complications such as haemorrhage and/or midline shift (*no recommendation*).

Background B-mode cranial ultrasound can provide additional parameters that could complement the assessment of patients at risk of ICHT, as well as help in the detection of intracerebral haemorrhage and complications [9]. However, this skill requires specialized/advanced training.

Item 6. Cerebral autoregulation

- We **recommend against** the use of autoregulation testing as a basic skill for intensivists to assess cerebrovascular hemodynamics (stress manoeuvres to elicit vasomotor reactivity) for the care of patients with acute brain injury (*weak recommendation*).

Background Brain injured patients may have loss of autoregulation, and this may impact management of systemic hemodynamic to prevent secondary brain injury [9]. Study of autoregulation or vasomotor reactivity can be done with change in TCD-flow velocity in response to changes in blood pressure, carbon dioxide or by performing stress maneuvers [14]. However, the panel felt that this skill was too advanced to be included as basic skill for intensivists.

Thorax (Fig. 2, ESM 3, Video S1).

Item 1. Pneumothorax (ESM 3, Video S2-S6)

- We **recommend** that the identification of either one of the following sonographic findings to rule out the presence of pneumothorax (PTX): lung sliding, lung pulse, and/or B-lines should be considered as basic skill (*strong recommendation*).
- We **recommend** that the identification of the “lung point” to confirm a suspected PTX should be considered as a basic skill (*strong recommendation*).
- We **recommend** that the integration of lung US findings with clinical assessment to determine the indication for PTX drainage should be considered as basic skill (*strong recommendation*).
- We **recommend** that the integration of lung US findings with clinical assessment to determine the location for PTX drainage should be considered as basic skill (*strong recommendation*).
- We **recommend** that the assessment of topographic projection over the chest of the lung point to semi-quantify extension of PTX should be considered as basic skill (*weak recommendation*).

Background Lung US accuracy for PTX detection under the probe is higher than chest X-ray [15], with higher sensitivity. Thus, lung US is superior in ruling-out but equally specific to chest X-ray in ruling-in PTX, mainly for small anterior air collections, and comparable to Computed Tomography (CT) [16]; it is nowadays integrated in the standard approach to trauma (extended focused assessment sonography for trauma) [17] (Fig. 2). The panel was strongly in favor of the use of ultrasonographic signs to rule out/in pneumothorax. The panel also agreed on the association of ultrasound findings with clinical assessment to reach the decision of pleural drainage, to guide drain insertion and to monitor effectiveness and complications of the procedure. The location of the lung point on the thorax allows semi-quantifying the lung collapse [16]; despite the interest of this application for clinical assessment and monitoring of patients with pneumothorax, especially if under positive pressure ventilation, this was not considered a basic skill by the panel.

Item 2. Pleural effusion (ESM 3, Video S5, S8–S10)

- We **recommend** that the evaluation of the presence of an anechoic region above the diaphragm as primary sonographic finding of pleural effusion should be considered as basic skill (*strong recommendation*).
- We **recommend** that the use of lung US to estimate the volume of pleural effusion should be considered as basic skill (*strong recommendation*).
- We **recommend** that the presence of additional internal echoes within the effusion to suggest the presence of complicated effusions (e.g., exudates, empyema, hemorrhage) should be considered as basic skill (*strong recommendation*).
- We **recommend** that the use of lung US to determine the indication and position for drainage of a pleural effusion should be considered as basic skill (*strong recommendation*).

- We **recommend** that the use of lung US to monitor the effectiveness and complications of the drainage and procedure should be considered as basic skill (*strong recommendation*).

Background The use of US for the assessment of pleural effusions, visualized as an anechoic space between the pleurae, has been acknowledged for many years [18]. Lung US is more sensitive than CXR in identifying small pleural effusions and more specific in distinguishing pleural effusion from consolidations/collapse [19]; it also allows a reliable quantification of the effusion volume when compared to the actual volume of fluid collected with thoracentesis [19, 20], with accuracy comparable to CT [21]. The panel was strongly in favor of the use of ultrasound to identify pleural effusion, to guide pleural drainage and monitor effectiveness/complications of the procedure [21].

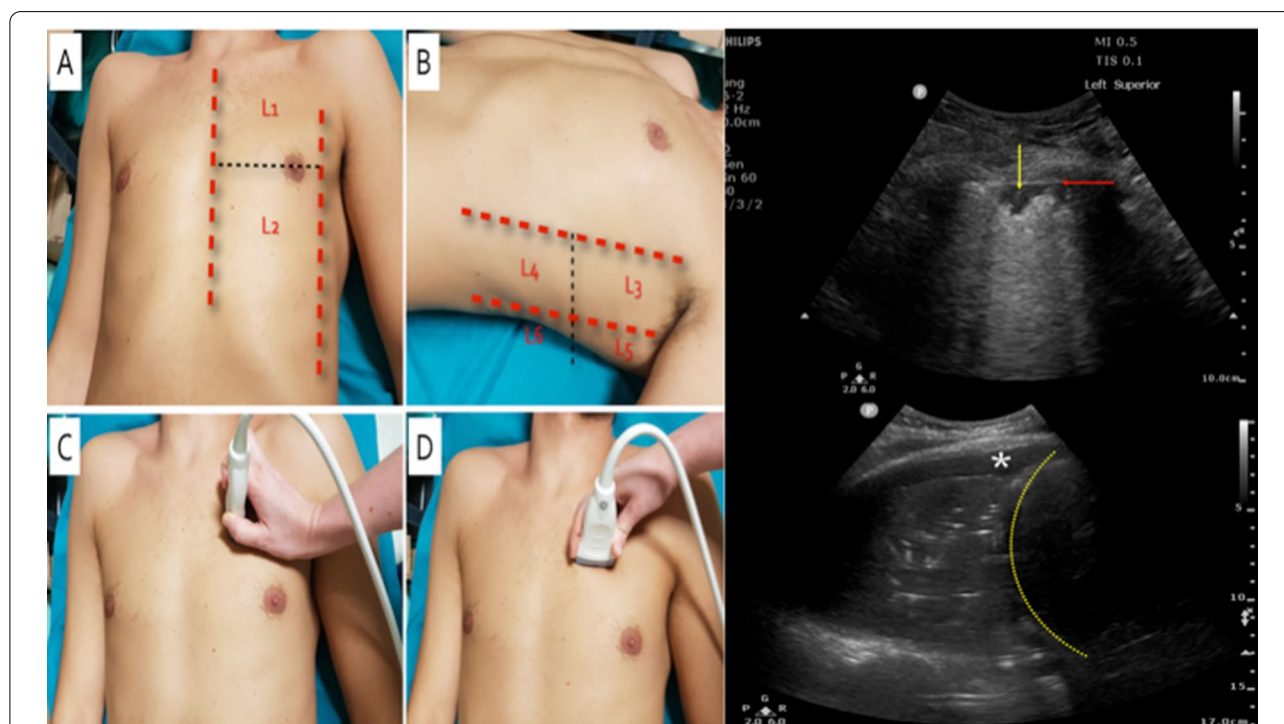


Fig. 2 Lung ultrasound. Images obtained using low-frequency curvilinear probe placed with orientation marker directed cranially. Technique for a complete thoracic examination. Panels **A–D**: when acquiring lung ultrasound images, a structured approach includes proper patient position and exposure and appropriate scanning protocol. A six-area per hemithorax approach is usually considered for a complete thoracic assessment: anterior, lateral and posterior fields are identified by sternum, anterior and posterior axillary lines (red dotted lines). **Right upper panel**: consolidation with static air bronchogram. Lung ultrasound scan of a posterior-inferior field with a low-frequency phased-array transducer in longitudinal scan. **Right lower panel**: consolidation with dynamic linear-arborescent air bronchogram. Lung ultrasound scan of a posterior-inferior field with a low-frequency curvilinear transducer in longitudinal scan. The diaphragm is well visualized as one of the basic landmarks (yellow dotted arrow), thus allowing to correctly identify intra-thoracic and intra-abdominal structures. The lung presents complete loss of aeration: the lobe is visualized as a tissue-like pattern. Within the lung, multiple white images are visualized; they move synchronously with tidal ventilation and present a shape mimicking the anatomical airway: they correspond to dynamic linear-arborescent air bronchogram. This pattern suggests the main airway is patent and is highly specific for community-acquired or ventilator-associated pneumonia, depending on the context. A small pleural effusion is also visualized as a hyperechoic space surrounding the consolidated lung (*)

Item 3. Respiratory failure: reduction/loss of lung aeration (ESM 3, Video S3, S11–S15)

- We **recommend** that the integration of lung US within the clinical context should be considered as basic skill for the evaluation of respiratory failure (*strong recommendation*).
- We **recommend** that the appearance of interstitial syndrome (B pattern) and/or lung consolidation (tissue-like pattern) as markers of increased lung density (i.e., reduction or complete loss in lung aeration) should be considered as basic skill (*strong recommendation*).
- We **recommend** against the use of quantitative approaches (e.g., lung ultrasound score) as basic ultrasound skill (*strong recommendation*).
- We **recommend** that the integration with the clinical context of the identification of additional sonographic findings (e.g., shape, size, margin, presence of shred sign, distribution, presence of dynamic or static air bronchogram and fluid bronchogram) for the diagnosis of parenchymal lung consolidation should be considered as basic skill (*strong recommendation*).
- We **recommend** that the use of an integrated (lung, cardiac and venous ultrasound) approach in patients with high probability of pulmonary embolism and for whom CT is not possible should be considered as basic skill (*strong recommendation*).
- We **recommend** a multifaceted approach to attempt identifying etiology of respiratory failure (i.e., lung injury versus cardiogenic pulmonary oedema) with lung US including integration with the clinical context, and identification of additional sonographic findings (e.g., B-line distribution, B-line density, and subpleural consolidation) as basic skill (*strong recommendation*).
- We are **unable to provide recommendation** on the evaluation of the loss of aeration of anterior fields to distinguish focal and non-focal patterns and to guide the ventilatory strategy (positive end expiratory pressure (PEEP) titration, pronation) in acute respiratory distress syndrome (ARDS) patients (*no recommendation*).

Background Lung US is a valid tool to improve the differential diagnosis of lung parenchymal diseases impairing lung aeration [23]. Although the lung parenchyma cannot be directly visualized until loss of aeration is complete, ultrasound artifacts can be combined to orient the clinicians in the management of acute respiratory failure and in the monitoring of mechanically ventilated patients [23]. The panel agreed on the use of ultrasound findings combined with clinical assessment to improve accuracy in the differential diagnosis of acute respiratory failure and

for the diagnosis of pulmonary embolism, in combination with other ultrasound techniques, such as critical care echocardiography [22, 23]. No consensus was reached on the use of ultrasound findings as a guide for the ventilatory strategy as this was considered too advanced from a part of the panel.

Item 4. Airway ultrasound (ESM 3, Video S16)

- We **recommend against** the use of airway ultrasound for endotracheal tube confirmation as basic ultrasound skill (*weak recommendation*).

Background The use of ultrasound for upper airway visualization has been described in different scenarios [26] for the assessment and identification of anatomical landmarks in case of emergency airway access, in preparation/during elective tracheostomy and for real-time identification of tracheal/esophageal intubation.

However, the panel agreed in not considering the use of airway ultrasound for real-time identification of tracheal/esophageal intubation as a basic ultrasound skill for the intensivists, possibly for lack of strong evidence and need for more advanced training.

Item 5. Diaphragm ultrasound (ESM 3, Video S17–S20)

- We **recommend** that the estimation of diaphragmatic excursion for diaphragmatic function assessment, mainly in patients to be weaned from mechanical ventilation should be considered as basic skill (*weak recommendation*).
- We are **unable to provide recommendation** on the evaluation of diaphragmatic thickening fraction for diaphragmatic function assessment, mainly in patients to be weaned from mechanical ventilation, as basic skill (*no recommendation*).

Background Diaphragmatic ultrasound assessment is a useful and feasible bedside tool; it easily identifies diaphragm paralysis, and helps in predicting prolonged and/or failure of weaning from mechanical ventilation through examining excursion (DE) or thickening fraction (TF) [27–29]. The panel agreed on the use of DE to assess diaphragmatic dysfunction during the weaning from mechanical ventilation, but questions remain on the use of TF, as it is more technically challenging.

Heart (Fig. 3)

Item 1. Evaluation for left ventricular (LV) systolic failure (ESM 4, Video S1, S2)

- We **recommend** that the assessment of LV systolic failure as increased, normal or decreased contrac-

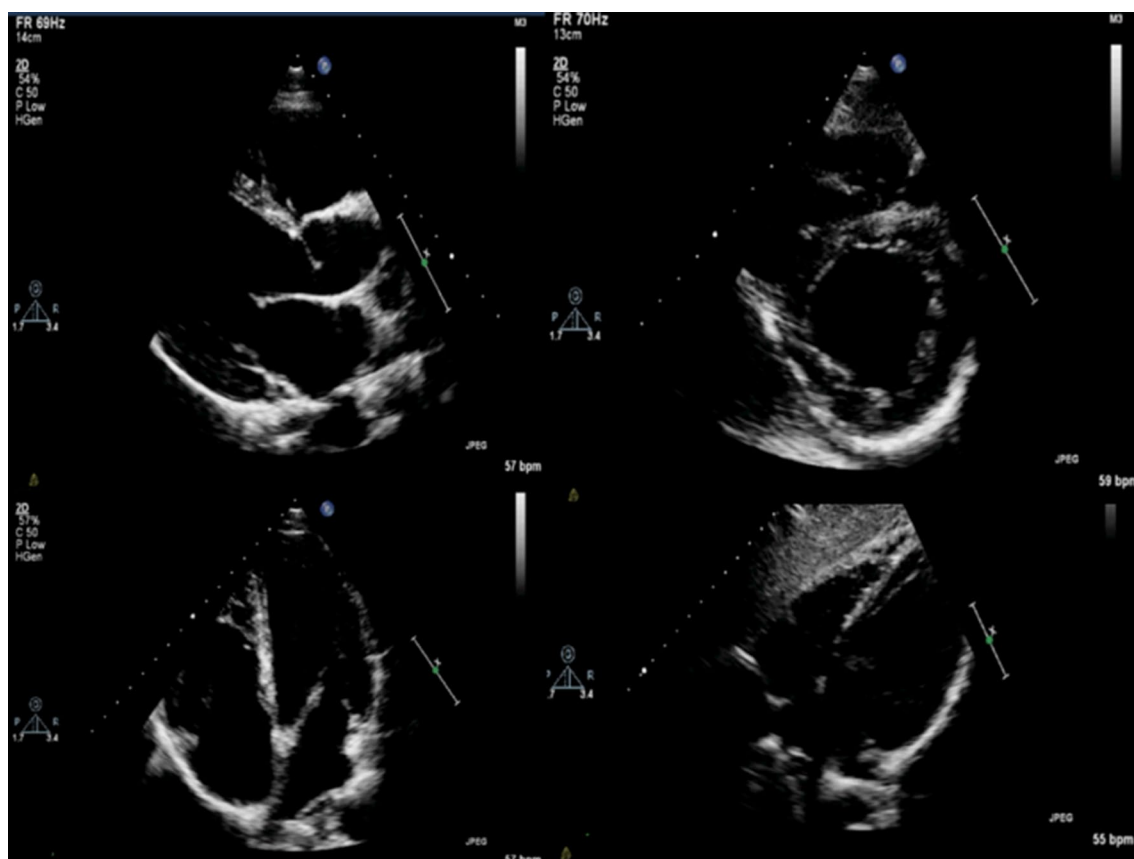


Fig. 3 Standard cardiac views. The images were obtained using a standard phased-array probe. **Upper left panel.** Parasternal long axis, where probe placed in left parasternal areas, with orientation marker pointing to the patient's right shoulder; **Upper right panel.** parasternal short-axis, where probe placed in left parasternal area with orientation marker pointing to patient's left shoulder; **Lower left panel.** Apical four-chamber, where probe placed over the apex of the heart with orientation marker pointing to the patient's left; **Lower right panel.** Subcostal four-chamber, where probe placed subxiphoid with orientation marker pointing to the patient's left

tility of the LV using four windows views should be considered as basic skill (*strong recommendation*).

- We **recommend** that regional wall motion abnormalities, which may aid in triaging patients suspected of acute coronary syndromes, who have equivocal, or uninterpretable serologic or electrical features should be considered as basic skill (*weak recommendation*).
- We **recommend** that the evaluation of LV outflow tract velocity time integral as an estimation of stroke volume should be as basic skill (*weak recommendation*).
- We **recommend** that an understanding of color Doppler—physics and limitations—is an added skill that may not be routinely taught and should not be considered as basic skill (*strong recommendation*).
- We are **unable to provide recommendation** on the use of transesophageal echocardiography as basic skill to obtain left ventricular parameters when tran-

sthoracic views are indeterminate (*no recommendation*).

Background Assessment for cardiogenic shock is easily carried out with bedside appraisal of LV systolic function (Fig. 3) [30]. The panel felt that basic recognition of normal and abnormal echocardiographic findings for LV evaluation are expected in all patients with undifferentiated shock admitted to the intensive care unit. Furthermore, in patients with known cardiogenic shock, these skills may be applied to evaluate response to vasoactive medications or reductions in mechanical circulatory support [31]; although transesophageal echocardiography might have several advantages compared to the transthoracic technique (including accuracy, better image resolution, etc..) part of the panel felt that this tool should be part of an advanced skills program.

Item 2. Evaluation for right ventricular (RV) failure (ESM 4, Video S3)

- We **recommend** that if massive pulmonary embolism is suspected as a cause of circulatory failure, the evaluation of normal RV size to effectively rule out obstructive physiology and re-prioritize diagnostic considerations should be considered as basic skill (*strong recommendation*).
- We **recommend** that the evaluation of RV size, as enlarged RV with RV/LV end-diastolic-surface area on apical four-chamber view or RV/LV end-diastolic-diameter on a parasternal long-axis view, should be considered as basic skill (*strong recommendation*).
- We **recommend** that the evaluation of RV failure as looking for: paradoxical septal motion, septal flattening, and dilated inferior vena cava (IVC) with no or small respiratory variations should be considered as basic skill (*strong recommendation*).
- We **recommend** that the evaluation of acute RV failure according to free RV wall thickness in subcostal view associated with RV dilatation should be considered as basic skill (*strong recommendation*).

Background Detection of right ventricular (RV) failure informs diagnosis, prognosis and heart–lung interactions in the ICU [32, 33] and, therefore, provides crucial information to the intensivist managing patients with cardiopulmonary failure, which are easily achieved by a basic bedside assessment.

Item 3. Evaluation of hemodynamically important pericardial effusion (ESM 4, Video S4)

- We **recommend** that the assessment of hemodynamically important pericardial effusion as early systolic collapse of the right atrium/diastolic collapse of the RV on an apical four-chamber or a subcostal view should be considered as basic skill (*strong recommendation*).
- We **recommend** that the evaluation of echocardiographic parameters of tamponade (chamber collapse, Doppler inflow variations) and its integration within the clinical context should be considered as basic skill (*strong recommendation*).
- We **recommend** that the evaluation of inferior vena cava (IVC) size and dilation to inform plausibility of tamponade physiology in cases of uncertainty or where multiple diagnostic considerations are being entertained should be considered as basic skill (*strong recommendation*).
- We are **unable to provide recommendation** on transesophageal echocardiography in patients in whom there is suspicion of post-procedural pericardial effusion (*no recommendation*).

Background The detection or exclusion of pericardial effusion in the critically ill is an essential clinical skill, which has been greatly simplified with the advent of point of care echocardiography, although it requires close integration with clinical parameters [34]. Assessment of the pericardium is recommended for all undifferentiated shock or cardiac arrest patients in the intensive care unit as part of a goal-directed echocardiogram; moreover, a non-dilated IVC usually rules out cardiac tamponade. The panel felt that these constitute required basic US skills for intensivists using the transthoracic approach.

Item 4. Evaluation for severe hypovolemia (ESM 4, Video S5)

- We **recommend** that the assessment of severe hypovolemia as small, collapsing IVC, small chamber sizes with intraventricular obliteration during systole should be considered as basic skill (*strong recommendation*).
- We **recommend** against the use of US for determination of fluid responsiveness in patients with persistent shock in the absence of features of hypovolemia as basic skill (*strong recommendation*).

Background With routine echocardiographic use, as well as mixed shock states, intensivists require understanding of the imaging features of hypovolemic shock, which can be easily obtained [35, 36]. Obvious acute volume loss (massive hemorrhage) and ensuing shock do not generally benefit from echocardiographic assessment which leaves the role for echocardiography for hypovolemia in more occult or chronic cases of volume loss.

Item 5. Evaluation for acute, severe left-sided valvulopathy (ESM 4, Video S6)

- We **recommend** that the evaluation of acute-left-sided valvulopathy as obvious anatomical abnormalities including vegetations should be considered as basic skill (*strong recommendation*).
- We **recommend** that the prosthetic valve assessment, and distinguishing severity of valvular lesions as well as acuity vs chronicity are the domain of expert echocardiographers and is discouraged at the basic level (*strong recommendation*).
- We **recommend** that the aortic and mitral valves should be the priority as basic skill, as other valve pathologies generally do not cause rapidly progressive, life-threatening conditions (*strong recommendation*).
- For those with existing fluency in the added skill of color Doppler, we **recommend** its use for the evaluation of acute-left-sided valvulopathy (by suggesting major changes in flow) should be considered as basic skill (*weak recommendation*).

- We **recommend** that the 2D assessment on anatomic basis (stenosis, vegetations, flail leaflet, perforation) of critical valvular failure should be considered as basic skill (*weak recommendation*).

Background Echocardiographic assessment of valvular heart disease frequently calls for advanced techniques and great experience [34]. However, the panel felt that basic echocardiography can identify obvious mechanical failure of either the mitral or aortic valve and may provide critical diagnostic information in patients with cardio-pulmonary failure. Furthermore, patients with other clinical features of valvular disease (heart murmur, peripheral features of endocarditis, widened pulse pressure) will benefit from deliberate attention to the mitral and aortic valves [35]. In all cases, we consider that echo studies should be systematically recorded for critical discussion with experts in the field, in case of uncertainties.

Abdomen (Fig. 4)

Item 1. Triage or clinical suspicion for aortic syndromes (ESM 5, Figure S1)

- We **recommend** that the scanning from the epigastrium up to the mesogastrium at the level of umbilicus, in a transverse and longitudinal plane for the detection of aneurysms of the abdominal aorta (AAA) in case of unexplained shock, abdominal pain, pulsatile mass palpation, presence of emboli, should be considered as basic skill (*strong recommendation*).

Background Bedside abdominal US when used as a screening modality, has been shown to be associated with excellent accuracy (sensitivity of 95–100% and specificity of nearly 100%) for the detection of AAA [37]. Moreover, clinical studies demonstrated that abdominal US screening reduced aortic syndrome related mortality, primarily through a reduction in rupture by emergency repair [38]. US for the diagnosis of aortic aneurism was considered a basic skill by the panel. However, the ultrasound diagno-

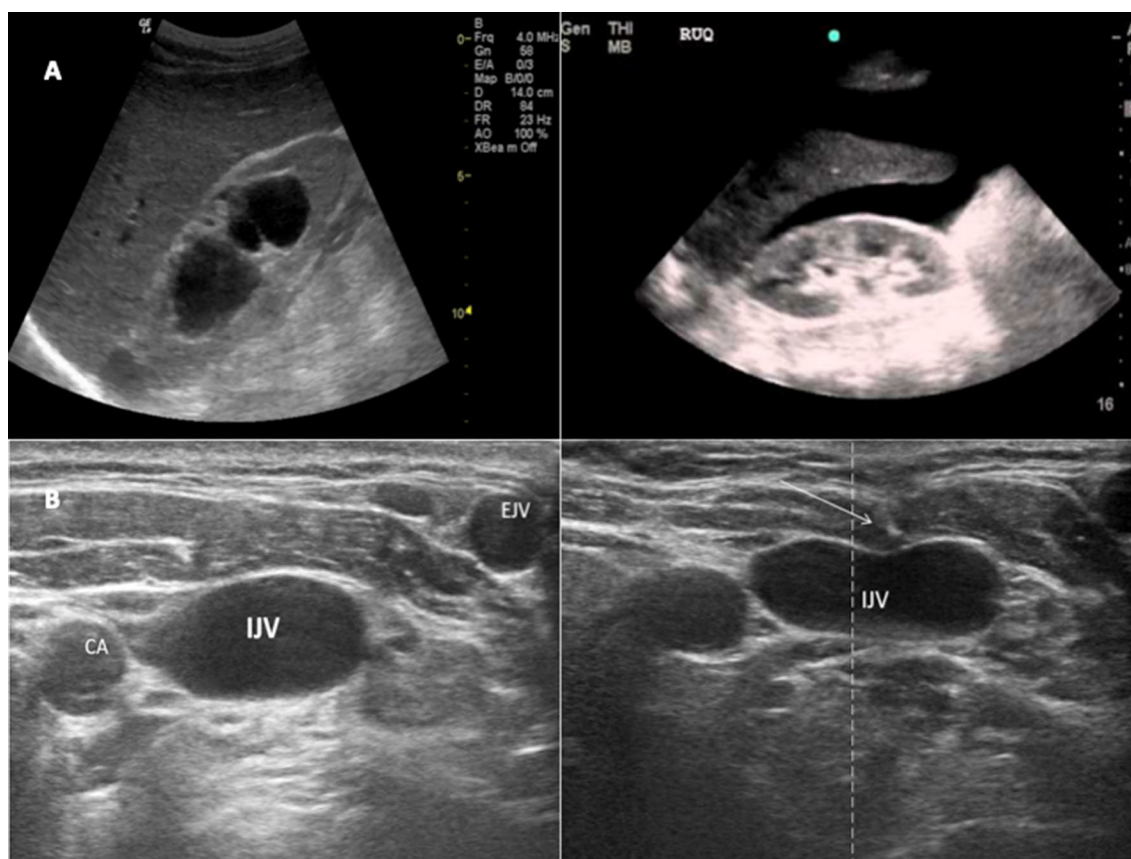


Fig. 4 Panels **A** abdominal ultrasound: images obtained using low-frequency curvilinear probe placed over the right, subcostal area, mid-axillary line with orientation marker pointing cranially. **Left**: severe hydronephrosis of the right kidney. **Right**: free fluid in the hepatorenal recess. Panels **B** vascular ultrasound. **Left**: short-axis view of the right internal jugular vein (IJV), external jugular vein (EJV) and carotid artery (CA). **Right**: out-of-plane puncture of the internal jugular vein (IJV) the arrow shows the pressure on the anterior wall of the vein of the tip of the needle

sis of rupture is complex and needs to be integrated with clinical findings (Fig. 4, ESM 2, Figure S4).

Item 2. Assessment of kidneys and urinary tract (ESM 5, Figure S2–S7)

- We **recommend** that B-mode evaluation of both kidneys and bladder in the short- and long-axis views to assess for the presence or absence of hydronephrosis and bladder overdistention should be considered as basic skill (*strong recommendation*).
- We **recommend** that the qualitative assessment of urine volume in the bladder, to identify bladder overdistension or prevent unnecessary catheterization should be considered as basic skill (*strong recommendation*).
- We are **unable to provide any recommendation** regarding the assessment of renal doppler resistive index (RDRI) of the interlobar arteries to predict adverse outcomes and renal failure progression (*no recommendation*).

Background B-mode US has a key role in the diagnosis of hydronephrosis and kidney injury due to its high sensitivity (>95%) (Fig. 4) [39]; RDRI has been shown to be a promising tool to predict acute kidney injury progression in post-operative setting as well as predict ICU mortality [40, 41] with a diagnostic accuracy higher than oliguria and serum creatinine levels. However, it has not been extensively validated in relatively inexperienced operators and requires more studies to determine whether it can be recommended as a basic US application in clinical practice.

Item 3a. Assessment of traumatic and non-traumatic acute abdomen (ESM 5, Video S1–S4).

Non-traumatic acute abdomen.

- We **recommend** that abdominal US should not be used alone to identify the cause of a surgical abdomen, because it does not reliably characterize different etiologies (e.g., infectious colitis, small bowel obstruction, intussusception and perforation) (*strong recommendation*).
- We **recommend** that the ability to detect hypo/anechoic free fluid in the peritoneal cavity for the identification of free peritoneal fluid to rule in non-traumatic acute abdomen should be considered as basic skill (*strong recommendation*).
- We **recommend** that the integration of clinical assessment with abdominal US to rule out non-traumatic acute abdomen should be considered as basic skill (*strong recommendation*).
- We **recommend** against the use of ultrasound as basic skill for the intensivists in the functional assess-

ment of bowel as the variety of ultrasound parameters that could be assessed is vast (*strong recommendation*).

- We are **unable to provide any recommendation** regarding the B-mode assessment of the gallbladder in the presence of jaundice and elevated liver function tests to evaluate for acute cholecystitis (dilatation of the intrahepatic bile ducts, gallbladder hydrops in conjunction with large gallbladder stones, presence of thickened walls or fluid peripheral collections, presence of biliary sludge or pus) (*no recommendation*).
- We are **unable to provide any recommendation** regarding the use of the detection of increased echogenicity of the peritoneal stripe with multiple reflection artifacts (A lines) for the identification of free intraperitoneal air to rule in the diagnosis of non-traumatic acute abdomen (*no recommendation*).
- We are **unable to provide any recommendation** regarding the US bowel assessment by B mode as initial evaluation of gastrointestinal tract conditions presenting acutely (*no recommendation*).
- We **recommend against** the identification of multiple granular echogenic foci within the bowel wall (starry night appearance) for the detection of intramural gas in the bowel wall to rule in the diagnosis of non-traumatic acute abdomen as a basic skill for intensivists (*weak recommendation*).

Traumatic acute abdomen.

- We **recommend** that the Focused Assessment with Sonography for Trauma (FAST) examination to identify pathological presence of free fluid/blood (i.e., pericardial sac, pleural space and peritoneum) in traumatic acute abdomen should be considered as basic skill (*strong recommendation*).
- We **recommend** that the integration of clinical assessment with the evaluation of the presence or absence of free peritoneal fluid in traumatic acute abdomen should be considered as basic skill (*strong recommendation*).
- We **recommend** that FAST examination as an integral component of trauma resuscitation should be considered as basic skill (*strong recommendation*).
- We **recommend** against the assessment of RDRI of the interlobar arteries in hemodynamically stable polytrauma patients to promptly detect signs of decompensation due to incipient traumatic haemorrhagic shock (*weak recommendation*).

Both traumatic and not traumatic acute abdomen.

- We **recommend** that the use of serial FAST exams in response to changes in the patient's condition to visualize the development of previously undetectable free fluids should be considered as basic skill (*strong recommendation*).
- We **recommend** that the evaluation of the presence of additional internal echoes within the effusion (which suggests the presence of complicated effusions) should be considered as basic skill (*strong recommendation*).
- We **recommend** that the integration of ultrasound findings with clinical assessment to determine the indication, location for abdominal drainage, monitor the effectiveness of the procedure and rule out drainage complications should be considered as basic skill (*strong recommendation*).
- We are **unable to provide any recommendation** regarding the use of Doppler ultrasonography of the kidney and spleen through RDRI of the renal interlobar arteries and the main branches of the splenic arteries to promptly detect early signs of splanchnic hypoperfusion in combination with other ultrasound in the context of traumatic or not traumatic acute abdomen (*no recommendation*).

Background FAST has progressively expanded beyond application in the trauma setting, and now represents an integral part of a more comprehensive evaluation of potential causes of shock in hypotensive patients [42]. The panel agreed that abdominal US should be a fundamental component of FAST, should be used to detect the presence of peritoneal fluid and represents a safe method for paracentesis, performed for both therapeutic and diagnostic purposes (Fig. 4) [43, 44]. However, the panel felt that some skills such as the use of US for detection of intramural gas to rule in the diagnosis of non-traumatic acute abdomen need further evidence and advanced skills and should be evaluated in a more comprehensive examination of the abdomen and, therefore, not considered basic skills.

Vascular (Fig. 4)

Item 1. Vascular cannulation (ESM 6, Video S1, Figure S1-S4)

- We **recommend** that anatomical evaluation under Ultrasound guidance (USG) for arterial cannulation in case of multiple failed attempts should be considered as basic skill (*strong recommendation*).
- We **recommend** that anatomical evaluation under USG for arterial cannulation when arterial pulse is not palpable should be considered as basic skill (*strong recommendation*).
- We **recommend** that the ultrasound scanning of the vessels (peripheral and central veins) to detect size, position and patency of the target vessel [by means of compression ultrasonography (CUS)], and to assess surrounding vital structures should be considered as basic skill (*strong recommendation*).
- We **recommend** that the continuous visualization of the needle tip during its trajectory using both in-plane and out-of-plane techniques to avoid penetration of the posterior wall of the vessel should be considered as basic skill (*strong recommendation*).
- We **recommend** that anatomical evaluation under USG in predicted difficult peripheral venous cannulation or after several failed attempts to improve success and patient's comfort should be considered as basic skill (*strong recommendation*).
- We **recommend** that the use of USG throughout the cannulation including the puncture, and post-procedural check for tip position as well as other abnormalities where there is suspicion of immediate life-threatening complications should be considered as basic skill (*strong recommendation*).

Background USG vascular access in ICU patients is increasingly supported by evidence [45] for significantly increased safety, effectiveness and efficiency when compared to methods using landmark guidance. The panel felt that the use of vascular USG in different settings should be included as basic skills for vascular cannulation [46, 47].


Item 2. Deep Venous Thrombosis (DVT) (ESM 6, Video S2, Figure S5)


- We **recommend** that the compression applied from the common femoral vein at the groin to the popliteal vein at the popliteal fossa to rule in DVT in case of clinical signs of DVT and/or in patients with risk factors to rule out silent DVT should be considered as basic skill (*strong recommendation*).

Background DVT risk factors include general and specific ICU risk factors such as mechanical ventilation, central venous catheterization, thrombocytosis and transfusion [45–48]. The compression technique, when applied from the common femoral vein at the groin to the popliteal vein (at the popliteal fossa) was demonstrated to be accurate for the diagnosis of DVT with high sensitivity and specificity among intensivists, although pulmonary embolism may also originate from pelvic and abdominal thrombi [49, 50]. This technique provides a rapid and accurate diagnosis of proximal lower extremity DVT and can be easily achieved by intensivists at the bedside [51].


BRAIN

Triage or clinical suspicion for intracranial hypertension


 We **recommend** B-mode TCCD insonation of the middle cerebral artery as a basic skill for intensivists for the qualitative waveforms analysis and to measure pulsatility index to rule out intracranial hypertension impairing cerebral perfusion.

 We are unable to provide recommendation regarding the use of optic nerve sheath diameter as a basic skill for intensivists to rule out intracranial hypertension.


Clinical suspicion of brain death

 We are unable to provide recommendation regarding the use of TCD/TCCD to recognize patterns suggesting impending cerebral circulatory arrest.


Detection of cerebral vasospasm after subarachnoid haemorrhage

 We are unable to provide recommendation regarding the evaluation of increased flow velocities and Lindegaard ratio through TCCD for the detection of vasospasm in patients with aneurysmal subarachnoid haemorrhage.


Evaluation of ischemic stroke

 We are unable to provide recommendation regarding the evaluation of flow velocity waveform using TCCD to assess for intracranial thrombosis causing stenosis or emboli monitoring in patients with infective endocarditis or undergoing cardiological procedures to assess risk of cerebrovascular complications.

Cranial ultrasound for intracerebral pathology

 We are unable to provide recommendation regarding the use of B mode assessment of brain parenchyma for the detection of major intracranial complications such as haemorrhage and/or midline shift.

Cerebral autoregulation

 We **recommend against** the use of autoregulation testing as basic skill for intensivists to assess cerebrovascular hemodynamics (stress maneuvers to elicit vasomotor reactivity) for the care of patients with acute brain injury.

 NO CONSENSUS  WEAK RECOMMENDATION  STRONG RECOMMENDATION  WEAK RECOMMENDATION AGAINST  STRONG RECOMMENDATION AGAINST

Fig. 5 Summary of the recommendations

Discussion and conclusions

In this consensus, we provide a large number of statements intended to recommend those basic ultrasound skills that intensivists should possess/acquire for the evaluation and management of critically ill patients (see Fig. 5). Importantly, this should not be read as a potential medico-legal document describing what constitutes adequate management by an intensivist, but it rather should be considered as a guide for intensivists during their pursuit of competencies in basic critical care US. Also, this document could serve as a core for any courses or training program, at least endorsed by ESICM.

The major limitation of this study is the lack of a systematic revision of literature and grading of evidence. However, experts were chosen for their experience and extensive knowledge of literature with huge background on critical care US. Second, the selection of the experts and votation could have led to a bias. However, all the experts had at least a basic training in head-to-toe ultrasonography, and an ultra-specialization regarding one organ. Each subgroup of ultra-specialized experts proposed the statements, but all the panel voted the statements. In this way, we aimed to provide high quality

statements but at the same time mirror the needs of every general intensivist, presenting a consensus rather than the opinion of a single physician.

This consensus covers many aspects of ultrasound in a very large and ambitious field. However, we had to limit the number of the statements/skills and, therefore, some topics and clinical applications could be missing (such as evaluation of pulmonary pressure, or clinical scenarios such as cardiac surgery). Similarly, details regarding the methodology and thresholds/cut-off of each skill were not deeply described in the main manuscript. However, we included a vast number of ESM included videos and additional figures to overcome this limitation.






Important questions still must be addressed, and future research and training programs should focus on the implementation of head-to-toe ultrasonography in the ICU.

Supplementary Information






The online version contains supplementary material available at <https://doi.org/10.1007/s00134-021-06486-z>.

THORAX


Pneumothorax


-  We **recommend** that the identification of either one of the following sonographic findings to rule out the presence of PTX: lung sliding, lung pulse, and/or B-lines- should be considered as basic skill for intensivists.
-  We **recommend** that the identification of the "lung point" to confirm a suspected PTX should be considered as a basic skill for intensivists.
-  We **recommend** that the integration of lung US findings with clinical assessment to determine the indication for PTX drainage should be considered a basic skill for intensivists.
-  We **recommend** that the integration of lung US findings with clinical assessment to determine the location for PTX drainage should be considered as basic skill for intensivists.
-  We **recommend** that the assessment of topographic projection over the chest of the lung point to semi-quantify extension of PTX should be considered as a basic skill for intensivists.


Pleural effusion


-  We **recommend** that the evaluation of the presence of an anechoic region above the diaphragm as primary sonographic finding of pleural effusion should be considered as basic skill for intensivists.
-  We **recommend** that the use of lung ultrasound to estimate the volume of pleural effusion should be considered as basic skill for intensivists.
-  We **recommend** that the presence of additional internal echoes within the effusion to suggest the presence of complicated effusions (e.g., exudates, empyemas, hemorrhage) should be considered as basic skill for intensivists.
-  We **recommend** that the use of lung US to determine the indication, position for drainage of a pleural effusion, monitor the effectiveness of the procedure should be considered as basic skill for intensivists.
-  We **recommend** that the use of lung US to monitor the effectiveness and complications of the drainage and procedure should be considered as basic skill for intensivists.


Respiratory failure: Reduction/loss of lung aeration


-  We **recommend** that the integration of lung US within the clinical context should be considered as basic skill for intensivists for the evaluation of respiratory failure.


-  We **recommend** that the appearance of interstitial syndrome (B-pattern) and/or lung consolidation (tissue-like pattern) as markers of increased lung density (i.e., reduction or complete loss in lung aeration), should be considered as basic skill for intensivists.

-  We **recommend against** the use of quantitative approaches (e.g., lung ultrasound score) as a core basic ultrasound skill for the intensivists.


-  We **recommend** that the integration with the clinical context and the identification of additional sonographic findings (e.g., shape, size, margin, presence of shred sign, distribution, presence of dynamic or static air bronchogram and fluid bronchogram) to narrow the differential diagnosis of parenchymal lung consolidation should be considered as basic skill for intensivists.

-  We **recommend** that the use of an integrated (including lung US, echocardiography and venous ultrasound) approach in patients with high probability of pulmonary embolism and for whom computed tomography is not possible should be considered a basic skill for intensivists.


-  We **recommend** that a multifaceted approach to attempt identifying etiology of respiratory failure with lung US including integration with the clinical context, and identification of additional sonographic findings (e.g., B-line distribution, B-line density, and subpleural consolidation) should be considered a basic skill for intensivists.


-  We are unable to provide recommendation on the evaluation of the loss of aeration of anterior fields to distinguish focal and non-focal patterns and to guide the ventilatory strategy (positive end expiratory pressure titration, pronation) in ARDS patients.

Airway Ultrasound

-  We **recommend against** the use of airway ultrasound for endotracheal tube confirmation as a core basic ultrasound skill for the intensivists.

Diaphragm Ultrasound

-  We **recommend** that the estimation of diaphragmatic excursion for diaphragmatic function assessment, mainly in patients to be weaned from mechanical ventilation should be considered a basic skill for intensivists.






-  We are unable to provide recommendation on the evaluation of diaphragmatic thickening fraction for diaphragmatic function assessment, mainly in patients to be weaned from mechanical ventilation.

 NO CONSENSUS  WEAK RECOMMENDATION  STRONG RECOMMENDATION  WEAK RECOMMENDATION AGAINST  STRONG RECOMMENDATION AGAINST





Fig. 5 continued

HEART


Evaluation for left ventricular systolic failure


-  We **recommend** that the assessment of left ventricular systolic failure as increased, normal or decreased contractility of the left ventricle using PSAX, PLAX, A4C and A2C views should be considered a basic skill for intensivists.
-  We **recommend** that regional wall abnormalities, which may aid in triaging patients suspected of acute coronary syndromes who have equivocal or uninterpretable serologic or electrical features should be considered a basic skill for intensivists.
-  We **recommend** that left ventricular outflow tract evaluation as an estimation of stroke volume should be a basic skill for intensivists as it may provide additional value when qualitative left ventricular function appears out of keeping with the clinical picture.
-  We **recommend** that an understanding of colour Doppler – physics and limitations – is an added skill that may not be routinely taught and should not be considered a basic skill for intensivists.
-  We are unable to provide recommendation on the use of transesophageal echocardiography as basic skill for intensivists to obtain left ventricular parameters when transthoracic views are indeterminate (e.g. mechanical support).


Evaluation for right ventricular failure


-  We **recommend** that if massive pulmonary embolism is suspected as a cause of circulatory failure, the evaluation of normal right ventricular size to effectively rule out obstructive physiology and re-prioritize diagnostic considerations should be considered a basic skill for intensivists.
-  We **recommend** that the evaluation of right ventricular size as enlarged RV with RV/LV on A4C view or RV/LV EDD on a PLAX view should be considered a basic skill for intensivists.
-  We **recommend** that the evaluation of right ventricular failure as looking for: paradoxical septal motion, septal flattening on PSAX view, and dilated IVC with no respiratory variations-should be considered a basic skill for intensivists.
-  We **recommend** that the evaluation of acute RV failure as the presence of RV dilation and free RV wall thickness in subcostal view should be considered as basic skill for intensivists.

Evaluation of hemodynamically important pericardial effusion



-  We **recommend** that the assessment of hemodynamically important pericardial effusion as early systolic collapse of the right atrium / diastolic collapse of the RV on an apical 4-chamber or a subcostal view should be considered a basic skill for intensivists.

 We **recommend** that the evaluation of echocardiographic parameters of tamponade (chamber collapse, Doppler inflow variations) and its integration within the clinical context should be considered a basic skill for intensivists.






 We **recommend** that the evaluation of inferior vena cava size to inform plausibility of tamponade physiology in cases of uncertainty or where multiple diagnostic considerations are being entertained should be considered a basic skill for intensivists.

 We are unable to provide recommendation on transesophageal echocardiography in the suspect of post-procedural pericardial effusion.

Evaluation for severe hypovolemia

-  We **recommend** that the assessment of severe hypovolemia as small, collapsing IVC, small chamber sizes with intraventricular obliteration during systole should be considered a basic skill for intensivists.
-  We **recommend against** the use of basic echo by general intensivists for determination of fluid responsiveness in patients with persistent shock in the absence of features of hypovolemia.

Evaluation for acute, severe left-sided valvulopathy

-  We **recommend** that the evaluation of acute-left-sided valvulopathy as obvious anatomical abnormalities including vegetations should be considered a basic skill for intensivists.
-  We **recommend** that the prosthetic valve assessment, and distinguishing severity of valvular lesions as well as acuity vs chronicity are the domain of expert echocardiographers and is discouraged at the basic level.
-  We **recommend** that the evaluation of aortic and mitral valves as priority of all basic echocardiographers should be considered a basic skill for intensivists, as other valves pathologies generally do not cause rapidly progressive, life threatening conditions.
-  We **recommend** that colour Doppler for the evaluation of acute-left-sided valvulopathy (by suggesting major changes in flow) should be considered as a basic skill for intensivists.
-  We **recommend** that the 2D assessment on anatomic basis (stenosis, vegetations, flail leaflet, perforation) of critical valvular failure should be considered as a basic skill for intensivists.

 NO CONSENSUS  WEAK RECOMMENDATION  STRONG RECOMMENDATION  WEAK RECOMMENDATION AGAINST  STRONG RECOMMENDATION AGAINST

Fig. 5 continued

ABDOMEN

Triage or clinical suspicion for aortic syndromes

!! We **recommend** that the scanning from the epigastrium up to the mesogastrium at the level of umbilicus, in a transverse and longitudinal plane for the detection of aortic abdominal aneurism in case of unexplained shock, abdominal pain, pulsatile mass palpation, presence of emboli, should be considered as basic skill for intensivists.

Assessment of kidneys and urinary tract

!! We **recommend** that B mode US evaluation of both kidneys and bladder in the short and long axis views to assess for the presence or absence of hydronephrosis and bladder overdistention should be considered as basic skill for intensivists.

!! We **recommend** that the US measurement of urine volume in the bladder, to rule in bladder overdistension or unnecessary catheterization should be considered as basic skill for intensivists.

? We are unable to provide any recommendation regarding the assessment of renal Doppler resistive index of the interlobar arteries to predict adverse outcomes and renal failure progression.

Assessment of non-traumatic acute abdomen

!! We **recommend** that abdominal US should not be used alone to identify the cause of a surgical abdomen because it does not reliably characterize different etiologies (e.g., infectious colitis, small bowel obstruction, intussusception and perforation).

!! We **recommend** that the ability to detect hypo/anechoic free fluid in the peritoneal cavity for the identification of free peritoneal fluid to rule in non-traumatic acute abdomen should be considered as basic skill.

!! We **recommend** that the integration of clinical assessment with abdominal US to rule-out non-traumatic acute abdomen should be considered as basic skill.

!! We **recommend against** the use of ultrasound as basic skill for the intensivists in the functional assessment of bowel as the variety of ultrasound parameters that could be assessed is vast.

? We are unable to provide any recommendation regarding the B mode assessment of the gallbladder in the presence of jaundice and elevated liver function tests to evaluate for acute cholecystitis (dilatation of the intrahepatic bile ducts, gallbladder hydrops in conjunction with large gallbladder stones, presence of thickened walls or fluid peripheral collections, presence of biliary sludge or pus).

? We are unable to provide any recommendation regarding the use of the detection of increased echogenicity of the peritoneal stripe with multiple reflection artefacts (A lines) for the identification of free intraperitoneal air to rule in the diagnosis of non-traumatic acute abdomen.

? We are unable to provide any recommendation regarding the US bowel assessment by B-mode as initial evaluation of gastrointestinal tract conditions presenting acutely.

! We **recommend against** the identification of multiple granular echogenic foci within the bowel wall (starry night appearance) for the detection of intramural gas in the bowel wall to rule in the diagnosis of non-traumatic acute abdomen as a basic skill for intensivists.

Assessment of traumatic acute abdomen

!! We **recommend** that the Focused Assessment with Sonography for Trauma (FAST) examination to identify pathological presence of free fluid/blood (i.e., pericardial sac, pleural space and peritoneum) in traumatic acute abdomen should be considered as basic skill.

!! We **recommend** that the integration of clinical assessment with the evaluation of the presence or absence of free peritoneal fluid in traumatic acute abdomen should be considered as basic skill.

!! We **recommend** that FAST examination as an integral component of trauma resuscitation should be considered as basic skill.

! We **recommend against** the assessment of RDRI of the interlobar arteries in hemodynamically stable polytrauma patients in order to promptly detect signs of decompensation due to incipient haemorrhagic shock.

Both traumatic and not traumatic acute abdomen

!! We **recommend** that the use of serial FAST exams in response to changes in the patient's condition in order to visualize the development of previously undetectable free fluids should be considered as basic skill.

!! We **recommend** that the evaluation of the presence of additional internal echoes within the effusion (which suggests the presence of complicated effusions) should be considered as basic skill.

!! We **recommend** that the integration of ultrasound findings with clinical assessment to determine the indication, location for abdominal drainage, monitor the effectiveness of the procedure and rule out drainage complications should be considered as basic skill.





? We are unable to provide any recommendation regarding the use of Doppler ultrasonography of the kidney and spleen through RDRI of the renal interlobar arteries and the main branches of the splenic arteries to promptly detect early signs of splanchnic hypoperfusion in combination with other ultrasound in the context of traumatic or not traumatic acute abdomen.


? NO CONSENSUS **!** WEAK RECOMMENDATION **!!** STRONG RECOMMENDATION **!** WEAK RECOMMENDATION AGAINST **!!** STRONG RECOMMENDATION AGAINST


Fig. 5 continued

VESSELS


Vessels cannulation

-  We **recommend** that the anatomical evaluation of Ultrasound-guided vascular access (USG) for arterial cannulation in case of multiple failed attempts should be considered as basic skill for intensivists.
-  We **recommend** that the anatomical evaluation of Ultrasound-guided vascular access for arterial cannulation when arterial pulse is not palpable should be considered as basic skill for intensivists.
-  We **recommend** that the evaluation of ultrasound scanning of the vessels to detect size, position and patency of the target vessel [by means of compression ultrasonography (CUS)], and to assess surrounding vital structures should be considered as basic skill for intensivists.
-  We **recommend** the continuous visualization of the needle tip during its trajectory both in in and out-of-plane techniques to avoid penetration of the posterior wall of the vessel should be considered as basic skill for intensivists.

 We **recommend** that the anatomical evaluation of US in predicted difficult peripheral venous cannulation or after several failed attempts to improve success and patient's comfort should be considered as basic skill for intensivists.

 We **recommend** evaluation of US as ultrasound-guidance throughout the puncture and the cannulation and post-procedural check in the suspect of immediate life-threatening complications and tip position should be considered as basic skill for intensivists.

Deep venous thrombosis

 We **recommend** that the compression applied from the common femoral vein at the groin to the popliteal vein at the popliteal fossa to rule in deep venous thrombosis (DVT) in case of clinical signs of DVT and/or in patients with risk factors to rule out silent DVT should be considered as basic skill for intensivists.

 NO CONSENSUS  WEAK RECOMMENDATION  STRONG RECOMMENDATION  WEAK RECOMMENDATION AGAINST  STRONG RECOMMENDATION AGAINST

Fig. 5 continued

Abbreviations

A2C: Apical two-chamber view; A4C: Apical four-chamber view; ARDS: Acute respiratory distress syndrome; CUS: Compression ultrasonography; EDA: End diastolic surface area; EDD: End diastolic diameter; FAST: Focused assessment with sonography in trauma; ICU: Intensive care unit; IVC: Inferior vena cava; LV: Left ventricle; RV: Right ventricle; PLAX: Parasternal long-axis view; PSAX: Parasternal short-axis view; PTX: Pneumothorax; RDRI: Renal doppler resistive index; TCCD: Transcranial color Doppler; TCD: Transcranial Doppler; US: Ultrasound; USG: Ultrasound guidance.

Author details

¹ Anesthesia and Intensive Care, Ospedale Policlinico San Martino, IRCCS per l'Oncologia e le Neuroscienze, Genoa, Italy. ² Italy and Department of Surgical Sciences and Integrated Diagnostics (DISC), Genoa, Italy. ³ Department of Critical Care, King's College Hospital, London, UK. ⁴ Anesthesia and Intensive Care Operative Unit, S. Martino Hospital, Belluno, Italy. ⁵ Consultant Intensivist, Head of ICU/RT Department Security Forces Hospital, Dammam, Saudi Arabia. ⁶ Division of Critical Care Medicine, Western University, London, ON, Canada. ⁷ Department of Anaesthesiology and Intensive Care, Biomedical and Clinical Sciences, Linköping University, S-58185 Linköping, Sweden. ⁸ Department of Surgical, Medical and Molecular Pathology and Critical Care Medicine, University of Pisa, Pisa, Italy. ⁹ E.O. Ospedali Galliera, Genoa, Italy. ¹⁰ Interdepartmental Division of Critical Care Medicine, Department of Anesthesia and Pain Management, University Health Network, University of Toronto, Toronto, ON M5G 2N2, Canada. ¹¹ Department of Medicine, Division of Critical Care Medicine, St. Michael's Hospital, Toronto, ON, Canada. ¹² Anesthesiology Institute, Cleveland Clinic, Abu Dhabi, United Arab Emirates. ¹³ Division of Pulmonary, Critical Care and Sleep Medicine, Northwell Health LJI/NSUH Medical Center, Zucker School of Medicine, Hofstra/Northwell, Hempstead, USA. ¹⁴ Humanitas Clinical and Research Center-IRCCS, Rozzano, Milan, Italy. ¹⁵ Anaesthesia and Intensive Care, San Matteo Hospital, Pavia, Italy. ¹⁶ Donald

and Barbara Zucker School of Medicine at Hofstra/Northwell, Hempstead, NY, USA. ¹⁷ Intensive Care Unit, Clinicas Hospital School of Medicine, University of the Republic, Montevideo, Uruguay. ¹⁸ Department of Neurology, Wake Forest Baptist Medical Center, Winston Salem, NC, USA. ¹⁹ Medical Intensive Care Unit and INSERM U1088, Amiens University Hospital, Amiens, France. ²⁰ Department of Intensive Care Medicine, Erasme Hospital, Université Libre de Bruxelles, Brussels, Belgium. ²¹ Medical-Surgical Intensive Care Unit, Inserm CIC 1435, Limoges University Hospital, Limoges, France. ²² Intensive Care Medicine Unit, Assistance Publique-Hôpitaux de Paris, University Hospital Ambroise Paré, Billancourt, 92100 Boulogne, France. ²³ INSERM UMR-1018, CESP, Team Kidney and Heart, University of Versailles Saint-Quentin en Yvelines, Villejuif, France. ²⁴ European Society of Intensive Care Medicine (ESICM), 19 Rue Belliard, Brussels 1040, Belgium.

Acknowledgements

The members of the European Society of Intensive Care Medicine task force for critical care ultrasonography would like to thank the ESICM for the support for the definition and preparation of this manuscript.

Author contributions

CR and AVB designed and coordinated the consensus in all its parts. CR drafted the manuscript, and AVB supervised the project CR is the first author and AVB the senior author of the manuscript. DP performed the statistical analysis and was responsible for the methodology. AW edited and coordinated videos and images production. All the authors: contributed substantially to the conception and design of the study, the acquisition of data, or the analysis and interpretation of the data, provided critical revision of the article, provided final approval of the version submitted for publication.

Funding

None.

Declarations

Conflicts of interest

AW: received honorarium for delivery of educational content from GE, Medasense and Vygon. SM: received fees for lectures from General Electric, outside the present work. ML: received honoraria for lecture from MSD, Edwards, Medtronic and Teleflex. Advisory board for Masimo and Edwards. AM: received travel expenses and registration for meetings, congresses, and courses and lecture fees from Vygon, Edwards and Philips. AS: honorarium and travel/lodging reimbursement for continuing medical education courses and workshops by Society of Critical Care Medicine, Neurocritical care society and American Academy of Neurology. FST: scientific advisor for Nihon Khoden, Eurosets and Neuropics. Received lecture fees for BD and Zoll. AVB: research grant from GSK company. All other authors have no conflicts of interest to declare.

Ethical approval

Not applicable.

Consent to participate

Not applicable.

Open Access

This article is licensed under a Creative Commons Attribution-NonCommercial 4.0 International License, which permits any non-commercial use, sharing, adaptation, distribution and reproduction in any medium or format, as long as you give appropriate credit to the original author(s) and the source, provide a link to the Creative Commons licence, and indicate if changes were made. The images or other third party material in this article are included in the article's Creative Commons licence, unless indicated otherwise in a credit line to the material. If material is not included in the article's Creative Commons licence and your intended use is not permitted by statutory regulation or exceeds the permitted use, you will need to obtain permission directly from the copyright holder. To view a copy of this licence, visit <http://creativecommons.org/licenses/by-nc/4.0/>.

Publisher's Note

Springer Nature remains neutral with regard to jurisdictional claims in published maps and institutional affiliations.

Received: 11 June 2021 Accepted: 16 July 2021

Published online: 5 October 2021

References

- Chen DC, Miloslavsky EM, Winn AS, McSparron JJ (2018) Fellow as Clinical Teacher (FACT) curriculum: improving fellows' teaching skills during inpatient consultation. *MedEdPORTAL J Teach Learn Resour* 14:10728. https://doi.org/10.15766/mep_2374-8265.10728
- Volpicelli G, Elbarbary M, Blaivas M et al (2012) International evidence-based recommendations for point-of-care lung ultrasound. *Intensive Care Med* 38(4):577–591
- Price S, Via G, Sloth E et al (2008) Echocardiography practice, training and accreditation in the intensive care: document for the World Interactive Network Focused on Critical Ultrasound (WINFOCUS). *Cardiovasc Ultrasound*. <https://doi.org/10.1186/1476-7120-6-49>
- Robba C, Poole D, Citerio G et al (2020) Brain ultrasonography consensus on skill recommendations and competence levels within the critical care setting. *Neurocrit Care*. <https://doi.org/10.1007/s12028-019-00766-9>
- Schmidt GA, Blaivas M, Conrad SA et al (2019) Ultrasound-guided vascular access in critical illness. *Intensive Care Med* 45:434–446. <https://doi.org/10.1007/s00134-019-05564-7>
- Hussain A, Via G, Melniker L et al (2020) Multi-organ point-of-care ultrasound for COVID-19 (PoCUS4COVID): international expert consensus. *Crit Care*. <https://doi.org/10.1186/s13054-020-03369-5>
- Wong A, Galarza L, Forni L et al (2020) Recommendations for core critical care ultrasound competencies as a part of specialist training in multidisciplinary intensive care: a framework proposed by the European Society of Intensive Care Medicine (ESICM). *Crit Care*. <https://doi.org/10.1186/s13054-020-03099-8>
- Badri S, Chen J, Barber J et al (2012) Mortality and long-term functional outcome associated with intracranial pressure after traumatic brain injury. *Intensive Care Med* 38:1800–1809. <https://doi.org/10.1007/s00134-012-2655-4>
- Robba C, Goffi A, Geeraerts T et al (2019) Brain ultrasonography: methodology, basic and advanced principles and clinical applications. A narrative review. *Intensive Care Med*. <https://doi.org/10.1007/s00134-019-05610-4>
- Cardim D, Robba C, Bohdanowicz M et al (2016) Non-invasive monitoring of intracranial pressure using transcranial Doppler ultrasonography: is it possible? *Neurocrit Care*. <https://doi.org/10.1007/s12028-016-0258-6>
- Spinello IM (2015) Brain death determination. *J Intensive Care Med*. <https://doi.org/10.1177/08850666135111053>
- Chang JJ, Tsvigoulis G, Katsanos AH et al (2016) Diagnostic accuracy of transcranial Doppler for brain death confirmation: systematic review and meta-analysis. *Am J Neuroradiol* 37:408–414. <https://doi.org/10.3174/ajnr.A4548>
- Mastantuono JM, Combesure C, Elia N et al (2018) Transcranial doppler in the diagnosis of cerebral vasospasm: an updated meta-analysis. *Crit Care Med* 46:1665–1672. <https://doi.org/10.1097/CCM.00000000000003297>
- Donnelly J, Aries MJ, Czosnyka M (2015) Further understanding of cerebral autoregulation at the bedside: possible implications for future therapy. *Expert Rev Neurother* 15:169–185. <https://doi.org/10.1586/14737175.2015.996552>
- Volpicelli G (2011) Sonographic diagnosis of pneumothorax. *Intensive Care Med* 37:224–232. <https://doi.org/10.1007/s00134-010-2079-y>
- Volpicelli G, Boero E, Sverzellati N et al (2014) Semi-quantification of pneumothorax volume by lung ultrasound. *Intensive Care Med* 40:1460–1467. <https://doi.org/10.1007/s00134-014-3402-9>
- Zanobetti M, Coppa A, Nazerian P et al (2018) Chest abdominal-focused assessment sonography for trauma during the primary survey in the emergency department: the CA-FAST protocol. *Eur J Trauma Emerg Surg* 44:805–810. <https://doi.org/10.1007/s00068-015-0620-y>
- Havelock T, Teoh R, Laws D, Gleeson F (2010) Pleural procedures and thoracic ultrasound: British Thoracic Society pleural disease guideline 2010. *Thorax*. <https://doi.org/10.1136/thx.2010.137026>
- Vignon P, Chastagner C, Berkane V, Chardac E, Francois B, Normand S, Bonnard M, Clavel M, Pichon N, Preux PM, Maubon A, Gastinne H (2005) Quantitative assessment of pleural effusion in critically ill patients by means of ultrasonography. *Crit Care Med* 33:1757–1763
- Balik M, Plasil P, Waldauf P et al (2006) Ultrasound estimation of volume of pleural fluid in mechanically ventilated patients. *Intensive Care Med* 32:318–321. <https://doi.org/10.1007/s00134-005-0024-2>
- Vignon P, Chastagner C, Berkane V et al (2005) Quantitative assessment of pleural effusion in critically ill patients by means of ultrasonography. *Crit Care Med* 33:1757–1763. <https://doi.org/10.1097/01.CCM.0000171532.02639.08>
- Melniker LA, Leibner E, McKenney MG et al (2006) Randomized controlled clinical trial of point-of-care, limited ultrasonography for trauma in the emergency department: the first sonography outcomes assessment program trial. *Ann Emerg Med* 48:227–235. <https://doi.org/10.1016/j.annemergmed.2006.01.008>
- Laursen CB, Sloth E, Lassen AT et al (2014) Point-of-care ultrasonography in patients admitted with respiratory symptoms: a single-blind, randomized controlled trial. *Lancet Respir Med* 2:638–646. [https://doi.org/10.1016/S2213-2600\(14\)70135-3](https://doi.org/10.1016/S2213-2600(14)70135-3)
- Cronin B, Khoche S, Maus TM et al (2017) NIH public access. *Intensive Care Med* 22:1–8. <https://doi.org/10.1016/j.nec.2017.12.001>
- Mongodi S, De Luca D, Colombo A et al (2021) Quantitative lung ultrasound: technical aspects and clinical applications. *Anesthesiology*. <https://doi.org/10.1097/aln.0000000000003757>
- You-Ten KE, Siddiqui N, Teoh WH, Kristensen MS (2018) Point-of-care ultrasound (POCUS) of the upper airway. *Can J Anesth* 65:473–484. <https://doi.org/10.1007/s12630-018-1064-8>
- Vivier E, Muller M, Putegnat JB et al (2019) Inability of diaphragm ultrasound to predict extubation failure: a multicenter study. *Chest* 155(6):1131–1139

28. Dinino E, Gartman EJ, Sethi JM, McCool FD (2014) Diaphragm ultrasound as a predictor of successful extubation from mechanical ventilation. *Thorax* 69:423–427. <https://doi.org/10.1136/thoraxjnl-2013-204111>
29. Umbrello M, Formenti P, Longhi D et al (2015) Diaphragm ultrasound as indicator of respiratory effort in critically ill patients undergoing assisted mechanical ventilation: a pilot clinical study. *Crit Care*. <https://doi.org/10.1186/s13054-015-0894-9>
30. Mjølstad OC, Dalen H, Graven T et al (2012) Routinely adding ultrasound examinations by pocket-sized ultrasound devices improves inpatient diagnostics in a medical department. *Eur J Intern Med* 23:185–191. <https://doi.org/10.1016/j.ejim.2011.10.009>
31. Di Bello V, La Carrubba S, Conte L et al (2015) Incremental value of pocket-sized echocardiography in addition to physical examination during inpatient cardiology evaluation: a multicenter Italian study (SIEC). *Echocardiography* 32:1463–1470. <https://doi.org/10.1111/echo.12910>
32. Repessé X, Charron C, Vieillard-Baron A (2016) Assessment of the effects of inspiratory load on right ventricular function. *Curr Opin Crit Care* 22:254–259. <https://doi.org/10.1097/MCC.0000000000000303>
33. Mekontso Dessap A, Boissier F, Charron C et al (2016) Acute cor pulmonale during protective ventilation for acute respiratory distress syndrome: prevalence, predictors, and clinical impact. *Intensive Care Med* 42:862–870. <https://doi.org/10.1007/s00134-015-4141-2>
34. Heiberg J, El-Ansary D, Royse CF et al (2016) Transthoracic and transoesophageal echocardiography: a systematic review of feasibility and impact on diagnosis, management and outcome after cardiac surgery. *Anaesthesia* 71:1210–1221. <https://doi.org/10.1111/anae.13545>
35. Vignon P, Repessé X, Begot E et al (2017) Comparison of echocardiographic indices used to predict fluid responsiveness in ventilated patients. *Am J Respir Crit Care Med* 195:1022–1032. <https://doi.org/10.1164/rccm.201604-0844OC>
36. Vieillard-Baron A, Naeije R, Haddad F et al (2018) Diagnostic workup, etiologies and management of acute right ventricle failure: a state-of-the-art paper. *Intensive Care Med* 44:774–790. <https://doi.org/10.1007/s00134-018-5172-2>
37. Kuhn M, Bonnín RLL, Davey MJ et al (2000) Emergency department ultrasound scanning for abdominal aortic aneurysm: accessible, accurate, and advantageous. *Ann Emerg Med* 36:219–223. <https://doi.org/10.1067/mem.2000.108616>
38. Harrois A, Soyer B, Gauss T et al (2018) Prevalence and risk factors for acute kidney injury among trauma patients: a multicenter cohort study. *Crit Care* 22:344. <https://doi.org/10.1186/s13054-018-2265-9>
39. Barozzi L, Valentino M, Santoro A et al (2007) Renal ultrasonography in critically ill patients. *Crit Care Med*. <https://doi.org/10.1097/01.CCM.0000260631.62219.B9>
40. Giustiniano E, Mecò M, Morengi E et al (2014) May renal resistive index be an early predictive tool of postoperative complications in major surgery? Preliminary results. *Biomed Res Int*. <https://doi.org/10.1155/2014/917985>
41. Boddi M, Bonizzoli M, Chiostrì M et al (2016) Renal Resistive Index and mortality in critical patients with acute kidney injury. *Eur J Clin Invest* 46:242–251. <https://doi.org/10.1111/eci.12590>
42. Jones AE, Tayal VS, Sullivan DM, Kline JA (2004) Randomized, controlled trial of immediate versus delayed goal-directed ultrasound to identify the cause of nontraumatic hypotension in emergency department patients. *Crit Care Med* 32:1703–1708. <https://doi.org/10.1097/01.CCM.0000133017.34137.82>
43. Schleder S, Dendl LM, Ernstberger A et al (2013) Diagnostic value of a hand-carried ultrasound device for free intra-abdominal fluid and organ lacerations in major trauma patients. *Emerg Med J*. <https://doi.org/10.1136/emmermed-2012-201258>
44. Landers A, Ryan B (2014) The use of bedside ultrasound and community-based paracentesis in a palliative care service. *J Prim Health Care* 6:148–151. <https://doi.org/10.1071/hc14148>
45. Viarasilpa T, Panyavachiraporn N, Marashi SM et al (2020) Prediction of symptomatic venous thromboembolism in critically ill patients: the ICU-venous thromboembolism score*. *Crit Care Med*. <https://doi.org/10.1097/CCM.0000000000004306>
46. Beitland S, Wimmer H, Lorentsen T et al (2019) Venous thromboembolism in the critically ill: a prospective observational study of occurrence, risk factors and outcome. *Acta Anaesthesiol Scand* 63:630–638. <https://doi.org/10.1111/aas.13316>
47. Gibson CD, Colvin MO, Park MJ et al (2020) Prevalence and predictors of deep vein thrombosis in critically ill medical patients who underwent diagnostic duplex ultrasonography. *J Intensive Care Med* 35:1062–1066. <https://doi.org/10.1177/0885066618813300>
48. Hirschi R, Hawryluk GWJ, Nielson JL et al (2019) Analysis of high-frequency PbtO₂ measures in traumatic brain injury: insights into the treatment threshold. *J Neurosurg* 131:1216–1226. <https://doi.org/10.3171/2018.4.JNS172604>
49. Bernardi E, Camporese G, Büller HR et al (2008) Serial 2-point ultrasonography plus D-dimer vs whole-leg color-coded Doppler ultrasonography for diagnosing suspected symptomatic deep vein thrombosis: a randomized controlled trial. *JAMA J Am Med Assoc* 300:1653–1659. <https://doi.org/10.1001/jama.300.14.1653>
50. Zhang R, Ni L, Di X et al (2021) Systematic review and meta-analysis of the prevalence of venous thromboembolic events in novel coronavirus disease-2019 patients. *J Vasc Surg Venous Lymphat Disord* 9:289–298.e5. <https://doi.org/10.1016/j.jvsv.2020.11.023>
51. Kapoor S, Chand S, Dieiev V et al (2020) Thromboembolic events and role of point of care ultrasound in hospitalized Covid-19 patients needing intensive care unit admission. *J Intensive Care Med*. <https://doi.org/10.1177/0885066620964392>