



HAL
open science

COVID-19 encephalopathy: detection of antibodies against SARS-CoV-2 in CSF

Daniela Andriuta, Pierre-Alexandre Roger, William Thibault, Benedicte
Toublanc, Chloe Sauzay, Sandrine Castelain, Olivier Godefroy, Etienne
Brochot

► **To cite this version:**

Daniela Andriuta, Pierre-Alexandre Roger, William Thibault, Benedicte Toublanc, Chloe Sauzay, et al.. COVID-19 encephalopathy: detection of antibodies against SARS-CoV-2 in CSF. *Journal of Neurology*, 2020, 267 (10), pp.2810-2811. 10.1007/s00415-020-09975-1 . hal-03591568

HAL Id: hal-03591568

<https://u-picardie.hal.science/hal-03591568v1>

Submitted on 16 Feb 2024

HAL is a multi-disciplinary open access archive for the deposit and dissemination of scientific research documents, whether they are published or not. The documents may come from teaching and research institutions in France or abroad, or from public or private research centers.

L'archive ouverte pluridisciplinaire **HAL**, est destinée au dépôt et à la diffusion de documents scientifiques de niveau recherche, publiés ou non, émanant des établissements d'enseignement et de recherche français ou étrangers, des laboratoires publics ou privés.



COVID-19 encephalopathy: detection of antibodies against SARS-CoV-2 in CSF

Daniela Andriuta¹ · Pierre-Alexandre Roger² · William Thibault¹ · Bénédicte Toublanc^{2,3} · Chloe Sauzay^{4,5} · Sandrine Castelain^{6,7} · Olivier Godefroy¹ · Etienne Brochot^{6,7}

Received: 29 May 2020 / Accepted: 4 June 2020 / Published online: 11 June 2020
© Springer-Verlag GmbH Germany, part of Springer Nature 2020

Dear Sirs,

Although the severe acute respiratory syndrome coronavirus 2 (SARS CoV-2) is known to induce encephalopathy [1, 2] this condition has not yet been well characterized. Furthermore, a reliable cerebrospinal fluid (CSF) biomarker for coronavirus disease 2019 (COVID-19) is currently lacking. Here, we report on the novel clinical and imaging characteristics of two cases of COVID-19 encephalopathy. Notably, we detected anti-SARS-CoV-2 antibodies in the patients' CSF samples.

A middle-aged woman with an unremarkable medical history developed exertional dyspnea after 7 days of fever and anosmia. A CT scan of the thorax showed bilateral

interstitial pneumonia, and a nasopharyngeal swab was positive for SARS CoV-2 in a reverse-transcriptase polymerase chain reaction (RT-PCR) assay. Although the woman had fully recovered from pneumonia by day 11 in the absence of treatment, she progressively developed (from day 16 onwards) gait disturbance and was admitted to our neurology department. A neurological examination showed a slight motor impairment of the lower limbs, pyramidal signs, hypopallesthesia of the four limbs, and bladder and bowel incontinence. Motor and sensory evoked potentials were impaired, indicating supraspinal impairment. Magnetic resonance imaging (MRI) of the spine was normal. Non-contrast-enhanced brain MRI revealed medial mesencephalic hyperintensity with a normal apparent diffusion coefficient (ADC) (Supplementary Figure A). The electroencephalogram and electroneuromyogram were normal.

A middle-aged man with a history of type 2 diabetes, hypertension and dyslipidemia developed severe acute respiratory syndrome in the context of asthenia and fever with bilateral interstitial pneumonia on a CT scan of the thorax. A nasal sample was positive for SARS-CoV-2 in an RT-PCR assay. The man was admitted to the intensive care unit and intubated 3 days later for acute respiratory distress syndrome. Despite the withdrawal of sedation, the patient did not awaken (Glasgow score: 6; eyes: 3; verbal: 1; motor: 2); the pupillary response was maintained, and flaccid tetraparesis was observed. Brain MRI showed bilateral diffuse white matter hyperintensities with a normal ADC. Gadolinium contrast enhancement revealed intense hemorrhagic lesions in both pallidi, with a low ADC (Supplementary Figure B).

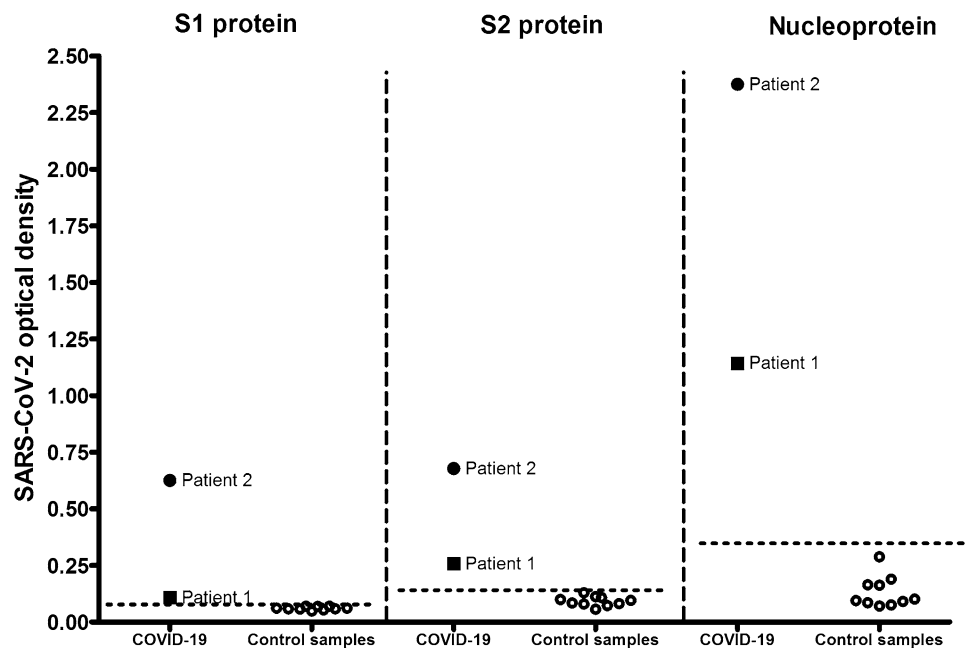
In both cases, exhaustive clinical and laboratory assessments failed to identify an alternative diagnosis for the encephalopathy (e.g., a toxic, metabolic, inflammatory, or infectious cause). The two patients' CSF samples had an elevated protein level, normal cytology results, an elevated glucose level, normal Delpech indices, no intrathecal synthesis

Electronic supplementary material The online version of this article (<https://doi.org/10.1007/s00415-020-09975-1>) contains supplementary material, which is available to authorized users.

✉ Daniela Andriuta
andriuta.daniela@chu-amiens.fr

- ¹ Department of Neurology and Laboratoire de Neurosciences Fonctionnelles et Pathologies (UR UPJV 4559), Amiens University Medical Center and Jules Verne University of Picardy, 80054 Amiens, France
- ² Department of Respiratory Intensive Care Unit and Lung Diseases, Amiens University Medical Center and Jules Verne University of Picardy, Amiens, France
- ³ Department of Pneumology, Amiens University Medical Center and INSERM U1088, Jules Verne University of Picardy, Amiens, France
- ⁴ Department of Biochemistry, Amiens University Medical Center, Amiens, France
- ⁵ CHIMERE Unit, EA7516, Jules Verne University of Picardie, Amiens, France
- ⁶ Department of Virology, Amiens University Medical Center, Amiens, France
- ⁷ AGIR Research Unit ER4294, Jules Verne University of Picardie, Amiens, France

Fig. 1 The contents of CSF samples from COVID-19 patients were allowed to bind to immobilized SARS-CoV-2 S1 protein, S2 protein, and nucleoprotein. To calculate the cutoff, CSF samples collected from other patients in June 2019 were used as negative controls. The cutoff was calculated as the mean plus three standard deviations, and is represented by the dashed horizontal line



of immunoglobulin was observed at isoelectrofocusing (IEF). A “mirrored profile” was detected on each patient’s IEF, suggesting an increased permeability of the hematoencephalic barrier. Furthermore, the samples tested negative in standard bacterial cultures, a meningitis/encephalitis multiplex virus PCR assay, and a specific SARS-CoV-2 PCR assay (Supplementary Table).

To detect SARS-Cov2 antibodies, the two patients’ CSF samples were tested for the presence of SARS-CoV-2 spike 1, spike 2 and nucleoprotein antigens, using ELISAs (The Native Antigen Company, Kidlington, UK; for details of the method, see the Supplementary Appendix). This analysis was approved by institutional review board at Amiens University Hospital (reference: PI2020_843_0048, dated April 24th, 2020). The CSF samples from both patients were strongly positive for the viral nucleoprotein. The signals were weaker for the SARS-CoV-2 spike antigens but still exceeded the assay’s threshold. For each viral antigen, reactivity was greater for patient 2’s samples (Fig. 1). The transudation percentages were 1.08 and 3.12% for patients 1 and 2, indicating that the presence of these antibodies in the CSF was due to transudation.

The present results illustrate the variety of clinical and imaging characteristics of COVID-19 encephalopathy and,

most interestingly, indicate that antibodies against SARS-CoV-2 can be found in the CSF. Although the specificity of this feature remains to be established, it may constitute a critical diagnostic marker.

Compliance with ethical standards

Conflicts of interest The authors report no disclosures of relevance to the manuscript.

Ethical approval The procedures were done in accord with the ethical standards of the Committee on Human Experimentation of the institution in which the experiments were done or in accord with the Helsinki Declaration of 1975.

References

1. Helms J, Kremer S, Merdji H et al (2020) Neurologic features in severe SARS-CoV-2 infection. *N Engl J Med* 382:2268–2270
2. Mao L, Jin H, Wang M et al (2020) Neurologic manifestations of hospitalized patients with coronavirus disease 2019 in Wuhan, China. *JAMA Neurol*. <https://doi.org/10.1001/jamaneurol.2020.1127>