



Celiac axis stenosis and digestive disease: Diagnosis, consequences and management

J. Dembinski, B. Robert, Marie-Antoinette Pietri-Sevestre, M. Freyermuth, T. Yzet, S. Dokmak, Jean-Marc Regimbeau

► To cite this version:

J. Dembinski, B. Robert, Marie-Antoinette Pietri-Sevestre, M. Freyermuth, T. Yzet, et al.. Celiac axis stenosis and digestive disease: Diagnosis, consequences and management. *Journal of Visceral Surgery*, 2021, 158 (2), pp.133-144. 10.1016/j.jviscsurg.2020.10.005 . hal-03595514

HAL Id: hal-03595514

<https://u-picardie.hal.science/hal-03595514>

Submitted on 24 Apr 2023

HAL is a multi-disciplinary open access archive for the deposit and dissemination of scientific research documents, whether they are published or not. The documents may come from teaching and research institutions in France or abroad, or from public or private research centers.

L'archive ouverte pluridisciplinaire **HAL**, est destinée au dépôt et à la diffusion de documents scientifiques de niveau recherche, publiés ou non, émanant des établissements d'enseignement et de recherche français ou étrangers, des laboratoires publics ou privés.



Distributed under a Creative Commons Attribution - NonCommercial 4.0 International License

Celiac axis stenosis and digestive disease: diagnosis, consequences and management

J. Dembinski^{1,2}, B. Robert³, M-A. Sevestre⁴, M. Freyermuth⁵, T. Yzet³, S. Dokmak⁶, J-M. Regimbeau^{1,2}

¹ Department of Digestive Surgery, University Hospital of Amiens Picardie et Université de Picardie Jules Verne, Amiens, France

² Clinical research unit SSPC (Simplifications des Soins des Patients Complexes) UR UPJV 7518, University of Picardie Jules Verne, Amiens, France

³ Radiology Department, University Hospital of Amiens Picardie and Picardie Jules Verne University, Amiens, France

⁴ Vascular Medicine Department, University Hospital of Amiens Picardie and Picardie Jules Verne University, Amiens, France

⁵ Vascular Surgery Department, University Hospital of Amiens Picardie and Picardie Jules Verne University, Amiens, France

⁶ Department of Hepatobiliary Surgery and Liver Transplantation, Assistance Publique-Hôpitaux de Paris and Paris University, Clichy, France

Correspondance :

Professeur J-M Regimbeau

Service de Chirurgie Digestive

CHU Amiens Picardie et Université de Picardie Jules Verne

1 rue du Professeur Christian Cabrol, 80054 Amiens, France

E-mail: regimbeau.jean-marc@chu-amiens.fr

Abbreviations used: CA: Celiac axis; SMA: Superior mesenteric artery; PD: pancreatoduodenectomy

Key words: celiac axis, median arcuate ligament, atheromatous stenosis

Summary:

Arterial blood flow to the organs of the upper abdomen is provided by the celiac axis (CA) and the superior mesenteric artery (SMA) that communicate between each other *via* the gastro-duodenal artery, the anterior and posterior pancreatico-duodenal arcades, the branches of the dorsal pancreatic artery and inconsistently, though a supplementary arcade that connects the CA and the SMA (arcade of Bühler).

Celiac axis stenosis may or may not have a hemodynamic impact on the splanchnic circulation. Hemodynamically significant CA stenosis can be asymptomatic, or symptomatic with protean clinical consequences. Management depends on whether the mechanism of stenosis is extrinsic or intrinsic.

When upper gastrointestinal interventional radiology or surgery is indicated, stenosis can pose technical difficulties or create severe ischemia requiring good understanding of this entity in the planning of operative steps and adapted management. Management of CA stenosis is therefore multidisciplinary and may involve interventional radiologists, gastrointestinal surgeons, vascular surgeons as well as medical physicians.

Even though the prevalence of CA stenosis is relatively low (between 5 and 10%) and irrespective of its etiology, surgeons, radiologists and physicians must be aware of it because it can intervene in the management of upper gastrointestinal disease. It must be sought, and treatment must be adapted to each particular situation to avoid potentially severe complications.

Essential points:

- Celiac axis stenosis can have a hemodynamic impact on the splanchnic circulation; it can be symptomatic or not. The prevalence is between 5% and 10%.
- The most common etiologies are extrinsic stenosis caused by the median arcuate ligament and intrinsic stenosis, related to atherosclerosis.
- Establishment of a positive diagnosis, determination of the etiology and evaluation of the clinical impact all depend on contrast-enhanced abdomino-pelvic CT scan and echo-Doppler studies.
- If interventional radiology or surgery of the upper abdomen is planned, CA stenosis must be systematically sought in order to adapt management plans to avoid technical complications and/or severe ischemic phenomena.

INTRODUCTION

The celiac axis (CA) and the superior mesenteric artery (SMA) provide the arterial blood flow to the upper abdominal viscera; they intercommunicate via the gastroduodenal artery, the anterior and posterior pancreaticoduodenal arcades, the branches of the dorsal pancreatic artery and inconsistently, though a supplementary arcade that courses between the CA and the SMA (arcade of Bühler) [1].

CA stenosis may or may not have a hemodynamic impact on the splanchnic circulation. Hemodynamically significant CA stenosis can be asymptomatic, or symptomatic with protean clinical consequences [2]. Management depends on whether the mechanism of the stenosis is extrinsic or intrinsic.

When upper gastrointestinal interventional radiology or surgery is indicated, CA stenosis poses technical difficulties [3] or can create severe ischemia [4,5], imposing the need for good understanding of this entity in the planning of operative steps and adapted management. The goal of this update is to describe the multidisciplinary management of CA stenosis, which involves interventional radiologists, gastrointestinal and vascular surgeons and medical vascular physicians.

DEFINITION

Extrinsic stenosis: median arcuate ligament compression

Compression of the CA by the median arcuate ligament of the diaphragm, described anatomically by Lipshutz in 1917 [6], is the most frequent cause of extrinsic CA stenosis. It is estimated to be present in 10% of the population [7]. The aorta passes from the chest to the abdomen through the diaphragm via the aortic hiatus; this is bordered posteriorly by the 12th thoracic vertebra and anteriorly by the intermingled fibers of the right and left diaphragmatic crura that form the pre-aortic median arcuate ligament. Thus constituted, the aortic hiatus is osteo-tendinous and relatively rigid, avoiding any influence of respiratory movements on aortic flow. However, this fibrous band can extrinsically compress the CA, angling the first centimeter of the axis downward and flattening it against the aorta. This compression increases during

expiration and chronic compression can cause defective development of the CA with CA hypoplasia. Contributing factors include hypertrophy of the median arcuate ligament or its low-lying insertion, high origin of the CA, abnormal trajectory, and more rarely, associated nervous compression or neuroma or the celiac plexus. Several classifications have been applied to median arcuate ligament-related stenosis, but they are rarely used in current practice. One of these classifications, described specifically for the repercussions of CA stenosis on pancreatoduodenectomy (PD), specifies the degree of stenosis, its length, the distance of stenosis from the aorta and the existence of collateral circulation [8].

Intrinsic stenosis: atheroma

Atheroma, constituted by deposits of lipids and sub-endothelial inflammatory cells, can cause narrowing of the CA. Atheromatous plaques develop mainly in zones of turbulent blood flow, and therefore typically arise near the take-off of the CA.

Other causes

Other much rarer extrinsic causes of CA stenosis include pancreatic tumor invasion of the CA, acute pancreatitis, granuloma formation, or nerve tumors. Other intrinsic causes of CA stenosis include fibromuscular dysplasia, inflammatory diseases (Horton's disease, Takayasu arteritis, polyarteritis nodosa, isolated gastro-intestinal vascularitis without systemic involvement, idiopathic aortitis), arterial elastic tissue anomalies (Type IV Ehler-Danlos syndrome, neurofibromatosis), arterial dissections (isolated, post-traumatic, extension of aortic dissection or syndromic) or other vascular diseases (segmental arterial mediolysis).

DIAGNOSIS

Anatomy

The arterial supply to the upper gastro-intestinal organs is provided by the CA, SMA and their numerous longitudinal and transversal anastomoses.

Several classifications of the anatomic variations of the CA exist for which at least 14 different configurations have been described [10]. The most common configuration, a

common trunk that divides into the left gastric artery and hepato-splenic trunk, is found in 50 to 75% of individuals. Other variations include trifurcation of the CA, a hepato-splenic trunk associated with the left gastric artery arising directly from the aorta, a hepato-mesenteric trunk associated with a gastro-splenic trunk or even a celiac-mesenteric trunk.

Several anatomic variations of the collateral anastomoses between the CA and SMA can co-exist and are important to identify when managing patients with CA stenosis, particularly in interventional radiology (*Figure 1*):

- At the level of the pancreatic head and isthmus: the division of the gastroduodenal artery into the anterior and posterior (superior) pancreaticoduodenal arteries forms the pancreaticoduodenal (Rio Branco) arcade that connects to the SMA *via* one or two inferior pancreatico-duodenal arteries [1]. Their configuration is variable; classically, there are two but there can be up to four different anterior and posterior pancreaticoduodenal arteries, and one or several pancreaticoduodenal arcades can arise directly from the common hepatic artery, sometimes, coursing through the parenchyma of the pancreatic head.

In the presence of modal hepatic artery anatomy, a communication may exist between the SMA and the right branch of the proper hepatic artery, running behind the pancreas, similar to when the right hepatic artery originates from the SMA [11]. Lastly, in presence of anatomic variations of the hepatic artery [12], and in particular, in the presence of a right hepatic artery originating from the SMA or a left hepatic artery originating from the left gastric artery, communications can arise between the proper hepatic artery and the supernumerary hepatic arteries around the portal vein, within the peri-biliary plexus and in the lesser omentum. A right hepatic artery originating from the SMA typically courses along the posterior aspect of the pancreas, or even within the pancreatic parenchyma [13].

- At the level of the pancreatic body: the dorsal pancreatic artery is the first branch originating from the splenic artery in 40% of individuals [1], but it can originate directly from the CA or one of its other branches. This artery divides into several branches that are variable in number and localization:

- Longitudinally, the dorsal pancreatic artery gives rise to a branch in **direct** communication with the SMA, forming the arcade of Bühler, which is independent from the pancreaticoduodenal arcades.
 - Transversally, it can provide a branch to the head and isthmus of the pancreas (arcade of Kirk) that joins the branches of the gastroduodenal artery and a branch that courses to the tail of the pancreas (inferior pancreatic artery) and anastomoses at different levels with branches of the splenic artery.
- At the level of the tail: the branches of the splenic artery anastomose with the transversal branches of the dorsal pancreatic artery (inferior pancreatic artery).

When CA stenosis is hemodynamically significant, the flow in the supra-mesocolic arteries is modified and blood flows preferentially retrograde from the SMA to the main branches of the CA through these collateral pathways (*Figure 2*).

Clinical findings

Hemodynamically significant stenosis, while usually asymptomatic, can be responsible for symptoms such as post-prandial epigastric pain that appears approximately 15 minutes after meals, along with nausea, vomiting and weight-loss. Auscultation reveals a systolic bruit in the epigastric region, which is loudest at the end of expiration. These symptoms can be related to chronic digestive ischemia.

Imaging: positive diagnosis / etiology / impact / associated lesions

Definitive diagnosis rests on CT scan with IV enhancement demonstrating CA stenosis associated with downstream arterial bed dilatation. The sensitivity and specificity of CT scan are 96% and 92%, respectively [4]. Currently, traditional arteriography is no longer used for the definitive diagnosis of stenosis.

CT scan can also point toward an etiologic diagnosis of extrinsic compression by identifying a notch at the origin of the CA suggesting median arcuate ligament

compression (*Figure 3*) or of intrinsic stenosis due to an ostial atheromatous plaque (*Figure 4*).

Evaluation of the hemodynamic impact of CA stenosis on down-stream flow is fundamental before any therapeutic decision. However, contrast-enhanced CT can over-estimate this if the study is performed in full expiration, because the median arcuate ligament impinges on the aorta and increases the image of stenosis [14]. Hemodynamically significant stenosis is better evaluated by echo-Doppler examination. Several authors have published criteria for stenosis. Aburahma *et al.* [15] defined « Peak Systolic Velocity » (PSV) > 320cm/s and « End Diastolic Velocity » (EDV) > 100 cm/s as being associated with > 70% stenosis. Indirect signs of CA stenosis are flow reversal in the gastroduodenal or common hepatic arteries fed by the SMA via the pancreaticoduodenal arcades. Nonetheless, echo-Doppler can yield false results when performed by inexperienced operators or because of variations in body habitus. MRI with contrast, if available, can provide a non-invasive and reliable measure of hemodynamic variations in the gastroduodenal artery related to CA stenosis [16]. Lastly, arteriography can demonstrate whether CA stenosis is hemodynamically significant but, because of its invasiveness, it is preferable to perform this investigation secondarily, notably when treatment of stenosis is envisioned by interventional radiology.

Associated findings supporting the diagnosis include post-stenotic dilatation of the CA, dilated gastroduodenal artery, collateral arterial circulation involving the pancreaticoduodenal arteries and the dorsal pancreatic artery, and aneurysms of the branches related to high arterial flow, most often at the level of the pancreaticoduodenal arcades [17] [18]. Of note, even in the absence of stenosis, enhanced CT scan can fail to visualize the gastroduodenal artery if the study is performed sub-optimally [19]. It is important to evaluate the associated involvement of other arterial pathways, particularly the SMA that can also impact the hemodynamics of upper gastro-intestinal circulation as well as clinical findings. With regard to stenosis of atheromatous origin, other atheromatous plaques should be sought at the level of the aorta and the ostia of its main branches (SMA, renal arteries, inferior mesenteric artery).

MANAGEMENT

Management options

The two main management modalities available to treat CA stenosis are surgical and endovascular. Surgical management consists of either division of the median arcuate ligament, (performed preferentially via laparotomy, although mini-invasive laparoscopic or robotic approaches have been described) or arterial bypass. Endovascular management consists of dilatation of the stenosis, with or without stent insertion. The choice of the modality depends on the etiology of the stenosis and the clinical context.

Extrinsic stenosis

If management of extrinsic stenosis due to median arcuate ligament compression is indicated, management is surgical. Endovascular treatment should not be the first line choice. Harjola in 1963 [20] and Dunbar in 1965 [21] published the original descriptions of surgical treatment of median arcuate ligament compression. Laparotomy is preferred over mini-invasive approaches [22,]23]. Good exposure is critical to this procedure, either by midline extension of a bilateral subcostal incision or by extension of a previous incision, particularly in the obese. Median arcuate ligament compression can be released either via an anterior approach through the lesser omentum above the CA by following the common hepatic artery and back toward the CA after identification of the left gastric artery and the splenic artery. A finger palpating along the CA from top to bottom can identify the fibrotic band formed by the median arcuate ligament. It is then divided step by step over a right-angled dissector, ensuring hemostasis progressively with successive ligations or bipolar coagulation, as needed. Once the arcuate ligament is divided, the origin of the CA and the anterior aspect of the aorta must be freed and visible. This anterior approach can be difficult because of lack of space between the antero-superior aspect of the CA and the arcuate ligament, with an increased risk of injury to the CA during dissection due to its fragility. For this reason, a lateral approach has been described [24]. This second solution requires a Kocher maneuver to mobilize the duodenopancreatic block, exposing the origin of the CA, and also the left renal vein,

the left border of the supra-renal vena cava, the proximal segment of the SMA, as well as the lymph nodes and nerve branches covering the right diaphragmatic crus. The mesenteric lymph nodes to the right of the CA should be clipped or ligated to avoid post-operative chylous leakage while the right sided nerves of the celiac plexus are coagulated. The right crus is divided to the right of the origin of the SMA to expose the median arcuate ligament which presents as a pearly white fibrotic bowstring, 1 to 3 millimeters thick. The median arcuate ligament is then divided along the right border of the SMA, avoiding the superior aspect to facilitate repair in case of a vascular injury (*Figure 5*). The efficacy of the gesture is confirmed by a test clamping of the gastroduodenal artery or an arterial echo-Doppler of the branches (*Figure 6*). If CA blood flow remains insufficient despite this liberation, the median arcuate ligament should be separated from the left and superior aspect of the CA to visualize its origin on the aorta. This maneuver should be performed with extreme caution because of the fragility of the CA in the compression zone. If after this maneuver blood flow is still insufficient, one can consider abandoning arcuate ligament division in favor of a revascularization procedure according to the original surgical indications and the associated symptomatology. Surgical revascularization can be performed with venous autograft (saphenous vein), cryopreserved arterial **graft** or prosthetic bypass. The exact site of the bypass is dictated by local conditions: aorto-celiac, aorto-hepatic, aorto-splenic [25], aorto-gastroduodenal [8] or even resection-anastomosis without interposition [26]. While surgical revascularization is sometimes essential in the context of upper gastro-intestinal surgery (in particular for PD), it is not recommended in case of diagnostic doubt or atypical symptomatology. Several retrospective series have reported the use of laparoscopic or robotic mini-invasive approaches as an alternative to laparotomy for median arcuate ligament release, reporting similar blood loss, shorter hospital stay and cosmetic advantages [27-31] These mini-invasive approaches cannot be recommended because of the risk of injury during the release procedure, a rare but severe and possibly life-threatening complication that is, above all, difficult to repair by the same mini-invasive approach [32]. Endovascular angioplasty associated with stent insertion is not recommended after surgical median arcuate ligament release. Effectively, this procedure is often difficult and dangerous because the hypoplastic tissue is fragile, exposing the patient to the risk of CA rupture during the procedure [33].

Intrinsic stenosis

Three arteries can be involved: CA, SMA and inferior mesenteric artery (IMA). Most patients with digestive artery atherosclerotic disease have aortic lesions that involve two or even all three arteries. Mikkelsen's rule [34,35] stipulates that at least two of the three arteries must be involved before circulatory insufficiency leads to chronic mesenteric ischemia. However, symptomatic mesenteric ischemia from stenosis of a single digestive artery is possible if the anastomotic intercommunication between the various arteries is poor. When symptomatic, atherosclerosis involves preferentially the SMA, then the CA, and less frequently, the inferior mesenteric artery. Most often SMA involvement results in mesenteric ischemia [36]. In a meta-analysis comparing 154 angioplasties to 355 surgical revascularizations of digestive arteries, the SMA was treated in 80% of cases, the CA in 25% and the inferior mesenteric artery in 5% of instances [37].

While atheromatous stenosis of digestive arteries is frequently observed, it is often difficult to establish a clear cause-and-effect relationship between non-specific abdominal symptoms and digestive tract artery anomalies in poly-vascular patients. Treatment of the stenosis without symptom relief is dangerous, submitting the patient to an unwarranted operative risk. Indications for prophylactic revascularization procedures to avoid acute mesenteric infarction are rare and should be performed within a strictly defined framework. Lastly, portal vein pulsed Doppler can be used to verify the responsibility of digestive artery stenoses in the genesis of symptoms; it should be performed in the fasting patient, and then ½ h, one h and 1 ½ hours after a meal. Portal vein flow (in relation to body surface) should increase; no increase or minimal increase in flow confirms mesenteric arterial insufficiency. This is the only functional test available.

When surgical treatment is indicated, the choice of technique depends on atheromatous plaque localization, the number of vascular axes involved, patient condition and symptoms leading to the indication for revascularization [10].

Per-cutaneous endovascular treatment can be performed in the interventional radiology suite or in a hybrid operating room. The CA can be approached via the brachial or femoral artery. The brachial approach is often preferred because it

presents the advantage of having to negotiate only two arterial curvatures to reach the CA while the femoral approach requires the passage of three curvatures, the last of which can be often impossible when the inverted connection angle is too acute [3]. For treatment of atheromatous stenosis by transluminal balloon angioplasty alone or combined with stent insertion, can provide early satisfactory results with low morbidity and mortality. There are no absolute recommendations for platelet anti-aggregant therapy after angioplasty, with or without stent insertion, but the overall consensus [38] is to prescribe double platelet anti-aggregant therapy for one month after the operation, followed by long-term single platelet anti-aggregant therapy. The potential complications of this procedure are plaque embolization (leading to intestinal and/or splenic necrosis), CA thrombosis, CA dissection, distal migration of the stent, and puncture site complications (hematoma, pseudo-aneurysm). Balloon angioplasty seems to provide satisfactory results for atheromatous CA stenosis, irrespective of associated stent placement; conversely, the results of angioplasty associated with stent placement in the SMA seem less durable [39]. Recurrences, if detected early, can be treated by a repeat endovascular procedure before other complications develop [40,41,42].

Otherwise, surgical revascularization should be preferred, notably in case of multiple revascularizations, long-segment stenosis, in young patients, in patients with a high risk of embolism or when exploratory laparotomy is indicted. In a meta-analysis of 43 retrospective studies that included 1795 patients treated for chronic mesenteric ischemia, the success rate was high for both techniques but statistically significantly higher in the surgical group (93% vs. 95%), although at the expense of higher morbidity and mortality (13% vs. 33% and 4% vs. 7%, respectively). The rate of symptom recurrence was higher in patients who underwent endovascular treatment (21% vs. 10%) with, however, the possibility of iterative treatment. There was no difference in 5 year survival [43].

INDICATIONS

Management strategies for CA stenosis outside the context of associated surgery are summarized in *Figure 7*. Management strategies within the context of associated surgery are summarized in *Figure 8*.

Outside the context of upper gastro-intestinal surgery:

- **Median arcuate ligament syndrome**

The median arcuate ligament syndrome is rare, involving 2/100,000 individuals with a 5:1 female predominance [44]. The symptoms leading to diagnosis are non-specific and inconstant (post-prandial epigastric pain, nausea, vomiting, loss of weight) and are not always related to ischemic phenomena, which means that surgical indications should be proposed with caution. The presence of a median arcuate ligament compression should be confirmed by imaging, its impact on blood flow confirmed by arterial echo-Doppler, and all other entities in the differential diagnosis should be eliminated by a gastroenterologist. The degree of stenosis and history of previous abdominal surgery have been reported as risk factors for symptomatic arcuate ligament syndrome [45].

After this exhaustive workup, surgical management consists in division of the median arcuate ligament; this gesture can be insufficient to restore adequate blood flow because of the chronic character of the compression resulting in CA hypoplasia. If arterial flow restoration on echo-Doppler imaging is insufficient, either surgical bypass or careful endovascular stent insertion can be considered [46], but the major character of surgery must be weighed against the severity of symptoms and the confirmed implication of the median arcuate ligament in the symptomatology. The functional results of this surgery seem to correlate with the restoration of arterial flow and the duration of symptoms.

- **Pancreatic arcade aneurysms**

Aneurysms of the pancreatic arcade are rare but warrant recognition because their rupture can lead to life-threatening hemorrhage. They develop due to increased blood flow through the arcades in patients with hemodynamically significant CA stenosis. The clinical picture of ruptured pancreatic arcade aneurysm is non-specific

abdominal pain associated with signs of intra-abdominal hemorrhage, occasionally important and poorly tolerated. The diagnosis is suggested when enhanced CT scan demonstrates an image of hematoma surrounding a pancreatic arcade aneurysm in the pancreatic head or mesocolon (Figure 9). In the absence of CT scan visualization of the aneurysm, traditional angiography can confirm the diagnosis. Non-surgical management relies on embolization of the pancreaticoduodenal arcades *via* the SMA, while surgery is reserved for failure of endovascular treatment. Incidental discovery of pancreatic arcade aneurysm related to CA stenosis requires embolization with the same technique. There is no consensus about division of the median arcuate ligament for this indication [47,48].

- **Necessity of the endovascular approach to the CA**

As indications for supramesocolic arterial interventional radiology increase, interventional radiologists must take CA anatomic variations into account. Many indications require an endovascular catheterization of the CA branches including chemo-embolization, intra-arterial chemotherapy and radio-embolization, as well as hepatic or splenic embolizations for trauma or indications for gastroduodenal artery embolization. When it is impossible to cannulate the CA ostium, the SMA can be catheterized to find a pathway to access the hepatic artery across the pancreaticoduodenal arcades and the gastroduodenal artery. Embolization procedures (simple embolization, chemo-embolization, radio-embolization) can be performed with microcatheters whose small size optimizes the success rate; passing *via* the SMA and the pancreaticoduodenal arcades should be envisioned only in case of failure *via* the CA [49]. In case of splenic trauma with active arterial bleeding, CA stenosis can impede endovascular access to the splenic artery and lead to the need for an emergency splenectomy. For intra-arterial chemotherapy of colorectal liver metastases, the diameter of the material is larger, and CA stenosis requires catheterization through the pancreaticoduodenal arcades *via* the SMA in order to attain the proper hepatic artery [50].

Within the context of upper gastro-intestinal surgery:

- **Esophago-gastrectomy (type Ivor Lewis-Santy)**

The Ivor Lewis-Santy operation, or esophago- (upper pole) gastrectomy with intra-thoracic anastomosis, is indicated for cancer of the middle and lower thirds of the esophagus. It requires a carcinologic resection that preserves the vascularization of the gastric tube used for reconstruction: necrosis of the gastric tube is a rare but severe, life-threatening complication. The team of Lainas *et al.* [5], in a series of 481 Ivor Lewis-Santy interventions, reported a 2.1% rate of necrosis, leading to anastomotic fistula in 90% of cases, re-operation for 70% of these patients with a 30% mortality rate. There were statistically significantly more CA stenoses in the group with necrosis (50% with extrinsic stenosis and 80% with intrinsic stenosis) compared with 0.4% and 2.3%, respectively, in the group without necrosis. CA stenosis (atheromatous or related to the median arcuate ligament) was an independent risk factor for gastric tube necrosis in multivariable analysis. CA stenosis should therefore be sought routinely and treated before performing esophago-gastrectomy, (division of the median arcuate ligament for extrinsic stenosis or stenting of intrinsic stenosis) in case of significant hemodynamic impact on the branches of the CA. Today, certain teams use indocyanine green fluorescence to visualize the gastric tube arterial vascularization intra-operatively [51,52,53].

- **Surgery for bleeding gastroduodenal peptic ulcer**

Bleeding gastroduodenal peptic ulcer is the most common cause of upper digestive hemorrhage; management is based on medical treatment combining proton pump inhibitors, vascular repletion and endoscopic hemostasis. In rare cases of refractory hemorrhagic shock or risk of recurrence as determined by endoscopic examination (Forrest stages Ia, Ib or IIa) associated with at least two failures of endoscopic treatment [54], surgery or alternatively, selective arterial embolization of the bleeding artery is indicated [55,56]. Surgical management is more effective than embolization to stop bleeding, with no difference in morbidity or mortality or risk of rebleeding [57]. Treatment can be conservative, consisting of duodenotomy, suture of the gastroduodenal artery at the base of the ulcer, or better, above and below the pylorus, and pyloroplasty closure, or more radically, oversewing of the gastroduodenal artery and antrectomy [58]. Arteriographic embolization can be impossible anatomically if hemodynamically significant CA stenosis renders access impossible; this imposes the need for surgical management.

- **Gastrectomy distal pancreatectomy with CA resection for locally advanced cancer (Appleby and modified Appleby techniques)**

The Appleby procedure was described in 1953 for locally advanced gastric cancers; it consists of *en bloc* total gastrectomy with left pancreatectomy, splenectomy and resection of the CA, in order to enable extended lymph node dissection [59]. The modified Appleby procedure was described in 1976 for locally advanced pancreatic cancers of the body and tail [60] and entails left spleno-pancreatectomy, resection of the CA and its branches, including the common hepatic artery out to the origin of the gastroduodenal artery [61].

While these operations allow resection of tumors that were long considered unresectable, few series of Appleby resection for gastric cancer have been published [62]. This intervention has developed and is now used essentially for pancreatic cancer. The principle behind this intervention relies on the presence of collateral circulation originating from the SMA with retrograde flow through the pancreaticoduodenal arcades and the gastroduodenal artery to assure hepatic and gastric arterial vascularization. Morbidity in this procedure is dominated by hepatic ischemia (abscess, infarction) and gastric complications (perforation, gastroparesis) [63,64], and every effort must be made to minimize these risks. Test clamping of the hepatic artery, searching for persistence of pulsations in the proper hepatic artery and an echo-Doppler investigation in its branches should be performed before dividing the common hepatic artery; the absence of hepatic artery flow contra-indicates CA resection. Pre-operative embolization of the common hepatic artery, alone or associated with embolization of the two other branches of the CA, can be performed [65,66] in order to enhance the development of collateral circulation to the hepatic artery via the pancreaticoduodenal arcades and to the stomach via the right gastric and right gastro-epiploic arteries and the arcades along the greater and lesser gastric curvatures. If, despite these measure, hepatic artery blood flow remains insufficient, arterial reconstruction (bypass) is necessary [67]. Embolization of the common hepatic artery seems to decrease the need for arterial reconstructions in patients undergoing the modified Appleby procedure [68,69,70]. When the CA is narrowed by the median arcuate ligament, collateral circulation *via* the duodeno-pancreatic arcades and the gastroduodenal artery develops and allows performance of the operation in certain patients without pre-operative embolization or arterial

reconstruction [71]. The same rules detailed above must be applied and, in the absence of development of a collateral arterial network on pre-operative imaging, it is preferable to embolize the CA, sometimes *via* the SMA and the pancreaticoduodenal arcades if the CA is not passable.

- **Pancreatoduodenectomy (PD)**

This operation requires division of the gastroduodenal artery and resection of the duodeno-pancreatic arcades. CA stenosis should be sought routinely pre-operatively because, if hepatic vascularization depends on backflow through the gastroduodenal [72], division of the gastroduodenal artery exposes the patient to hepatic ischemia, gastric and pancreatic complications, and menaces the gastro-jejunal, hepatico-jejunal and pancreatico-jejunal anastomoses [73-75]. The presence of a Dilatation of the pancreatic arcades has been identified as a risk factor for post-operative complications after PD [19]. The key pre-operative examination is enhanced abdomino-pelvic CT scan which can be complemented by echo-Doppler investigation of the digestive arteries and by contrast phase MRI [16] to evaluate the downstream arterial impact.

If there is atherosclerotic intrinsic CA stenosis, endovascular maneuvers should ideally be performed before surgery [76]. For extrinsic CA stenosis, division of the median arcuate ligament, preferentially via the lateral approach is facilitated by the duodeno-pancreatic mobilization. Otherwise, an arterial bypass must be performed during the operation. A classification to guide the revascularization strategy for extrinsic CA stenosis during PD has been published [8] that separates extrinsic stenoses into three types according the degree of stenosis, its length, the distance from the aorta and the existence of arterial collateral circulation.

In each situation, the impact of CA stenosis must be evaluated at surgery by cross-clamping the gastroduodenal artery at its origin and using echo-Doppler to look for decreased or abolished pulsations or decreased flow in the proper hepatic artery [77]. This test clamping must be repeated during the operation because a negative test at the beginning of dissection does not eliminate the possibility of a symptomatic arcuate ligament compensated by the persistence of collateral circulation. In a prospective study of 545 patients before PD, Gaujoux *et al.* [4] detected 62 CA

stenoses, 7 intrinsic (of which four were significant on arterial echo-Doppler) and 55 extrinsic (27 of which were significant). Intrinsic stenoses were treated by pre-operative stent or bypass while extrinsic stenoses were treated by intra-operative division of the median arcuate ligament with an 87% success rate. Ischemic complications were diagnosed in six patients, five of whom died, representing 36% of overall mortality. This underlines the importance of pre-operative detection of arterial stenoses to allow timely treatment.

- **Liver transplantation**

In case of liver transplantation, the hepatic collateral circulation is interrupted and the CA is the only source of arterial blood supply for the liver graft, unless the gastroduodenal artery has been preserved [78]. CA compression must therefore be identified and treated to avoid the severe complications of arterial thrombosis such as ischemic cholangitis with formation of intrahepatic abscess and biliary tract stenoses that can lead to loss of the graft and require repeat transplantation or even lead to death. In a recent series of 286 orthotopic transplantations, the prevalence of extrinsic CA stenosis was 12% while that of intrinsic stenosis was 6% [79]. Pre-operative analysis of receiver CT scans is therefore primordial. The only data in the literature are retrospective cohort studies [79-83] but the approach most commonly followed is to evaluate the flow in the hepatic artery after total hepatectomy. If flow is low, a median arcuate ligament compression must be routinely suspected and released to increase the graft flow. This release will also limit the risk of a vascular steal when the stenosis is associated with liver arterial hypoperfusion dependent on the splenic artery [84] and facilitate potential interventional radiology on the hepatic artery, should that be necessary post-operatively. This procedure is easier to perform before liver implantation when exposure is enhanced, allowing an anterior approach since the Kocher maneuver is often made difficult by portal hypertension. If arcuate ligament release does not restore sufficient arterial blood flow, an arterial bypass is necessary [81]. In case of collateral circulation around the CA making median arcuate ligament release risky or prone to morbidity, performance of an initial CA bypass during the arterial reconstruction of the transplant is recommended. If intrinsic atherosclerotic stenosis is present, it must be treated before liver transplantation; if not, an arterial bypass is necessary.

In the case of living donor liver transplantation, certain authors feel that CA stenosis in the donor is a contra-indication [85]. However, this stenosis does not influence the perfusion of the graft or the remnant because neither the gastroduodenal artery, nor the pancreaticoduodenal arcades are implicated in the hepatectomy. Whereas extrinsic stenosis related to a median arcuate ligament does not seem to impact the post-operative course [86,87] and does not constitute in itself a contra-indication, atherosclerotic intrinsic stenosis is a relative contra-indication [86] because it usually implies diffuse arteriosclerosis which represents a risk factor for biliary ischemia and retransplantation in the long term [88,89].

- **Pseudo-aneurysms**

Pseudo-aneurysm is a blood collection arising from arterial wall rupture but contained by adjacent structures. This complication, observed after acute necrotizing pancreatitis or upper gastro-intestinal (pancreatic, liver or gastric) surgery, is a potential source of life-threatening hemorrhage. Treatment is based on interventional radiology embolization of the pseudo-aneurysm. CA stenosis can require embolization *via* the SMA and the pancreaticoduodenal arcades.

CONCLUSION

In spite of the relatively low prevalence, ranging from 5% to 10%, celiac axis stenosis, irrespective of its etiology, is an entity that surgeons, radiologists and physicians must be aware of, because of its importance in the management of upper digestive disease. CA stenosis has to be detected and treated in a manner adapted to each situation in order to avoid complications that can potentially be severe.

The authors have no conflicts of interest to declare

REFERENCES

- [1] Song S-Y., Chung J. W., Kwon J. W., Joh J. H., Shin S. J., Kim H. B. *et al.*, Collateral pathways in patients with celiac axis stenosis: angiographic-spiral CT correlation, *Radiographics*, 2002, 22(4): 881-893
- [2] Kim E. N., Lamb K., Relles D., Moudgill N., DiMuzio P. J., and Eisenberg J. A., Median arcuate ligament syndrome-review of this rare disease, *JAMA Surg*, 2016, 151(5): 471–477
- [3] Cognet F., Ben Salem D., Dransart M., Cercueil J-P., Weiller M., Tatou E. *et al.*, Chronic mesenteric ischemia: imaging and percutaneous treatment, *Radiographics*, 2002, 22(4): 863-879
- [4] Gaujoux S., Sauvanet A., Vullierme M-P., Cortes A., Dokmak S., Sibert A. *et al.*, Ischemic complications after pancreaticoduodenectomy: incidence, prevention, and management, *Ann. Surg.*, 2009, 249(1): 111–117
- [5] Lainas P., Fuks D., Gaujoux S., Machroub Z., Fregeville A., Perniceni T. *et al.*, Preoperative imaging and prediction of oesophageal conduit necrosis after oesophagectomy for cancer, *Br J Surg*, 2017, 104(10): 1346–1354
- [6] Lipshutz B., A composite study of the coeliac axis artery, *Ann. Surg.*, 1917, 65(2): 159–169
- [7] Horton K. M., Talamini M. A., and Fishman E. K., Median arcuate ligament syndrome: evaluation with CT angiography, *Radiographics*, 2005, 25(5): 1177–1182
- [8] Sugae T., Fuji T., Kodera Y., Kanzaki A., Yamamura K., Yamada S. *et al.*, Classification of the celiac axis stenosis owing to median arcuate ligament compression, based on severity of the stenosis with subsequent proposals for management during pancreatoduodenectomy, *Surgery*, 2012, 151(4): 543–549

- [9] Skeik N., Hyde J. R., Olson S. R., Thaler C. M., Abuatiyeh W., Ahmed A. K. *et al.*, Nonatherosclerotic abdominal vasculopathies, *Ann Vasc Surg*, 2019, 60: 128-146
- [10] White R. D., Weir-McCall J. R., Sullivan C. M., Mustafa S. A., Yeap P. M., Budak M. J. *et al.*, The celiac axis revisited: anatomic variants, pathologic features, and implications for modern endovascular management, *Radiographics*, 2015, 35(3): 879–898
- [11] Noon M. A. and Young S. W., Case report. Aberrant right hepatic artery: a normal variant demonstrated by computed tomography, *J Comput Assist Tomogr*, 1981, 5(3): 411–412
- [12] Gkaragkounis A., Fanariotis M., Tepetes K., Fezoulidis I., and Vassiou K., Celiac trunk and hepatic arteries: anatomical variations of liver arterial supply as detected with multidetector computed tomography in 1,520 patients and its clinical importance, *Clin Anat*, 2019, *Epub ahead of print*
- [13] Rebibo L., Peltier J., Gerin O., Michel D., Robert B., and Regimbeau J-M., Unusual course of the aberrant right hepatic artery running through the pancreatic parenchyma during modified Frey's procedure, *Morphologie*, 2014, 98(323): 182–186
- [14] Suh G-Y., Choi G., Herfkens R. J., Dalman R. L., and Cheng C. P., Three-dimensional modeling analysis of visceral arteries and kidneys during respiration, *Ann Vasc Surg*, 2016, 34: 250–260
- [15] AbuRahma A. F., Stone P. A., Srivastava M., Dean L. S., Keiffer T., Hass S. M. *et al.*, Mesenteric/celiac duplex ultrasound interpretation criteria revisited, *Journal of Vascular Surgery*, 2012, 55(2): 428–436
- [16] Haquin A., Sigovan M., Si-Mohamed S., Mabrut J-Y., Manichon A-F., Bakir M. *et al.*, Phase-contrast MRI evaluation of haemodynamic changes induces by a

coeliac axis stenosis in the gastroduodenal artery, *Br J Radiol*, 2017, 90: 20160802

- [17] Heo S., Kim H. J., Kim B., Lee J. H., Kim J., and Kim J. K., Clinical impact of collateral circulation in patients with median arcuate ligament syndrome, *Diagn Interv Radiol*, 2018, 24(4): 181–186
- [18] Baskan O., Kaya E., Gungoren F. Z., and Erol C., Compression of the celiac artery by the median arcuate ligament: multidetector computed tomography findings and characteristics, *Can Assoc Radiol J*, 2015, 66(3): 272–276
- [19] Nakayama Y., Sugimoto M., Kobayashi T., Gotohda N., Takahashi S., Kusumoto M. *et al.*, Impact of pancreaticoduodenal arcade dilation on postoperative outcomes after pancreaticoduodenectomy, *HPB (Oxford)*, 2018, 20(1): 49–56
- [20] Harjola P. T., A rare obstruction of the coeliac artery. Report of a case, *Ann Chir Gynaecol Fenn*, 1963, 52: 547–550
- [21] Dunbar J. D., Molnar W., Beman F. F., and Marable, S. A., Compression of the celiac trunk and abdominal angina, *Am J Roentgenol Radium Ther Nucl Med*, 1965, 95(3): 731–744
- [22] Landen S., Ballet T., Delugeau V., and Landen C., Laparoscopic approach to median arcuate ligament syndrome (with video), *J Visc Surg*, 2018, 155(2): 159–161
- [23] Do M. V., Smith T. A., Bazan H. A., Sternbergh W. C., Abbas A. E., and Richardson W. S., Laparoscopic versus robot-assisted surgery for median arcuate ligament syndrome, *Surg Endosc*, 2013, 27(11): 4060–4066
- [24] Gaujoux S. and Sauvanet A., Division of the arcuate ligament for compressive stenosis of the celiac axis noted during a pancreaticoduodenectomy, *J Chir*, 145(5): 466–469

- [25] Piardi T., Rhaïem R., Aghei A., Fleres F., Renard Y., Duprey A. *et al.*, Feasibility and safety of spleno-aortic bypass in patients with atheromatous celiac trunk stenosis in pancreaticoduodenectomy, *J. Gastrointest. Surg.*, 2019, 23(4): 882–884
- [26] Grotemeyer D., Duran M., Iskandar F., Blondin D., Nguyen K., and Sandmann W., Median arcuate ligament syndrome: vascular surgical therapy and follow-up of 18 patients, *Langenbecks Arch Surg*, 2009, 394(6): 1085–1092
- [27] De'Ath H. D., Wong S., Szentpali K., Somers S., Peck T, and Wakefield C. H., The laparoscopic management of median arcuate ligament syndrome and its long-term outcomes, *J Laparoendosc Adv Surg Tech A*, 2018, 28(11): 1359–1363
- [28] Cienfuegos J. A., Estevez M. G., Ruiz-Carnela M., Paro F., Diez-Caballero A., Vivas I. *et al.*, Laparoscopic treatment of median arcuate ligament syndrome: analysis of long-term outcomes and predictive factors, *J. Gastrointest. Surg.*, 2018, 22(4): 713–721
- [29] Brody F. and Richards N. G., Median arcuate ligament release, *J. Am. Coll. Surg.*, 2014, 219(4): e45-50
- [30] Khrucharoen U., Juo Y-Y., Chen Y., Jimenez J. C., and Dutson E. P., Short- and intermediate-term clinical outcome comparison between laparoscopic and robotic-assisted median arcuate ligament release, *J Robot Surg*, 2019, 14(1): 123-129
- [31] Weber J. M., Boules M., Fong K., Abraham B., Bena J., El-Hayek K. *et al.*, Median arcuate ligament syndrome is not a vascular disease, *Ann Vasc Surg*, 2016, 30: 22–27
- [32] Riess K. P., Serck L., Gundersen S. B., Sergi M., and Kothari S. N., Seconds from disaster: lessons learned from laparoscopic release of the median arcuate ligament, *Surg Endosc*, 2009, 23(5): 1121–1124

- [33] Ducerf C., Rode A., De la Roche E., Beck F., Adham M., Berthoux N. *et al.*, Compression of the celiac trunk by the diaphragmatic arcuate ligament during supramesocolonic surgery, *Ann Chir*, 1998, 52(6): 495–502
- [34] Mikkelsen W. P. and Zaro J. A., Intestinal angina; report of a case with preoperative diagnosis and surgical relief, *N. Engl. J. Med.*, 1959, 260(18): 912–914
- [35] Van Petersen A. S., Kolkman J. J., Meerwaldt R., Huisman A. B., van der Palen J., Zeebregts C. J. *et al.*, Mesenteric stenosis, collaterals, and compensatory blood flow, *J. Vasc. Surg.*, 2014, 60(1): 111–119
- [36] Chang R. W., Chang J. B., and Longo W. E., Update in management of mesenteric ischemia, *World J. Gastroenterol.*, 2006, 12(20): 3243–3247
- [37] Cluzel P., Auguste M., and Galvez V., Traitement endovasculaire des artères digestives, in *Chirurgie des artères digestives*, AERCv, 1999, 145–153
- [38] Kikano G. E. and Brown M. T., Antiplatelet therapy for atherothrombotic disease: an update for the primary care physician, *Mayo Clin. Proc.*, 2007, 82(5): 583–593
- [39] Turba U. C., Saad W. E., Arslan B., Sabri S. S., Trotter S., Angle J. F. *et al.*, Chronic mesenteric ischaemia: 28-year experience of endovascular treatment, *Eur Radiol*, 2012, 22(6): 1372–1384
- [40] Hodgkiss-Harlow K. D. and Bandyk D. F., Interpretation of arterial duplex testing of lower-extremity arteries and interventions, *Semin Vasc Surg*, 2013, 26(2–3): 95–104
- [41] Baker A. C., Chew V., Li C-S., Lin T-C., Dawson D. L., Pevec W. C. *et al.*, Application of duplex ultrasound imaging in determining in-stent stenosis during

- surveillance after mesenteric artery revascularization, *J. Vasc. Surg.*, 2012, 56(5): 1364–1371
- [42] Lee R. W., Bakken A. M., Palchik E., Saad W. E., and Davies M. G., Long-term outcomes of endoluminal therapy for chronic atherosclerotic occlusive mesenteric disease, *Ann Vasc Surg*, 2008, 22(4): 541–546
- [43] Pecoraro F., Rancic Z., Lachat M., Mayer D., Amann-Vesti B., Pfammatter T. *et al.*, Chronic mesenteric ischemia: critical review and guidelines for management, *Ann Vasc Surg*, 2013, 27(1): 113–122
- [44] Lamba R., Tanner D. T., Sekhon S., McGahan J. P., Corwin M. T., and Lall C. G., Multidetector CT of vascular compression syndromes in the abdomen and pelvis, *Radiographics*, 2014, 34(1): 93–115
- [45] Khrucharoen U., Juo Y-Y., Sanaiha Y., Finn J. P., Jimenez J. C., and Dutson E. P., Factors associated with symptomology of celiac artery compression and outcomes following median arcuate ligament release, *Ann Vasc Surg*, 2020, 62: 248-257
- [46] Reilly L. M., Ammar A. D., Stoney R. J., and Ehrenfeld W. K., Late results following operative repair for celiac artery compression syndrome, *J. Vasc. Surg.*, 1985, 2(1): 79–91
- [47] Chivot C., Rebibo L., Robert B., Regimbeau J-M., and Yzet T., Ruptured pancreaticoduodenal artery aneurysms associated with celiac stenosis caused by the median arcuate ligament: a poorly known etiology of acute abdominal pain, *Eur J Vasc Endovasc Surg*, 2016, 51(2): 295–301
- [48] Ducasse E., Roy F., Chevalier J., Massouille D., Smith M., Speziale F. *et al.*, Aneurysm of the pancreaticoduodenal arteries with a celiac trunk lesion: current management, *J. Vasc. Surg.*, 2004, 39(4): 906–911

- [49] Kwon J. W., Chung J. W., Song S-Y., Lim H. G., Myung J. S., Choi Y. H. *et al.*, Transcatheter arterial chemoembolization for hepatocellular carcinomas in patients with celiac axis occlusion, *J Vasc Interv Radiol*, 2002, 13(7): 689–694
- [50] Ikeda O., Tamura Y., Nakasone Y., and Yamashita Y., Celiac artery stenosis/occlusion treated by interventional radiology, *Eur J Radiol*, 2009, 71(2): 369–377
- [51] Ladak F., Dang J. T., Switzer N., Mocanu V., Tian C., Birch D. *et al.*, Indocyanine green for the prevention of anastomotic leaks following esophagectomy: a meta-analysis, *Surg Endosc*, 2019, 33(2): 384–394
- [52] Kumagai Y., Ishiguro T., Haga N., Kuwabara K., Kawano T., and Ishida H., Hemodynamics of the reconstructed gastric tube during esophagectomy: assessment of outcomes with indocyanine green fluorescence, *World J Surg*, 2014, 38(1): 138–143
- [53] Yukaya T., Saeki H., Kasagi Y., Nakashima Y., Ando K., Imamura Y. *et al.*, Indocyanine green fluorescence angiography for quantitative evaluation of gastric tube perfusion in patients undergoing esophagectomy, *J. Am. Coll. Surg.*, 2015, 221(2): e37-42
- [54] Lau J. Y., Sung J. J., Lam Y. H., Chan A. C., Ng E. K., Lee D. W. *et al.*, Endoscopic retreatment compared with surgery in patients with recurrent bleeding after initial endoscopic control of bleeding ulcers, *N. Engl. J. Med.*, 1999, 340(10): 751–756
- [55] Brehant O., Fuks D., Sabbagh C., Wouters A., Mention C., Dumont F. *et al.*, Surgical management of duodenal ulcer with hemorrhage from the gastroduodenal artery: antrectomy versus conservative surgery?, *J Chir (Paris)*, 2008, 145(3): 234–237
- [56] Loffroy R., Favelier S., Pottecher P., Estivalet L., Genson P. Y., Gehin S. *et al.*, Transcatheter arterial embolization for acute nonvariceal upper gastrointestinal

bleeding: Indications, techniques and outcomes, *Diagn Interv Imaging*, 2015, 96(7–8): 731–744

- [57] Darmon I., Rebibo L., Diouf M., Chivot C., Riault C., Yzet T. *et al.*, Management of bleeding peptic duodenal ulcer refractory to endoscopic treatment: surgery or transcatheter arterial embolization as first-line therapy? A retrospective single-center study and systematic review, *Eur J Trauma Emerg Surg*, 2020, *Epub ahead of print*
- [58] Pautrat K., Valleur P., and Pocard M., Urgent surgery for bleeding duodenal ulcer, *J Chir (Paris)*, 2007, 144(3): 231–235
- [59] Appleby L. H., The coeliac axis in the expansion of the operation for gastric carcinoma, *Cancer*, 1953, 6(4): 704–707
- [60] Nimura Y., Hattori T., Miura K., Nakashima N., and Hibi M., Resection of advanced pancreatic body-ail carcinoma by Appleby's operation., *Shujutu*, 1976, 30:885–889
- [61] Bonnet S., Kohneh-Shahri N., Goere D., Deshayes I., Ayadi S., and Elias D., Indications and surgical technique of Appleby's operation for tumor invasion of the celiac trunk and its branches, *J Chir (Paris)*, 2009, 146(1): 6–14
- [62] Furukawa H., Hiratsuka M., and Iwanaga T., A rational technique for surgical operation on Borrmann type 4 gastric carcinoma: left upper abdominal evisceration plus Appleby's method, *Br J Surg*, 1988, 75(2): 116–119
- [63] Kimura A., Yamamoto J., Aosasa S., Hatsuse K., Nishikawa M., Nishiyama K. *et al.*, Importance of maintaining left gastric arterial flow at Appleby operation preserving whole stomach for central pancreatic cancer, *Hepatogastroenterology*, 2012, 59(120): 2650–2652
- [64] Okada K-I., Kawai M., Tani M., Hirono S., Miyazawa M., Shimizu A. *et al.*, Preservation of the left gastric artery on the basis of anatomical features in

patients undergoing distal pancreatectomy with celiac axis en-bloc resection (DP-CAR), *World J Surg*, 2014, 38(11): 2980–2985

- [65] Hirano S., Kondo S., Hara T., Ambo Y., Tanaka E., Shichinohe T. *et al.*, Distal pancreatectomy with en bloc celiac axis resection for locally advanced pancreatic body cancer: long-term results, *Ann. Surg.*, 2007, 246(1): 46–51
- [66] Kondo S., Katoh H., Shimizu T., Omi M., Hirano S., Ambo Y. *et al.*, Preoperative embolization of the common hepatic artery in preparation for radical pancreatectomy for pancreas body cancer, *Hepatogastroenterology*, 2000, 47(35): 1447–1449
- [67] Latona J. A., Lamb K. M., Pucci M. J., Maley W. R., and Yeo C. J., Modified Appleby procedure with arterial reconstruction for locally advanced pancreatic adenocarcinoma: a literature review and report of three unusual cases, *J. Gastrointest. Surg.*, 2016, 20(2): 300–306
- [68] Klompmaker S., van Hilst Jony, Gerritsen S. L., Adham M., Teresa Albiol Quer M., Bassi C. *et al.*, Outcomes after distal pancreatectomy with celiac axis resection for pancreatic cancer: a pan-european retrospective cohort study, *Ann. Surg. Oncol.*, 2018, 25(5): 1440–1447
- [69] Cesaretti M., Abdel-Rehim M., Barbier L., Dokmak S., Hammel P., and Sauvanet A., Modified Appleby procedure for borderline resectable/locally advanced distal pancreatic adenocarcinoma: a major procedure for selected patients, *J Visc Surg*, 2016, 153(3): 173–181
- [70] Nakamura T., Hirano S., Noji T., Asano T., Okamura K., Tsuchikawa T. *et al.*, Distal pancreatectomy with en bloc celiac axis Resection (modified Appleby procedure) for locally advanced pancreatic body cancer: a single-center review of 80 consecutive patients, *Ann. Surg. Oncol.*, 2016, 23(5): 969–975
- [71] Holoyda K. A., Maley W. R., and Yeo C. J., Enhanced vascular collateralization through the pancreaticoduodenal arcade secondary to median arcuate ligament

compression of the celiac axis in the setting of pancreatic body adenocarcinoma: the ideal scenario for the modified Appleby procedure, *J Pancreat Cancer*, 2017, 3(1): 46–48

- [72] Sakorafas G.H., Sarr M.G., and Peros G., Celiac artery stenosis: an underappreciated and unpleasant surprise in patients undergoing pancreaticoduodenectomy, *J. Am. Coll. Surg.*, 2008, 206(2): 349–356
- [73] Thompson N. W., Eckhauser F. E., Talpos G., and Cho K. J., Pancreaticoduodenectomy and celiac occlusive disease, *Ann. Surg.*, 1981, 193(4): 399–406
- [74] Berney T., Pretre R., Chassot G., and Morel P., The role of revascularization in celiac occlusion and pancreatoduodenectomy, *Am. J. Surg.*, 176(4): 352–356
- [75] Giovanardi F., Lai Q., Garofalo M., Arroyo Murillo G. A., Choppin de Janvry E., Hassan R. *et al.*, Collaterals management during pancreatoduodenectomy in patients with celiac axis stenosis: A systematic review of the literature, *Pancreatology*, 2018, *Epub ahead of print*
- [76] Sauvanet A., Complications chirurgicales des pancreatectomies, *Journal de Chirurgie*, 2008, 145: 103–114
- [77] Bekada S., Le Roux F., Pequignot A., Sabbagh C., and Regimbeau J-M., Lateral access of arcuate ligament in Whipple procedure with video, *J Visc Surg*, 2016, 153(2): 143–144
- [78] Mochizuki T., Ohira M., Hashimoto S., Tahara H., Ide K., Kobayashi T. *et al.*, Utility of doppler ultrasonography in liver transplantation with celiac axis compression syndrome: a case report, *Transplant. Proc.*, 2019, 51(9): 3103–3106
- [79] Czigany Z., Boecker J., Morales Santana D. A., Bednarsch J., Meister F. A., Amygdalos I. *et al.*, Median arcuate ligament compression in orthotopic liver

transplantation: results from a single-center analysis and a european survey study, *J Clin Med*, 2019, 8(4): 550

- [80] Fukuzawa K., Schwartz M. E., Katz E., Mor E., Emre S., Acarli K. *et al.*, The arcuate ligament syndrome in liver transplantation, *Transplantation*, 1993, 56(1): 223–224
- [81] Jurim O., Shaked A., Kiai K., Millis J. M., Colquhoun S. D., and Busuttil R. W., Celiac compression syndrome and liver transplantation, *Ann. Surg.*, 1993, 218(1): 10–12
- [82] Agnes S., Avolio A. W., Magalini S. C., Frongillo F., and Castagneto M., Celiac axis compression syndrome in liver transplantation, *Transplant. Proc.*, 2001, 33(1-2): 1438–1439
- [83] Lubrano J., Scatton O., Randone B., Molinier N., Massault P. P., Legmann P. *et al.*, Median arcuate ligament in orthotopic liver transplantation: relevance to arterial reconstruction, *Transplant. Proc.*, 2008, 40(10): 3532–3535
- [84] Manner M., Otto G., Senninger N., Kraus T., Goerich J., and Herfarth C., Arterial steal: an unusual cause for hepatic hypoperfusion after liver transplantation, *Transpl. Int.*, 1991, 4(2): 122–124
- [85] Marcos A., Ham J. M., Fisher R. A., Olzinski A. T., and Posner M. P., Surgical management of anatomical variations of the right lobe in living donor liver transplantation, *Ann. Surg.*, 2000, 231(6): 824–831
- [86] Akamatsu N., Sugawara Y., Tamura S., Kaneko J., Togashi J., and Makuuchi M., Impact of celiac axis stenosis on living donor hepatectomy, *Transplant. Proc.*, 2006, 38(9): 2948–2950
- [87] Kadry Z., Furrer K., Selzner M., Pfammatter T., and Clavien P-A., Right living donor hepatectomy in the presence of celiac artery stenosis, *Transplantation*, 2003, 75(6): 769–772

- [88] Mourad M. M., Liossis C., Gunson B. K., Mergental H., Isaac J., Muiesan P. *et al.*, Etiology and management of hepatic artery thrombosis after adult liver transplantation, *Liver Transpl.*, 2014, 20(6): 713–723
- [89] Duffy J. P., Hong J. C., Farmer D. G., Ghobrial R. M., Yersiz H., Hiatt J. R. *et al.*, Vascular complications of orthotopic liver transplantation: experience in more than 4,200 patients, *J. Am. Coll. Surg.*, 2009, 208(5): 896-903-905

LIST OF FIGURES

Figure 1. Celiac axis anatomy and anastomoses with the superior mesenteric artery

In red: anastomoses at the level of the head and isthmus of the pancreas. In blue, corporeal anastomoses. In green, distal anastomoses

1. Aorta; 2. Celiac axis; 3. Superior mesenteric artery; 4. Left gastric artery; 5. Right gastric artery; 6. Common hepatic artery; 7. Proper hepatic artery; 8. Gastroduodenal artery; 9. Anterior superior pancreaticoduodenal artery; 10. Posterior superior pancreaticoduodenal artery; 11. Inferior pancreaticoduodenal artery; 12. Right gastro-epiploic artery; 13. Left gastro-epiploic artery; 14. Splenic artery; 15. Dorsal pancreatic artery; 16. Transverse pancreatic arcade (arcade of Kirk); 17. Anastomosis between the celiac axis and the superior mesenteric artery (arcade of Bühler); 18. Inferior pancreatic artery

Figure 2. Schematization of blood flow secondary to compression of the celiac axis by the median arcuate ligament. Volume rendering (VR) CT reconstruction

Supra-mesenteric blood runs off the aorta (1) via the superior mesenteric artery (2), through the pancreaticoduodenal arcades (3) enters the gastroduodenal artery retrograde (4) to vascularize the liver via the proper hepatic artery (5). Blood flow retrograde through the common hepatic artery (6) to vascularize the other branches of the celiac axis (7) the splenic artery (8) and the left gastric artery (9).

Figure 3. CT scan image after injection, maximum intensity projection reconstruction; sagittal and coronal slices. Median arcuate ligament compression of the celiac axis

Arrow: celiac axis stenosis due to median arcuate ligament compression; *: downstream impact with dilatation of the gastro-duodenal artery

Figure 4. CT scan image after injection, sagittal slice and VR reconstruction. Intrinsic stenosis of celiac axis due to arteriosclerosis.

Arrow: celiac axis stenosis atheromatous plaque; * associated involvement of the aorta and superior mesenteric artery

Figure 5. intraoperative view. Lateral approach: division of right crus toward the median arcuate ligament

1. superior mesenteric artery; 2. aorta; 3. right crus of diaphragm and edge of median arcuate ligament; 4. celiac axis

Figure 6. Clamping test by intra-hepatic arterial Doppler

1. before clamping of the gastroduodenal artery; 2. After clamping of the gastroduodenal artery.

Figure 7. Management strategy for celiac axis stenosis outside the surgical context.

LAM= MAL median arcuate ligament; SMA=superior mesenteric artery

Figure 8. Management strategy for celiac axis stenosis within the context of surgery

OGPS: EG esophagogastrectomy; UGD: GDU gastroduodenal ulcer; DP= PD Pancreatoduodenectomy; LA = MAL median arcuate ligament

Figure 9. Ruptured pancreatic arcade aneurysm

A. CT image without injection, axial slice. Retroperitoneal and retro-duodenopancreatic hematoma

B. CT image with injection, VR reconstruction coronal and sagittal slice.

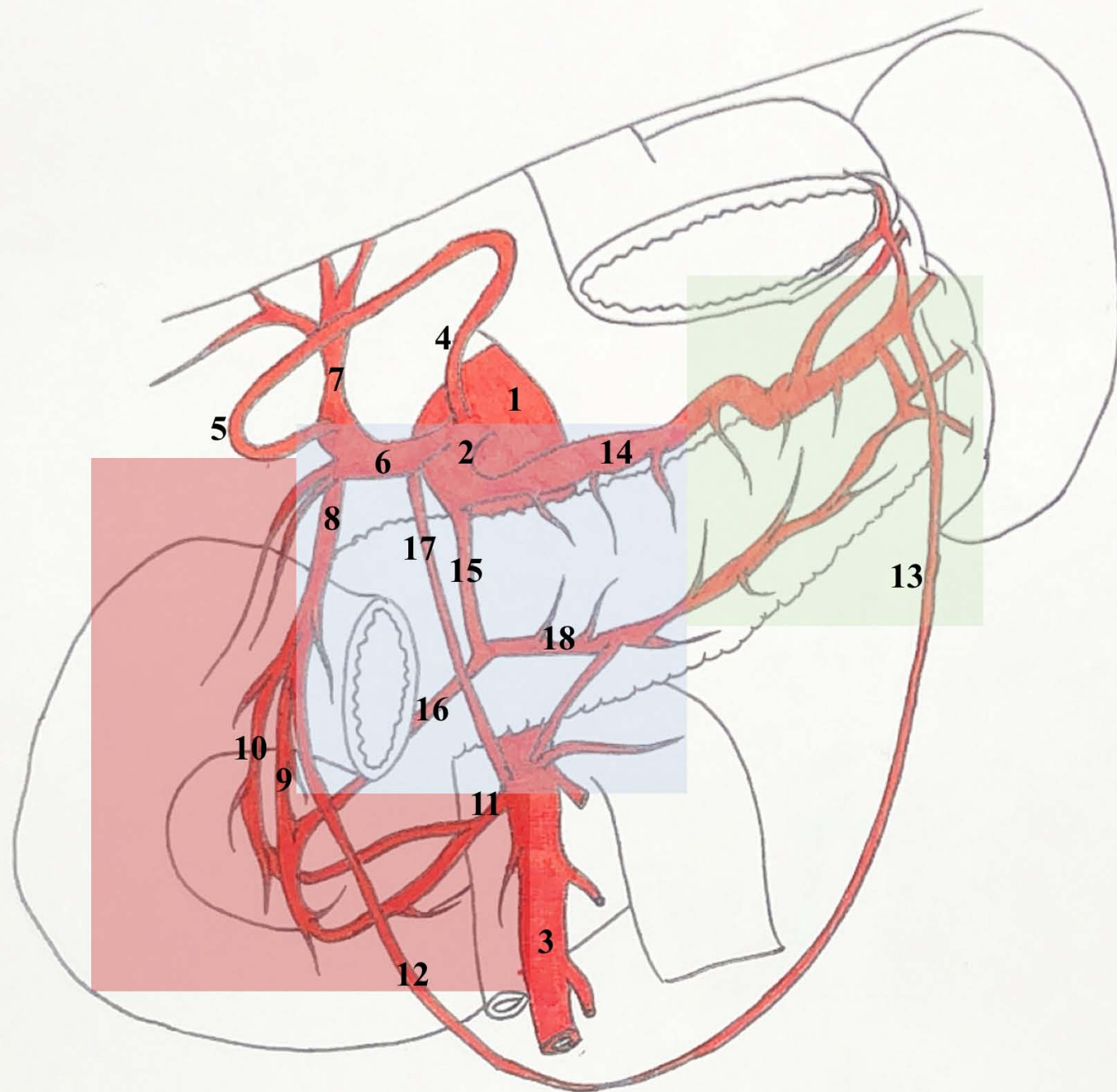
arrow: celiac axis stenosis due to median arcuate ligament compression; *: downstream impact with dysplastic aspect of the gastroduodenal artery

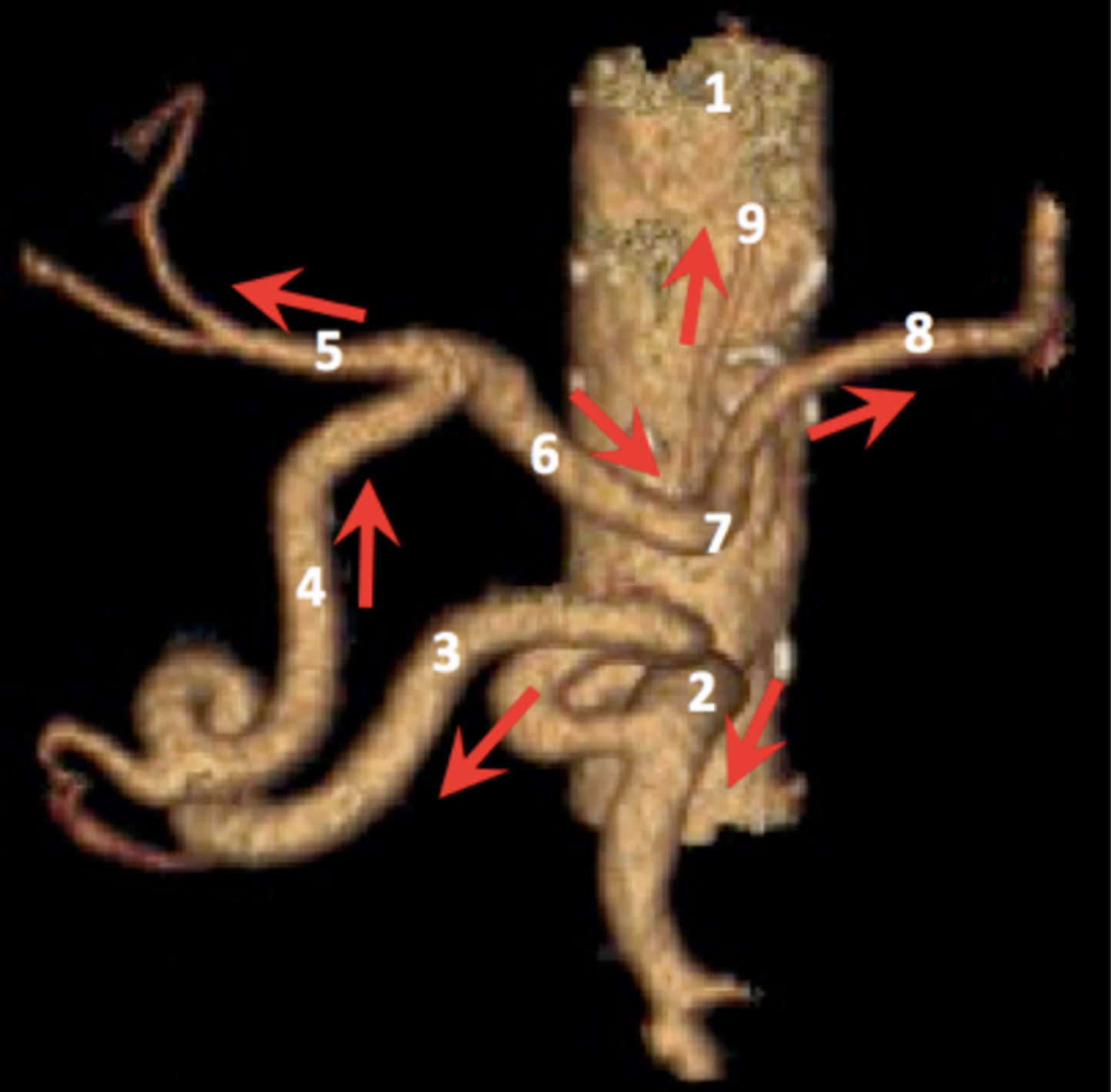
C. Celiac arteriography. Dysplastic aspect of the posterior pancreaticoduodenal artery

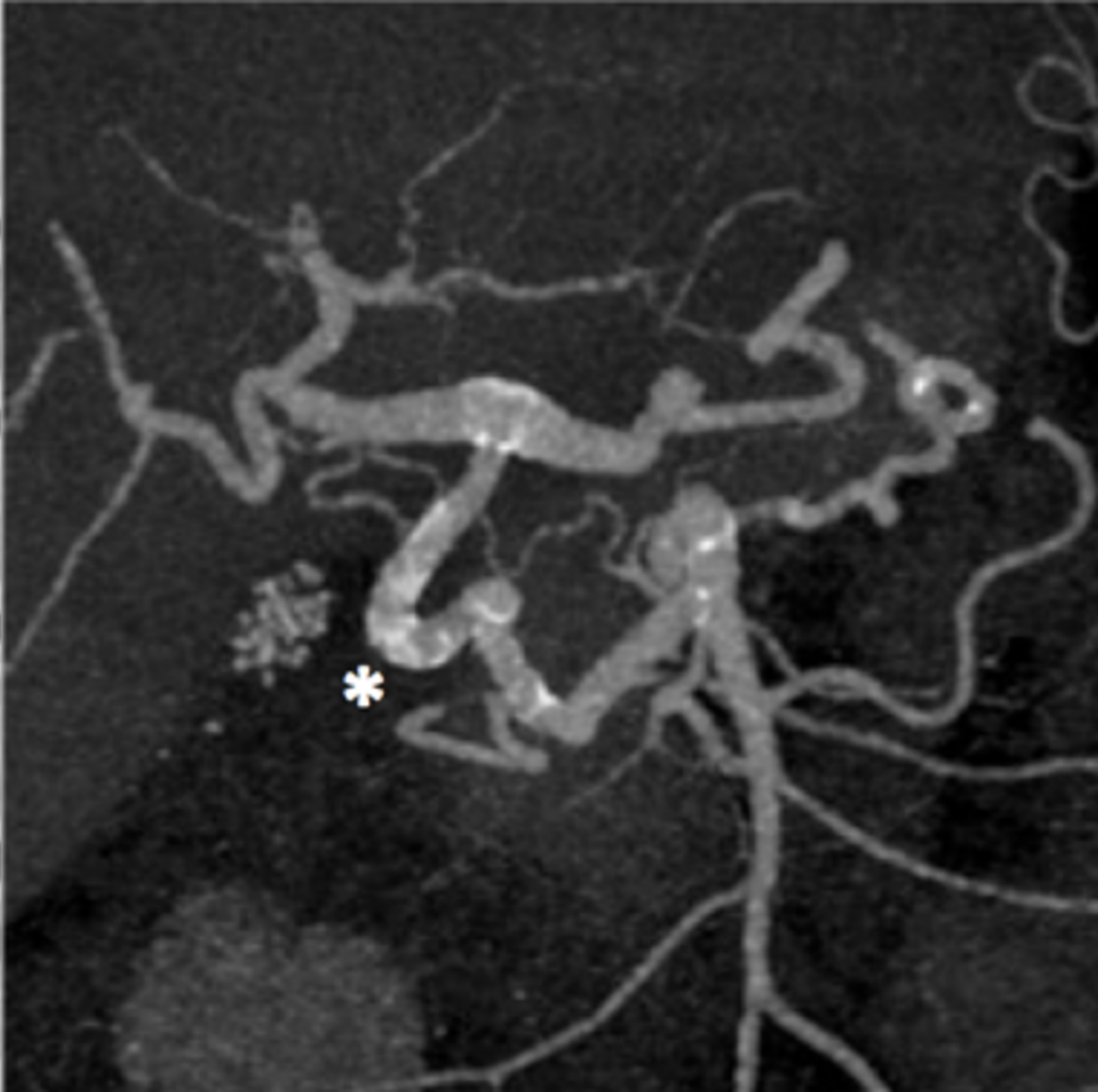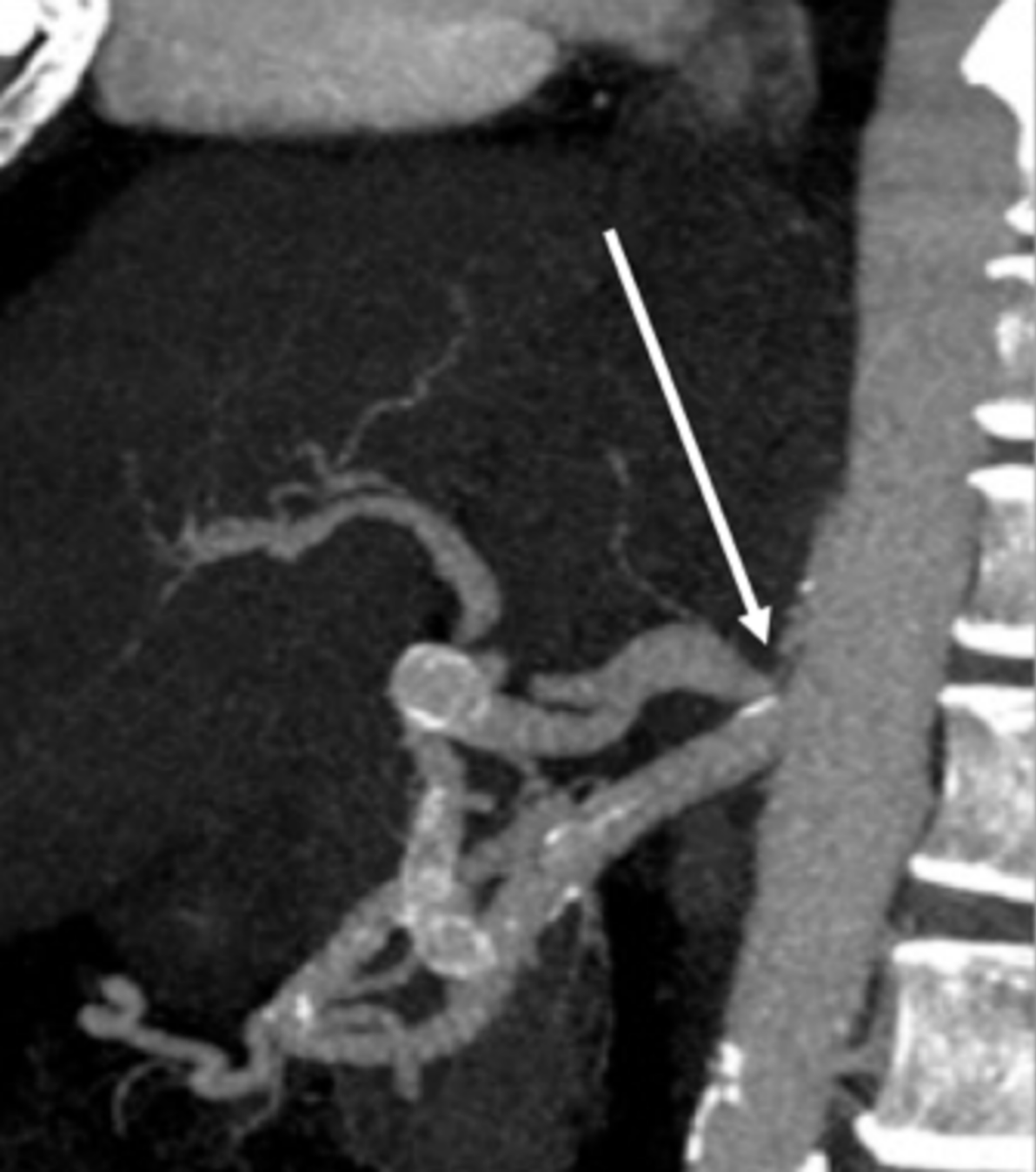
Arrow: micro-aneurysms of the posterior pancreaticoduodenal arcade

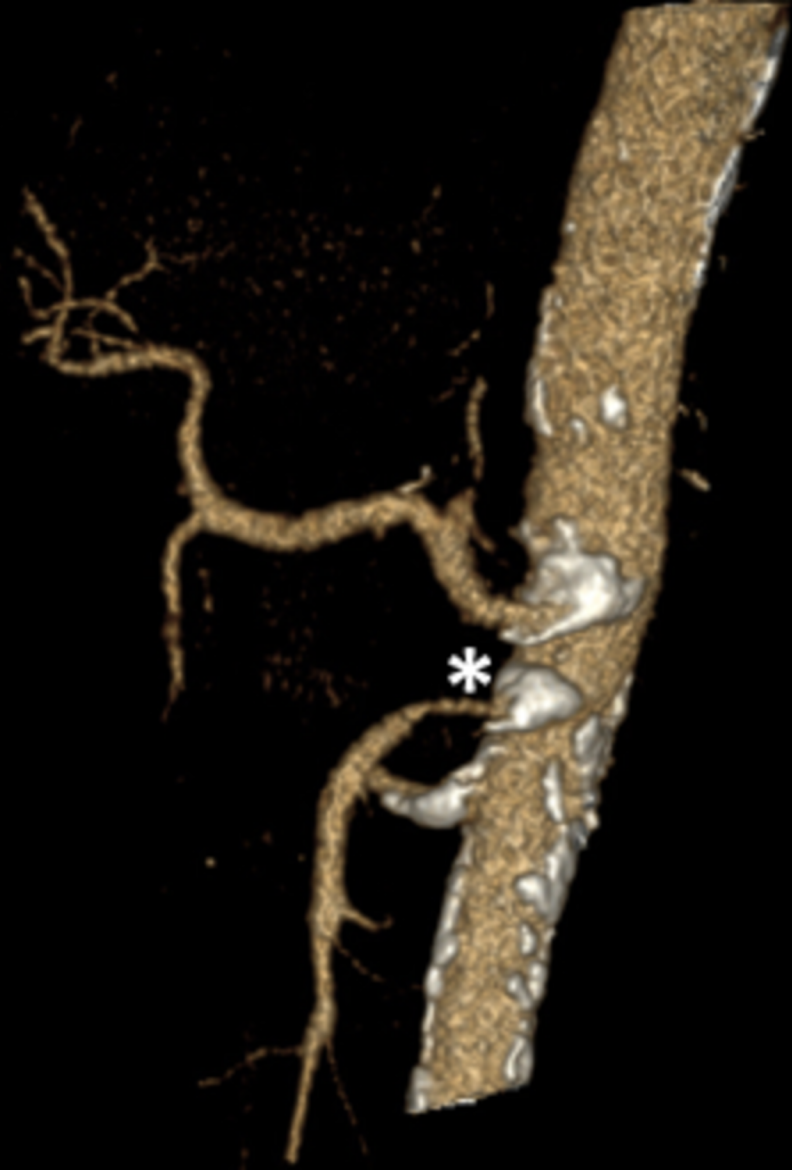
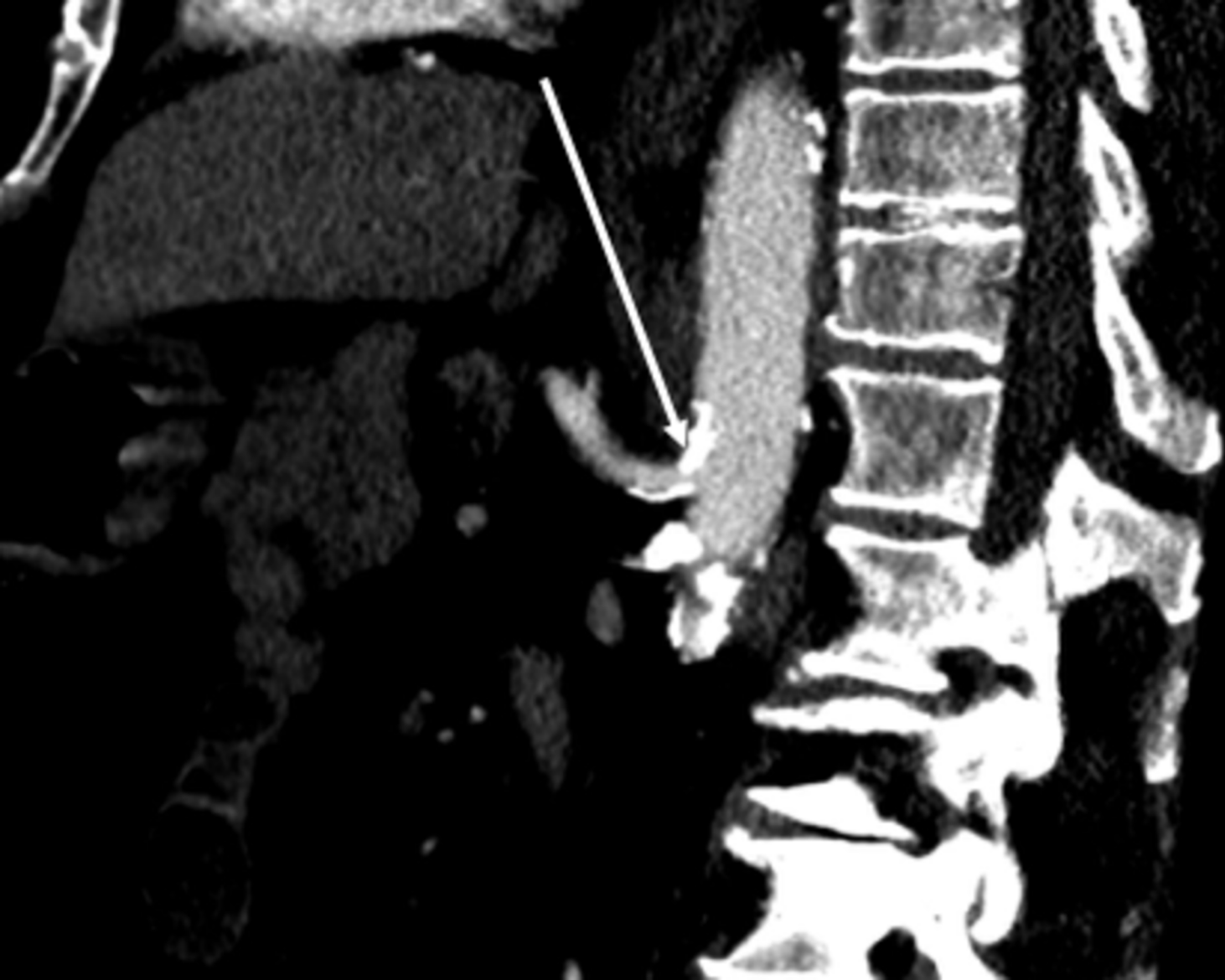D. Celiac arteriography. Active bleeding shown by contrast extravasation, embolization of the pancreaticoduodenal arcade by micro-coils respecting the vascularization *via* the gastro-duodenal artery

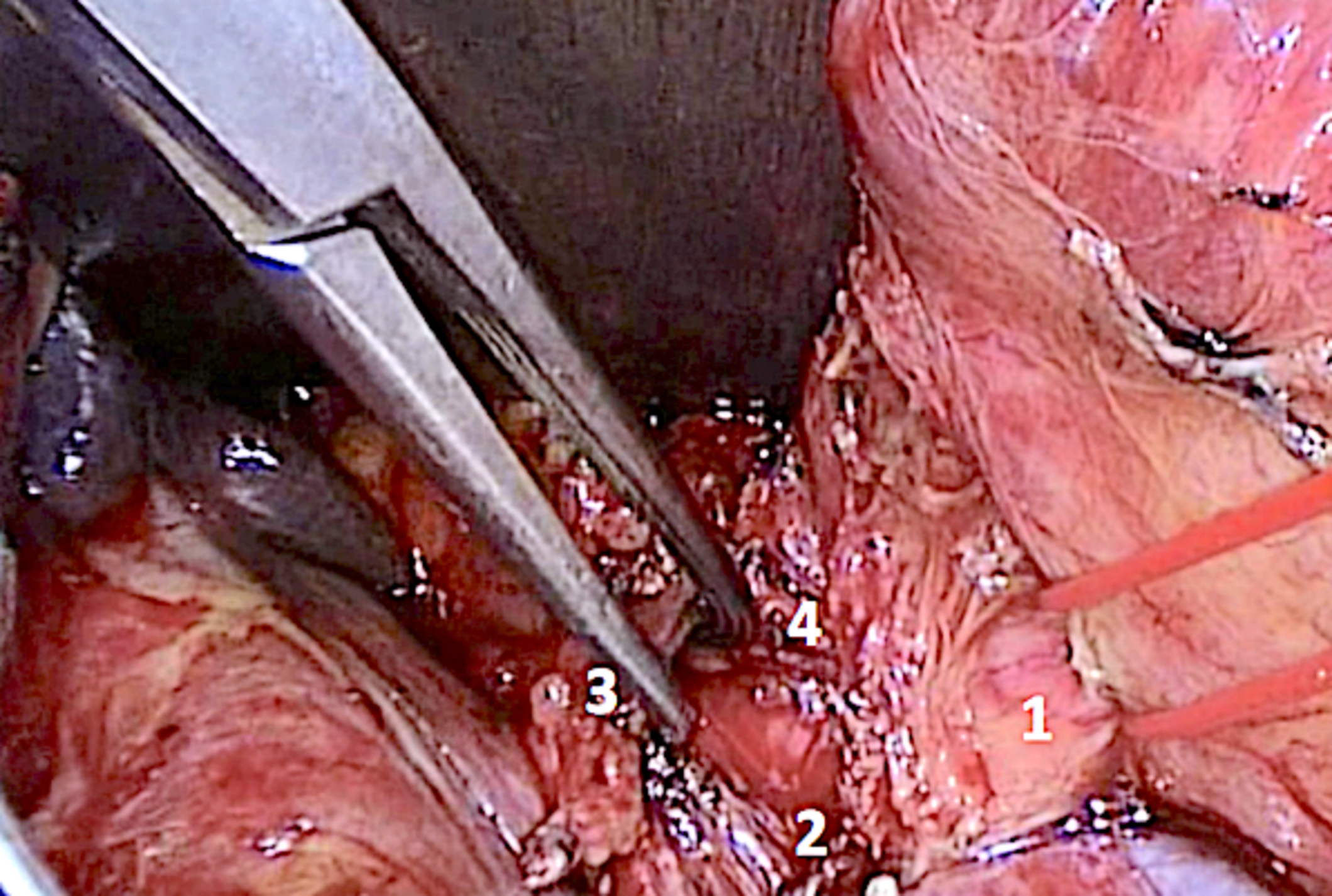
Arrow: contrast material extravasation



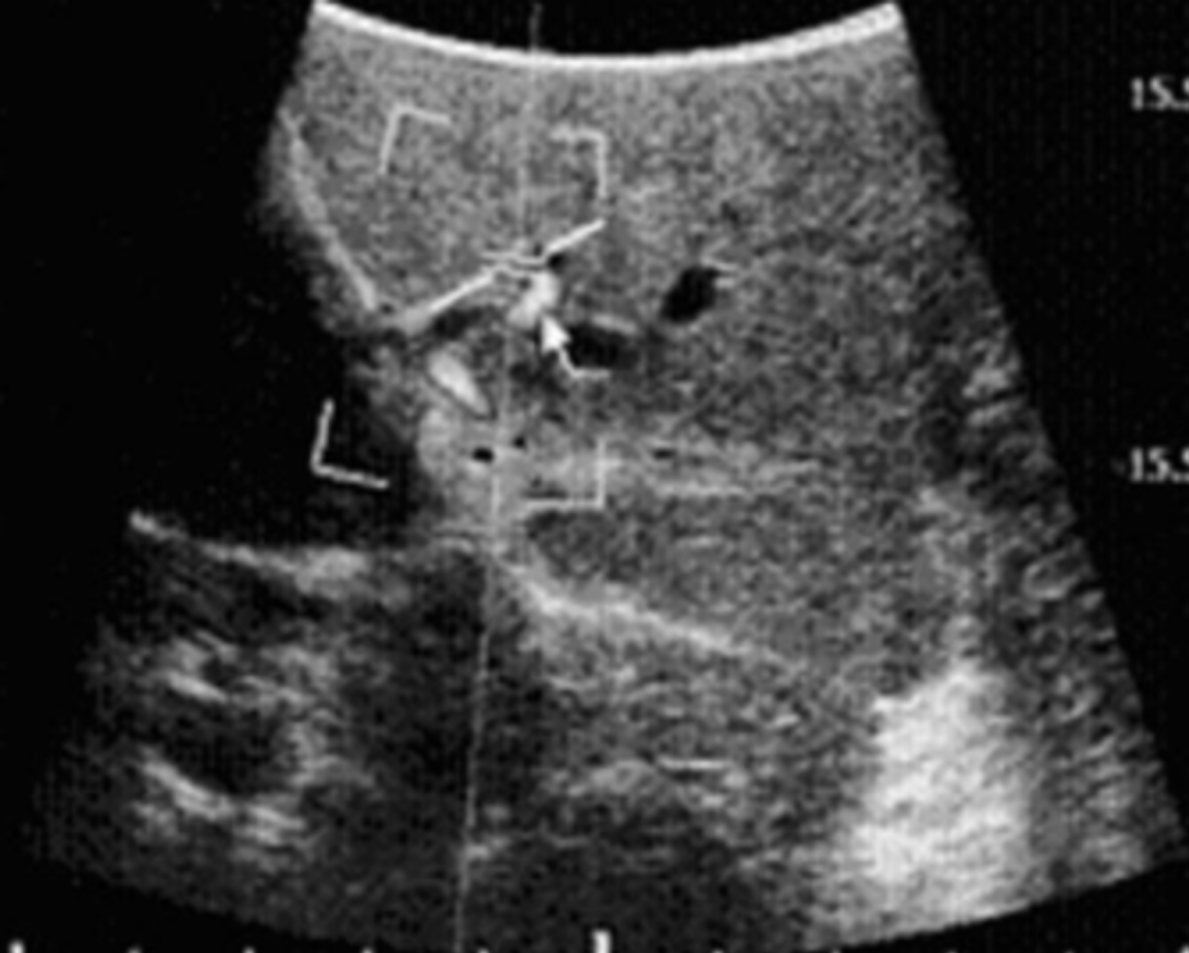







BK Medical
 F: 1.00<1.50
 M: 0.7<2.0
 Rés./Hz 1/17 Hz
 Général
 Couleur
 Doppler
 Gain 50 %
 PRF 2.0 kHz
 1.72 cm 1.0 mm
 60.0°



-0.4 cm/s
 15.5 cm/s
 -15.5 cm/s
 7.3 cm/s
 49.6 cm/s
 12.4 cm/s

Mesures
 S/O
 S/O

	Median arcuate ligament (MAL) syndrome	Pancreatic arcade aneurysm rupture	Celiac artery (CA), endovascular approach required
Stenosis	<i>Extrinsic</i>	<i>Extrinsic</i>	<i>Extrinsic or intrinsic</i>
Indication for management	<ul style="list-style-type: none"> - Symptomatology compatible with MAL - Hemodynamic impact - After extensive workup (search for differential diagnosis) 	<ul style="list-style-type: none"> - Rupture of aneurysm - Incidental discovery of aneurysm 	Simple embolization of CA branches Intra-arterial chemo-embolization Intra-arterial radio-embolization Intra-arterial chemotherapy
Therapeutic possibilities	Surgical lateral approach to CA <i>via</i> laparotomy Mini-invasive approach possible	Embolization of aneurysm <i>via</i> the SMA if CA catheterization is impossible Division of MAL considered	Use of microcatheters, embolization <i>via</i> the SMA if CA catheterization is impossible
Alternatives	In case of failure and valid indication, arterial bypass	Division of MAL if failure of embolization or recurrence	Surgery
Consequences of no management	Persistence of aspecific symptoms	Rupture, hemorrhage	Impossibility of performing what was planned

	EG	Bleeding gastro-duodenal ulcer	Modified Appleby procedure	PD	Liver transplantation	Other (inframesocolic surgery, hepatectomy)
Stenosis	<i>Extrinsic and intrinsic</i>	<i>Extrinsic and intrinsic</i>	<i>Extrinsic and intrinsic</i>	<i>Extrinsic and intrinsic</i>	<i>Extrinsic and intrinsic</i>	<i>Extrinsic and intrinsic</i>
Indication for management	Hemodynamic impact	Intractable hemorrhagic shock Risk of re-bleeding and failure of endoscopic therapy	Absence of development of collateral circulation	Hemodynamic consequences	Hemodynamic impact Extrinsic stenosis even without hemodynamic impact	None
Therapeutic possibilities	Intra-operative MAL release (lateral approach) Pre-operative angioplasty of atheromatous stenosis	Embolization via the SMA Surgical treatment (conservative or radical)	Intra-operative MAL release Pre-operative angioplasty of atheromatous stenosis	Intra-operative MAL release (lateral approach) Pre-operative angioplasty of atheromatous stenosis	Intra-operative MAL release (anterior approach) or initial bypass Pre-operative angioplasty of atheromatous stenosis	
Alternatives			Intra-operative arterial bypass	Intra-operative arterial bypass	Intra-operative arterial bypass	
Consequences of no management	Ischemic complications (gastric tube necrosis)		Complications of liver (abscess, infarction) and gastric (ischemia, gastroparesis) ischemia	Complications of liver and gastric ischemia Anastomotic leak Failure of embolization (hemorrhagic complications)	Thrombosis of arterial anastomosis Complications of liver ischemia (abscess, cholangitis) Re-transplantation	

