



HAL
open science

Strategy and technique for colostomy reversal by laparoscopy after left colectomy with end colostomy (Hartmann procedure)

Baptiste Brac, Charles Sabbagh, Jean-Marc Regimbeau

► To cite this version:

Baptiste Brac, Charles Sabbagh, Jean-Marc Regimbeau. Strategy and technique for colostomy reversal by laparoscopy after left colectomy with end colostomy (Hartmann procedure). *Journal of Visceral Surgery*, 2020, 158 (6), pp.506-512. 10.1016/j.jvisc surg.2020.12.006 . hal-03595649

HAL Id: hal-03595649

<https://u-picardie.hal.science/hal-03595649>

Submitted on 5 Jan 2024

HAL is a multi-disciplinary open access archive for the deposit and dissemination of scientific research documents, whether they are published or not. The documents may come from teaching and research institutions in France or abroad, or from public or private research centers.

L'archive ouverte pluridisciplinaire **HAL**, est destinée au dépôt et à la diffusion de documents scientifiques de niveau recherche, publiés ou non, émanant des établissements d'enseignement et de recherche français ou étrangers, des laboratoires publics ou privés.



Distributed under a Creative Commons Attribution - NonCommercial 4.0 International License

Strategy and technique for colostomy reversal by laparoscopy after left colectomy with end colostomy (Hartmann procedure)

Brac B^{1,2}, Sabbagh C¹⁻³, Regimbeau JM¹⁻³

1. Service de chirurgie digestive, centre hospitalier universitaire Amiens-Picardie, avenue René-Laënnec-Salouël, 80054 Amiens cedex 1, France

2. Université de Picardie-Jules-Verne, Picardie, Amiens, France

3. Unité de Recherche UPJV 7518 SSPC « Simplification des Soins des Patients Complexes » - Université de Picardie Jules Verne, France

Correspondant :

Professor JM Regimbeau, MD, PhD

Department of Digestive Surgery

Amiens University Hospital

Avenue René Laennec, F-80054, Amiens cedex 01, France

E-mail: regimbeau.jean-marc@chu-amiens.fr

Les auteurs déclarent ne pas avoir de liens d'intérêt

Key words: Reversal colostomy, laparoscopy, Hartmann procedure

Hartmann's procedure is a simplified surgical procedure for left colonic resection used mainly in emergency situations in order to reduce post-operative morbidity and mortality. Depending on the underlying pathology and the general condition of the patient, the Hartmann procedure is carried out with the intention to restore intestinal at a later date (which is feasible in 32 to 85% of cases) with post-operative morbidity of 3-50% and mortality of 0-7.1%, respectively (1,2). Although in the majority of cases, the initial intervention is performed by laparotomy, it has been shown that Hartmann reversal (HR), the procedure to restore intestinal continuity, can be performed laparoscopically in 78 to 100% of cases (3). This approach has been associated with benefits in terms of reduced post-operative morbidity, duration of hospital stay, post-operative ileus and parietal infections (3-5).

Figure 1: Patient setup

The patient is positioned supine as for a two-team laparoscopic left colectomy. The two arms lie alongside the body, with shoulder pads and a bladder catheter that may lie within the operative field (optional). The operator starts the operation on the patient's left side (stoma removal and laparoscopic viscerolysis), and then moves to the right for the rest of the operation.

Figure 2: Global strategy for laparoscopic Hartmann reversal

We propose here a technique for an all laparoscopic HR with a strategy of dissection in two stages: a first stage of abdominal viscerolysis (abdominal wall and enterolysis) and, if possible, a stage of pelvic viscerolysis (enterolysis and freeing of the rectal stump). This makes it possible to limit the size of the incision (in the event that conversion becomes necessary) to an infra-umbilical incision for the pelvic stage, without necessarily increasing the operating time. It is therefore necessary to operate "with the intention of an all-laparoscopic HR" on

all patients. The indications for laparoscopy, on the other hand, must be reasonable so that the operative approach does not become deleterious for the patient (for example, HR in a patient with a ventral hernia).

Figure 3: Feasibility of optical trocar insertion to enable placement of first trocars

The procedure begins with dissection to free the stoma from the abdominal wall. The dissection of the colostomy is made in direct contact with the intestine down to the rectus fascia, avoiding injury to the mesocolon so as not to damage the arcade of Drummond. Viscerolysis (**B**) is then performed as far into the abdomen as possible through the ostomy opening, dissecting toward the old midline scar. Dissection is carried up to the umbilicus (**A**) in order to facilitate the laparoscopic phase by enabling insertion of the umbilical optical trocar (**a**) under visual control through the ostomy opening (prevention of a trocar-associated intestinal wound). A plastic skirt with two wall-retracting rings (**b**) is inserted through the ostomy wound, which can be made air-tight around a trocar (**c**). If this step proves unfeasible, the surgeon may choose to proceed to a midline laparotomy. If the laparoscopic approach is to be pursued, the anvil of the end-to-end mechanical stapler is inserted into the proximal colon for an eventual stapled colorectal anastomosis. The rest of the operation is performed according to the strategy described in **Figure 2**, with two distinct dissection phases: an initial abdominal phase followed by a pelvic phase. A 12mm trocar is placed through the double ring skirt and then a 12mmHg pneumoperitoneum is insufflated.

Figure 4: Feasibility of parietal viscerolysis and introduction of the working trocars

In the absence of parietal adhesions - which is sometimes the case - three 5 mm trocars are introduced in the left hypochondrium, right hypochondrium, and right iliac fossa. If abdominal wall adhesions prevent visualized placement of these

trocars, the camera is introduced *via* the stomal orifice trocar **(a)** and viscerolysis is started using dissecting instruments *via* the umbilical trocar **(b)** and a 5mm trocar inserted in the left hypochondrium **(c)** in an area cleared of adhesions during the stoma removal. The location of the rest of the trocars **(d)** will depend on which areas can be freed of adhesions. If it is not possible to continue with trocar placement safely, conversion to midline laparotomy should be considered. Complete release of the parietal adhesions of the submesocolic area is necessary in order to be able to continue the operation without difficulty. However, complete small intestinal viscerolysis is not necessary in most cases and could lead to intestinal injury.

Figure 5: Feasibility of laparoscopic mobilization of the splenic flexure and/or colon (if necessary)

The mobility of the descending colon should be promptly assessed to see whether it can be brought down into the pelvis for a tension-free anastomosis. If mobilization of the colon by the laparoscopic route proves impossible, the HR should be converted to a midline laparotomy. On the other hand, if the gesture is feasible, a complete liberation of the descending colon, and omental/small intestinal adhesions is performed. If there is tension on the liberated colon in the pelvis, several options may be considered: if the splenic flexure was not freed during the first operation, it must now be freed. If the colon still lacks sufficient mobility, the inferior mesenteric vein can be divided.

Figure 6: Feasibility of pelvic viscerolysis

At this stage, it is important to assess the extent of the small bowel adhesions in the pelvis and in the left iliac fossa to evaluate whether pelvic adhesions can be lysed laparoscopically. If not, conversion to open laparotomy may be necessary. Since the colon has already been mobilized, a conversion may require only a limited infra-umbilical laparotomy incision. The pelvis is completely freed from

adhesions and the rectal stump is identified by the non-absorbable monofilament sutures left at the ends of the running hemostatic suture that overran the stapled closure of the rectal stump during the initial intervention (6).

Figure 7: Dissection of the rectal stump

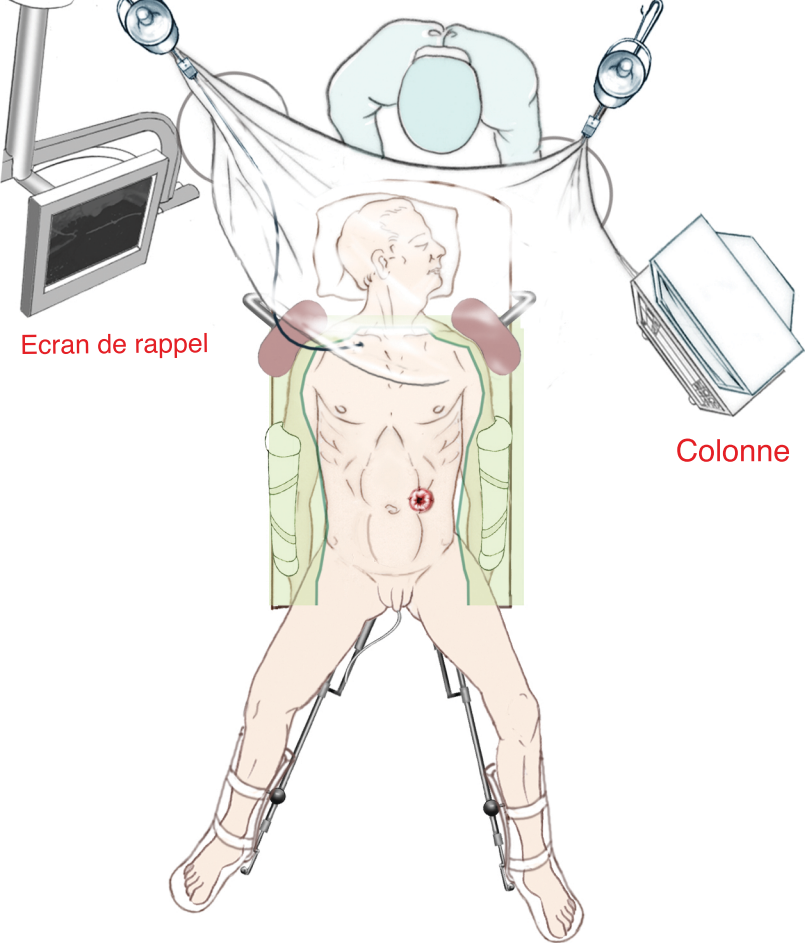
A dilator or bougie introduced *via* the anus will facilitate identification and dissection of the rectal stump. The rectal stump should be sufficiently mobilized to allow the performance of the stapled anastomosis. If the rectal stump is too long, it can be dissected and staple/transected at a lower level.

Figure 8: Performing colorectal anastomosis

A standard colorectal stapled anastomosis is then performed. The anastomosis should be air-tested for leaks. We do not recommend the placement of a peri-anastomotic drain, nor the routine performance of a protective ileostomy.

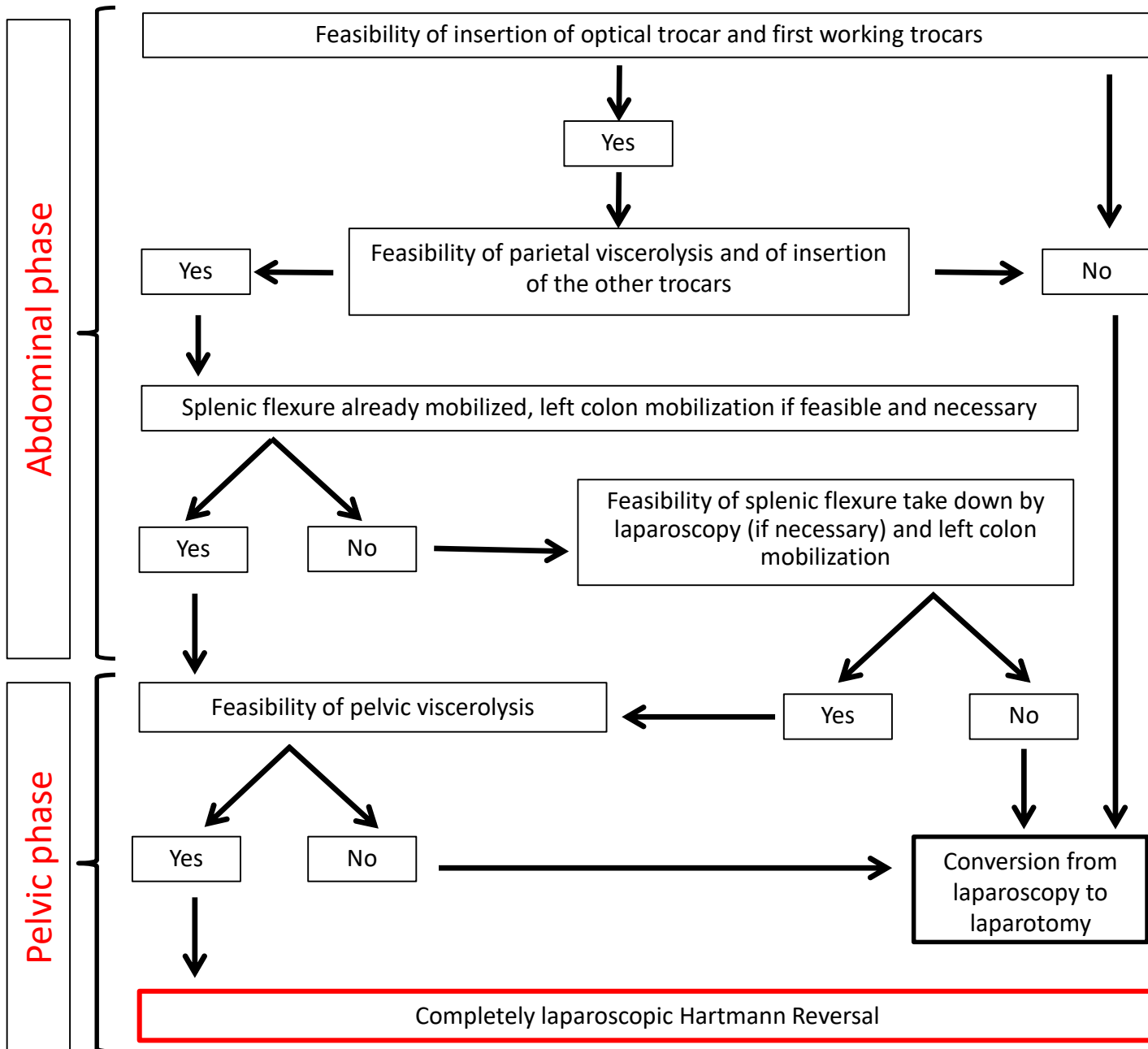
Conclusion

The reversal of a Hartmann procedure by laparoscopy is a safe and feasible procedure in more than 70% of cases and offers a benefit to the patient in terms of the post-operative course.

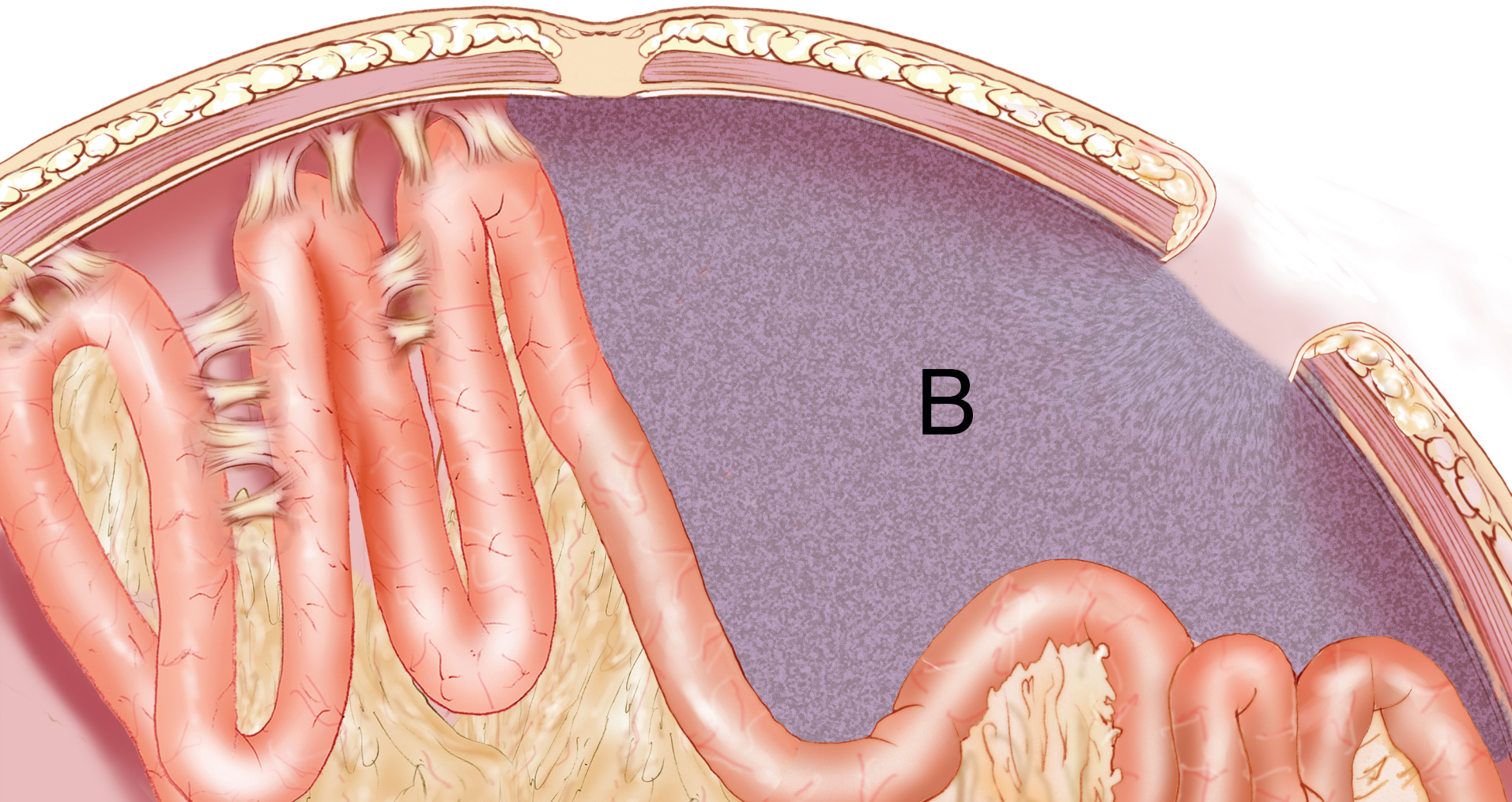


Ecran de rappel

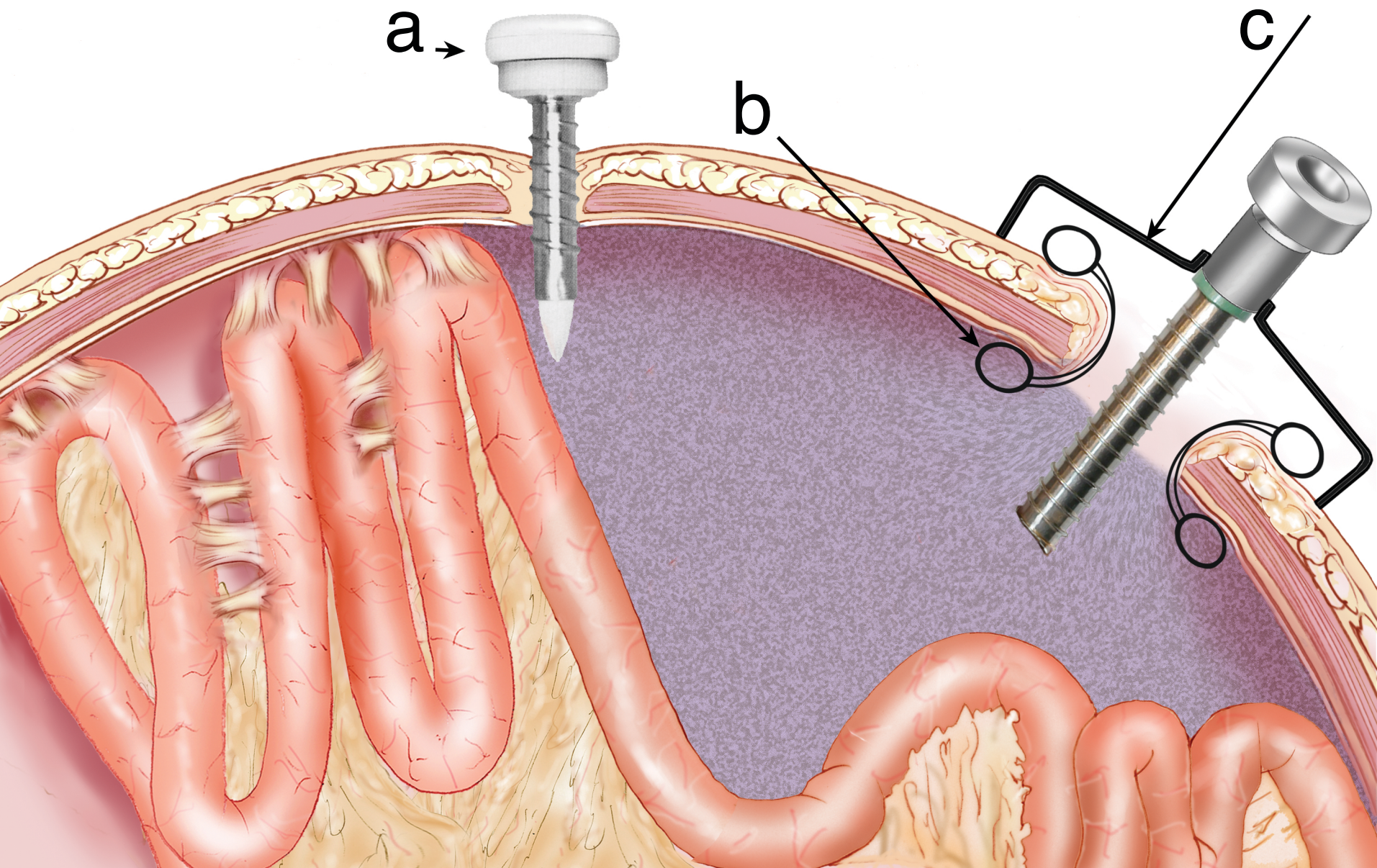
Colonne

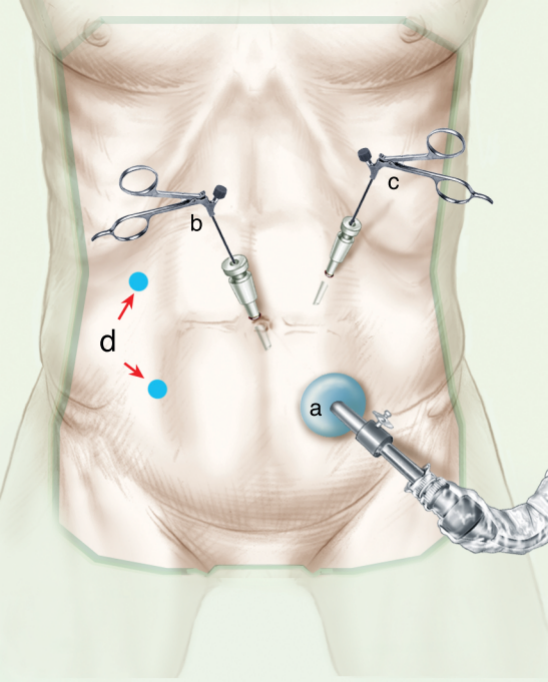


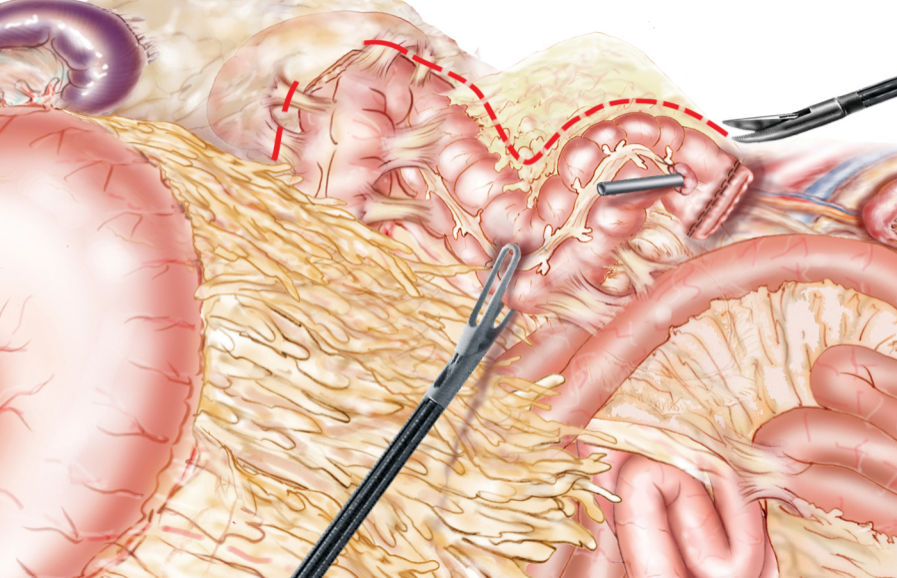
A

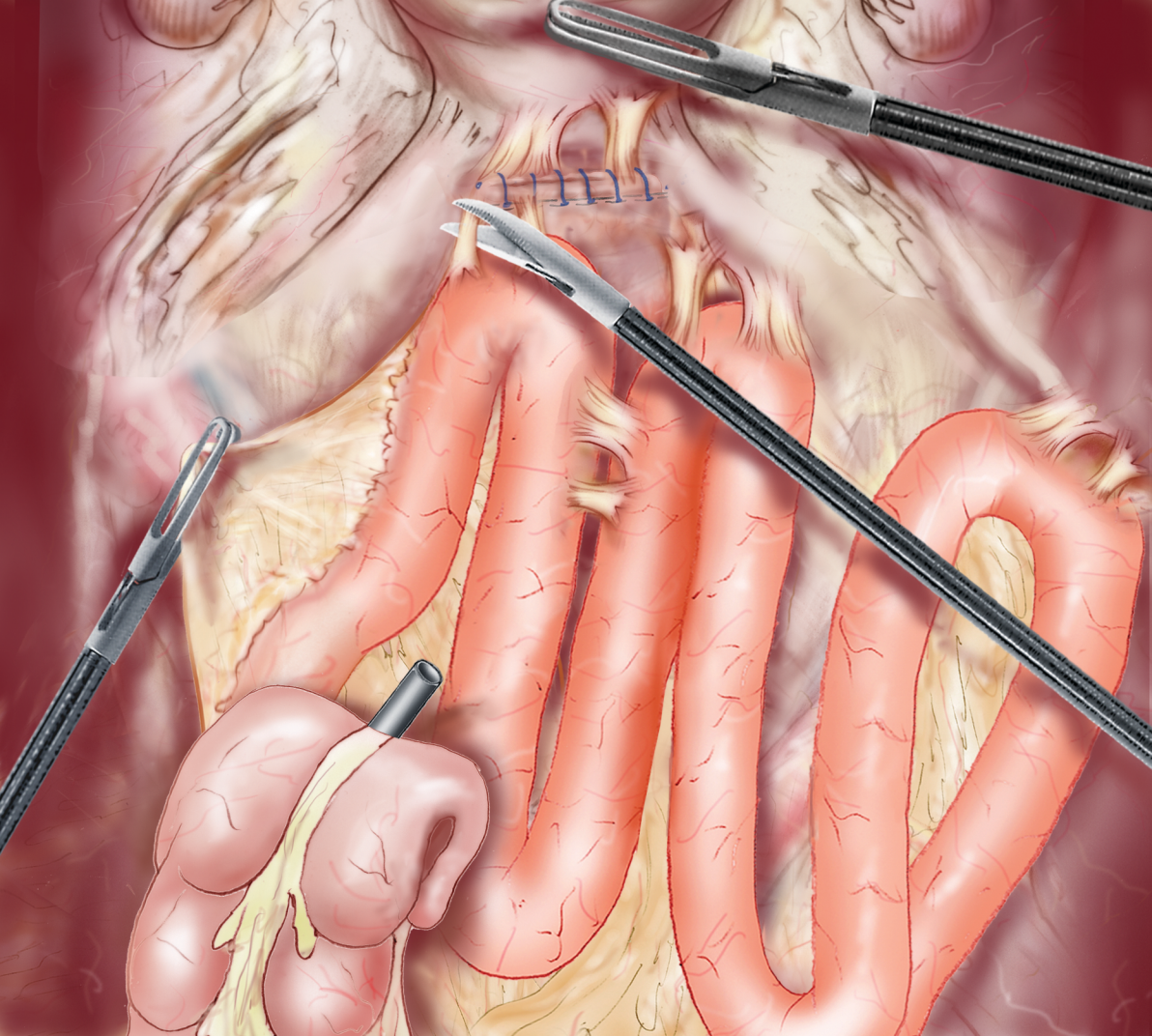


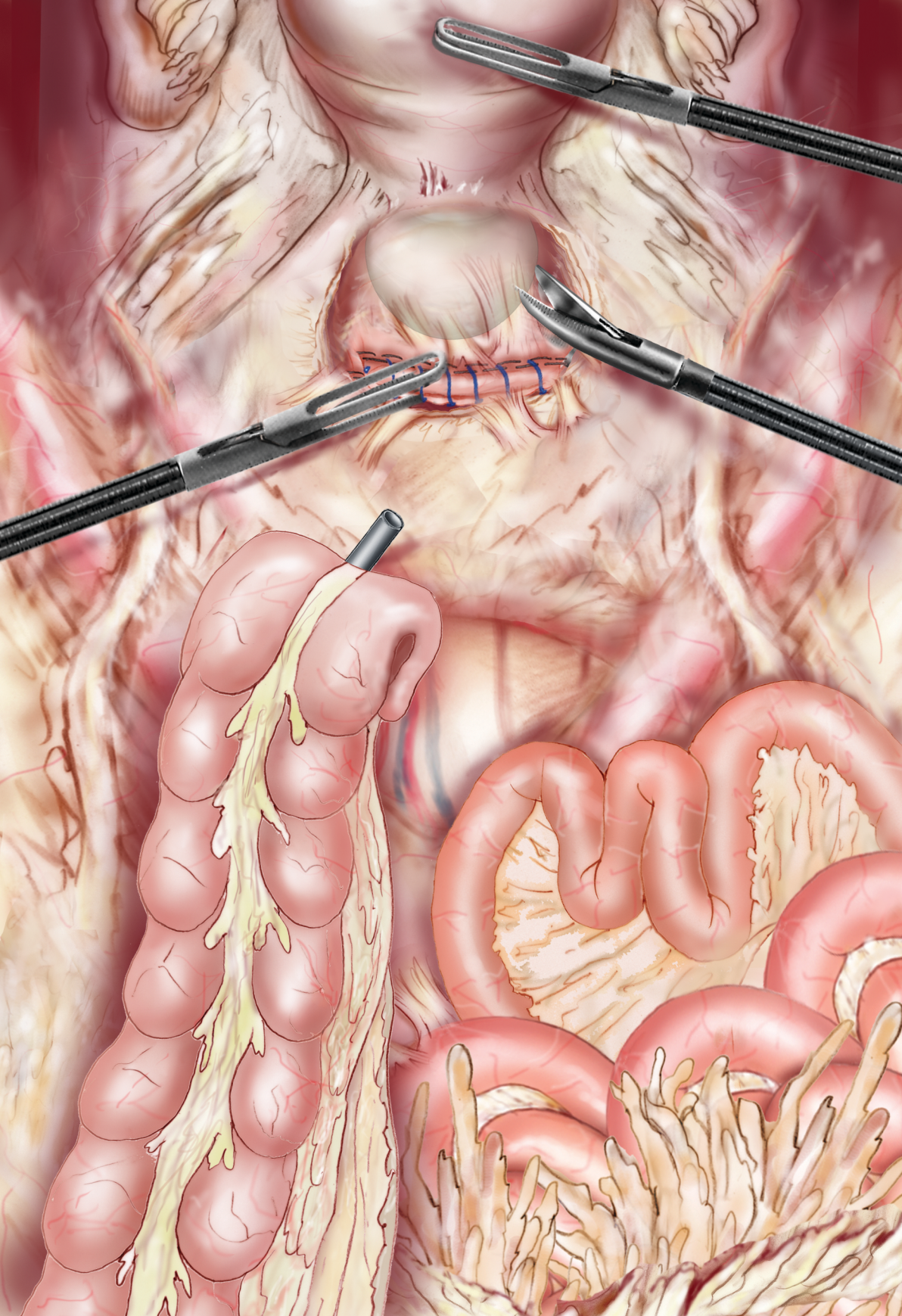
B

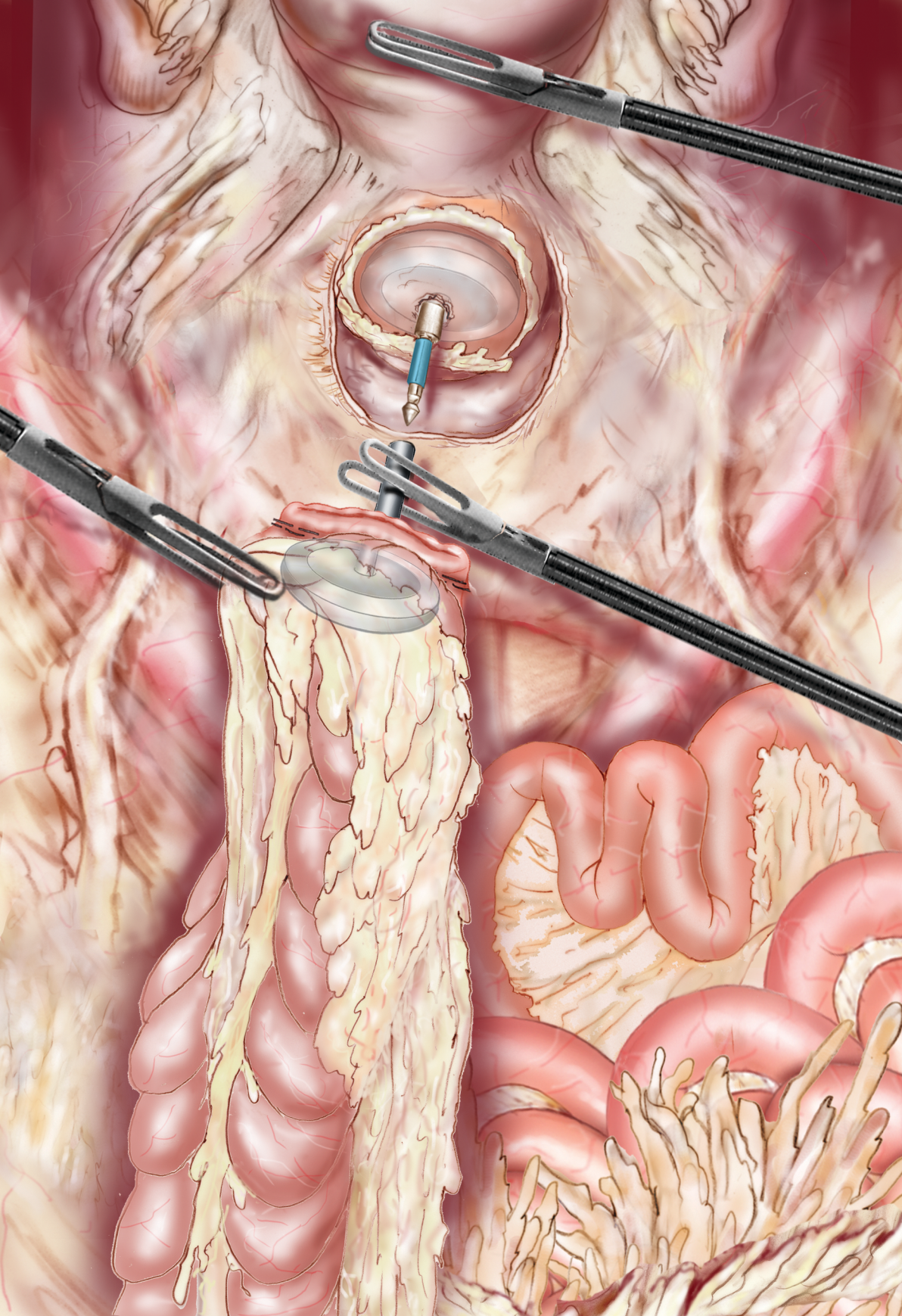












Références :

1. Dumont F, Vibert E, Duval H, Manaouil D, Sredic A, Alfahel N, et al. [Morbi-mortality after Hartmann procedure for peritonitis complicating sigmoid diverticulitis. A retrospective analysis of 85 cases]. *Ann Chir.* août 2005;130:391-9.
2. van de Wall BJM, Draaisma WA, Schouten ES, Broeders IAMJ, Consten ECJ. Conventional and laparoscopic reversal of the Hartmann procedure: a review of literature. *J Gastrointest Surg Off J Soc Surg Aliment Tract.* avr 2010;14:743-52.
3. Celentano V, Giglio MC, Bucci L. Laparoscopic versus open Hartmann's reversal: a systematic review and meta-analysis. *Int J Colorectal Dis.* déc 2015;30:1603-15.
4. De'angelis N, Brunetti F, Memeo R, Batista da Costa J, Schneck AS, Carra MC, et al. Comparison between open and laparoscopic reversal of Hartmann's procedure for diverticulitis. *World J Gastrointest Surg.* 27 août 2013;5:245-51.
5. Gustafsson UO, Scott MJ, Hubner M, Nygren J, Demartines N, Francis N, et al. Guidelines for Perioperative Care in Elective Colorectal Surgery: Enhanced Recovery After Surgery (ERAS®) Society Recommendations: 2018. *World J Surg.* mars 2019;43:659-95.
6. Brac B, Sabbagh C, Regimbeau JM. Colectomie gauche en urgence avec colostomie terminale (intervention de Hartmann). *J Chir Viscérale.* 29 juin 2020