



HAL
open science

Second metatarsal free transfer in total temporomandibular joint reconstruction for ankylosis in a child: 10-year follow-up

Matthieu Olivetto, Jérémie Bettoni, Sylvie Testelin, Stéphanie Dakpé,
Bernard Devauchelle

► To cite this version:

Matthieu Olivetto, Jérémie Bettoni, Sylvie Testelin, Stéphanie Dakpé, Bernard Devauchelle. Second metatarsal free transfer in total temporomandibular joint reconstruction for ankylosis in a child: 10-year follow-up. *International Journal of Oral and Maxillofacial Surgery*, 2021, 50 (5), pp.610-614. 10.1016/j.ijom.2020.07.017 . hal-03598570

HAL Id: hal-03598570

<https://u-picardie.hal.science/hal-03598570>

Submitted on 9 May 2023

HAL is a multi-disciplinary open access archive for the deposit and dissemination of scientific research documents, whether they are published or not. The documents may come from teaching and research institutions in France or abroad, or from public or private research centers.

L'archive ouverte pluridisciplinaire **HAL**, est destinée au dépôt et à la diffusion de documents scientifiques de niveau recherche, publiés ou non, émanant des établissements d'enseignement et de recherche français ou étrangers, des laboratoires publics ou privés.



Distributed under a Creative Commons Attribution - NonCommercial 4.0 International License

Second metatarsal free transfer in total temporomandibular joint reconstruction for ankylosis in a child: 10-year follow-up

Matthieu Olivetto, Jérémie Bettoni, Sylvie Testelin, Stéphanie Dakpé, Bernard Devauchelle

Department of Maxillofacial Surgery, Amiens-Picardy University Medical Centre, Amiens, France

Abstract

The management of temporomandibular joint (TMJ) ankylosis requires complete removal of the ankylosed block and the prevention of recurrence. For this purpose, the ramus–condyle unit can be reconstructed with a second metatarsal free flap. This article reports the use of this flap in a young patient treated for left TMJ ankylosis, post costochondral graft for the treatment of hemifacial microsomia [Au?1]. Data from the 10-year follow-up are reported [Au?1]. The glenoid fossa was reconstructed with a graft of the second metatarsal base, enabling the juxtaposition of two cartilaginous joint surfaces, with the aim of optimizing the functional result and preventing the recurrence of ankylosis. At the 10-year follow-up after this surgery, there was no recurrence of the ankylosis and no articular disorder, and the morphological result was satisfactory. Bone fixation was stable over the 10-year

period and the metatarsal head was still in place. Quantitative measurements obtained by computed tomography scan did not show any growth of the second metatarsal free flap compared to the right unaffected condylar process.

Key words: temporomandibular joint reconstruction, condylar reconstruction, metatarsal free flap, bone free transfer, otomandibular dysplasia

Introduction

The management of temporomandibular joint (TMJ) ankylosis is challenging¹. It involves the complete removal of the ankylosed block. An interpositional gap arthroplasty is required to prevent the recurrence of ankylosis, and this is achieved conventionally with either autologous tissue (temporalis fascia flap, dermal fat graft, fascia lata) or alloplastic materials (silicone)² [Au?1]. The gold standard for restoring the ramus height is an autologous TMJ bone reconstruction [Au?1]. A costochondral graft is often used, but this graft is problematic in terms of growth, long-term stability, and the risk of failure with recurrence of joint ankylosis³ [Au?1]. Other options include distraction osteogenesis, which does not reconstruct the joint surfaces, and total prosthetic joint replacement, for which functional results and long-term stability are controversial⁴.

In 1909, Bardenheuer performed the first autogenous tissue reconstruction of the TMJ in which the mandibular condyle was replaced by the fourth metatarsal⁵. Other uses of an autogenous metatarsal head to reconstruct the mandibular condyle were reported by Dingman and Grabb⁶ in 1964, Glahn and Winther⁷ in 1967, and Spiessl et al.⁸ in 1972 [Au?2]. Entin⁹ used a non-vascularized metatarsophalangeal

joint in 1958. Later, in 2000, Dierks and Buehler¹⁰ reported the use of a non-vascularized metatarsophalangeal joint to reconstruct the TMJ.

The use of a vascularized second metatarsal flap to replace the ankylosed TMJ was proposed in 1985¹¹. Due to its similar shape, the provision of an articular surface, and its long-term stability, it appears to be an attractive option for the reconstruction of the mandibular condyle. However, this method has rarely been used, and the functional quality of the reconstruction has been poorly studied in the long term.

This article reports the case of a complete TMJ reconstruction (condyle and glenoid fossa) with a metatarsal transfer [Au?1]. Similar to the historical articles mentioned above, a metatarsal base bone graft was applied for the reconstruction of the glenoid fossa, associated with a vascularized metatarsal transfer for reconstruction of the condylar process [Au?1].

Case report

A 13-year-old female born with hemifacial microsomia associated with other malformations came for a consultation in 2007, having undergone no previous management. She had complete agenesis of the left TMJ (condyle, ramus, glenoid fossa) with a normal zygomatic arch and without any associated auricular malformation (type II according to the Pruzansky classification)¹².

In 2008, a first mandibular ramus reconstruction was performed using a costochondral graft combined with a serratus free flap to provide mandibular angle volume. A postoperative haematoma caused partial necrosis of the free flap and there was progressive development of TMJ ankylosis with an extensive bone block (type IV

according to the Sawhney classification)¹³ (**Supplementary Material** Fig. S1, ankylotic block).

Surgical management of severe ankylosis ideally requires a total TMJ reconstruction. The second metatarsal free flap technique originally proposed by Ting et al.¹¹ was refined to propose a two-joint surface contact, with reconstruction of the glenoid fossa using the base of the harvested metatarsus as a bone graft.

In 2009, the surgery was done by resection of the ramus and the TMJ ankylosed bone block to create a neocavity [Au?3] similar to the glenoid fossa. A complete reconstruction of the left TMJ with a right second metatarsal free flap was performed.

Harvesting of a second metatarsal flap results in two disarticulations: the metatarsophalangeal joint and the tarsometatarsal joint (see **Supplementary Material** Video S1).

To prevent recurrence and achieve contact between the two articular surfaces, the temporal glenoid fossa was reconstructed. The cartilaginous base of the second metatarsal bone was shaped with a round bur, then rigidly fixed as a graft in the temporal glenoid neocavity [Au?3]. The transplant length was adjusted to the loss of substance to place the metatarsal head 5 mm from the new glenoid. Then, diaphysis osteotomies were performed using tenon–mortise joints [Au?4] to enlarge the contact of the surface with the mandibular angle at which osteosynthesis was achieved with an L-plate (**Supplementary Material** Fig. S2, diagram of the osteotomies). The two cartilaginous surfaces were then covered by the surrounding tissue (deep side of the parenchyma parotidis [Au?5]).

Management of the second ray was conducted by tendinoplasty with phalange preservation and wearing of a postoperative immobilization device, followed by a temporary gait orthosis.

In 2017, bimaxillary orthognathic surgery prepared with orthodontics allowed correction of the occlusal plane by jaw repositioning and mandibular redirection osteotomy. At the same time, an iliac bone graft was used to correct the left angle defect.

The morphological result and facial symmetry at the 10-year follow-up are shown in Fig. 1. There was no recurrence of ankylosis. The patient had no psychosocial difficulties. The changes in magnitude of articular movements are reported in Table 1 [Au?1]. The clinical evaluation found no joint or muscular pain, and no joint cracking or clicking was present on either side. A minimal lateral deviation of the mandible and chin point on the reconstructed side was found on maximum mouth opening. A second toe claw deformity was observed, but this did not affect walking (**Supplementary Material** Fig. S3) [Au?1].

[Table 1 here]

[Figure 1 here]

To evaluate bone development in the second metatarsal flap over time, quantitative measurements were performed with a 10-year CT scan evaluation (three-dimensional reconstruction, shown in Fig. 2). The results were compared with the postoperative CT scan (Table 2). Bone fixation was shown to be stable over time. The metatarsal head position was still aligned with the reconstructed temporal glenoid fossa.

[Figure 2 here]

[Table 2 here]

Discussion

The originality of this case report is the use of the cartilaginous base of the second metatarsal to reconstruct the temporal glenoid fossa and thus juxtapose two cartilaginous surfaces in order to prevent recurrence of the ankylosing process. The metatarsal head was placed to achieve a gap of about 5 mm. This allowed us to consider the restoration of joint mobility in three directions and to reduce the recurrence risk. The stability of bone fixation is an issue because of numerous biomechanical constraints. A tenon–mortise [Au?4] osteosynthesis joint was constructed to optimize surface contact at the mandibular angle. To ensure good articular congruence, harvesting must be conducted on the contralateral foot. If the complete metatarsophalangeal joint is harvested, it has only one direction of movement, which will limit lateral movements; this is in contrast with the TMJ [Au?1]. Therefore, the metatarsal head is disarticulated, allowing the joint cartilage to rest in the glenoid fossa and enabling the joint to move more anatomically.

The long-term bone development of the second metatarsal free flap was followed up in this report. The cortical bone remained thick and without fat involution of the bone marrow. The position of the reconstructed TMJ was satisfactory. Nevertheless, with this patient being at the end of puberty, no longitudinal growth of the free flap was observed. In fact, the measurements obtained showed that the length had decreased by 1.5 mm, probably due to the reshaping of the metatarsal head. The

cortical thickness had reduced by 0.2–0.3 mm in a non-significant manner [Au?1]. Moreover, the diaphyseal width had decreased, in contrast to data reported in the literature for other bone flaps, such as fibula free flaps, because of the lessening of pressure exerted on them¹⁴. Thus, the use of vascularized free bone transfer in children should be favoured at the end of their development in view of the absence of growth of the bone and the possible comorbidities of the donor site (forefoot deformities; postural disorders). In this report, the patient developed a claw toe without any pain or functional issues when walking [Au?1]. This morbidity has to be balanced against the long-term functional benefit of an autologous TMJ reconstruction. As the lengthening tendinoplasty performed was insufficient to prevent the effects of tendon retraction, a possible improvement for the management of the donor site could include an initial section of the phalangeal flexor and extensor tendons.

There is still no consensus on the most effective therapeutic strategy for the management of TMJ ankylosis^{4,15–17}. The treatment goal is to restore the range of mobility of the joint and maintain a stable dental occlusion, as well as to prevent the recurrence of ankylosis. Currently, no surgical technique is characterized by a satisfactory and consistent success rate¹. The main complication is recurrence of ankylosis, which often occurs within 6 months of surgery. Extensive osteoarticular resection is therefore necessary to prevent recurrence of the ankylosing process¹⁸. If the resulting gap is too narrow (<1 cm), it may lead to new adhesions and recurrence of ankylosis. However, if the gap is too wide (1.5–2.5 cm), it may reduce the ramus height and lead to lateral mandibular deviation. Intensive postoperative physiotherapy helps prevent adhesions, but initiation should be delayed for a few days until the pain and risk of haematoma formation have diminished.

If the bone resection is extensive, joint reconstruction is performed with autogenous bone grafts, distraction osteogenesis, or alloplastic TMJ prostheses. Distraction osteogenesis techniques cannot reconstruct the joint. Additionally, the very long-term stability of alloplastic TMJ prostheses used in adolescents and young adults has not been demonstrated. The main disadvantages of the bone grafting technique are the rapid rate of resorption and degenerative remodelling. This is exacerbated when the receiving bed has been disrupted by previous surgical procedures, making the long-term results of subsequent condylar reconstruction unpredictable. TMJ reconstruction with a second metatarsal free flap provides better long-term stability. The bone provided by the graft CT scan secondary adjustments to be made, such as bilateral sagittal split osteotomy in which the flap can be repositioned as a native condyle, in a situation where a prosthesis, for example, would have been less adaptive [Au?6].

In conclusion, the second metatarsal free flap for ramus–condyle unit reconstruction associated with an original metatarsal base bone graft for glenoid fossa reconstruction, is a useful therapeutic option for complete TMJ reconstruction in cases requiring the management of ankylosis. This technique, despite its complexity, provides biological tissue that is more suitable than a prosthesis for adolescents and young adults. The functional results are satisfactory and stable over time. This could be a salvage surgery solution after removal of a TMJ prosthesis. In this case report of an adolescent female, the lack of growth of the free bone flap could be a significant factor that has not yet been studied extensively.

Funding

No funding source.

Competing interests

No competing interests.

Ethical approval

No ethical approval was required for this retrospective case report [Au?1].

Patient consent

Written patient consent was obtained.

References

1. Allori AC, Chang CC, Farina R, et al. [Au?7] Current concepts in pediatric temporomandibular joint disorders part I. *Plast Reconstr Surg* 2010; 126: 1263–1275.
2. Gupta S, Gupta H, Mohammad S, et al. [Au?7] Silicone vs temporalis fascia interposition in TMJ ankylosis: a comparison. *J Oral Biol Craniofac Res* 2016; 6: 107–110.
3. Perrott DH, Umeda H, Kaban LB. Costochondral graft construction/reconstruction of the ramus/condyle unit: long term follow-up. *Int J Oral Maxillofac Surg* 1994; 23: 321–328.
4. Mittal N, Goyal M, Sardana D, Dua JS. Outcomes of surgical management of TMJ ankylosis: a systematic review and meta-analysis. *J Craniomaxillofac Surg* 2019; 47: 1120–1133. doi: 10.1016/j.jcms.2019.03.029
5. Lexer E. Joint transplantations and arthroplasty. *Surg Gynecol Obstet* 1925; 40: 782–809.

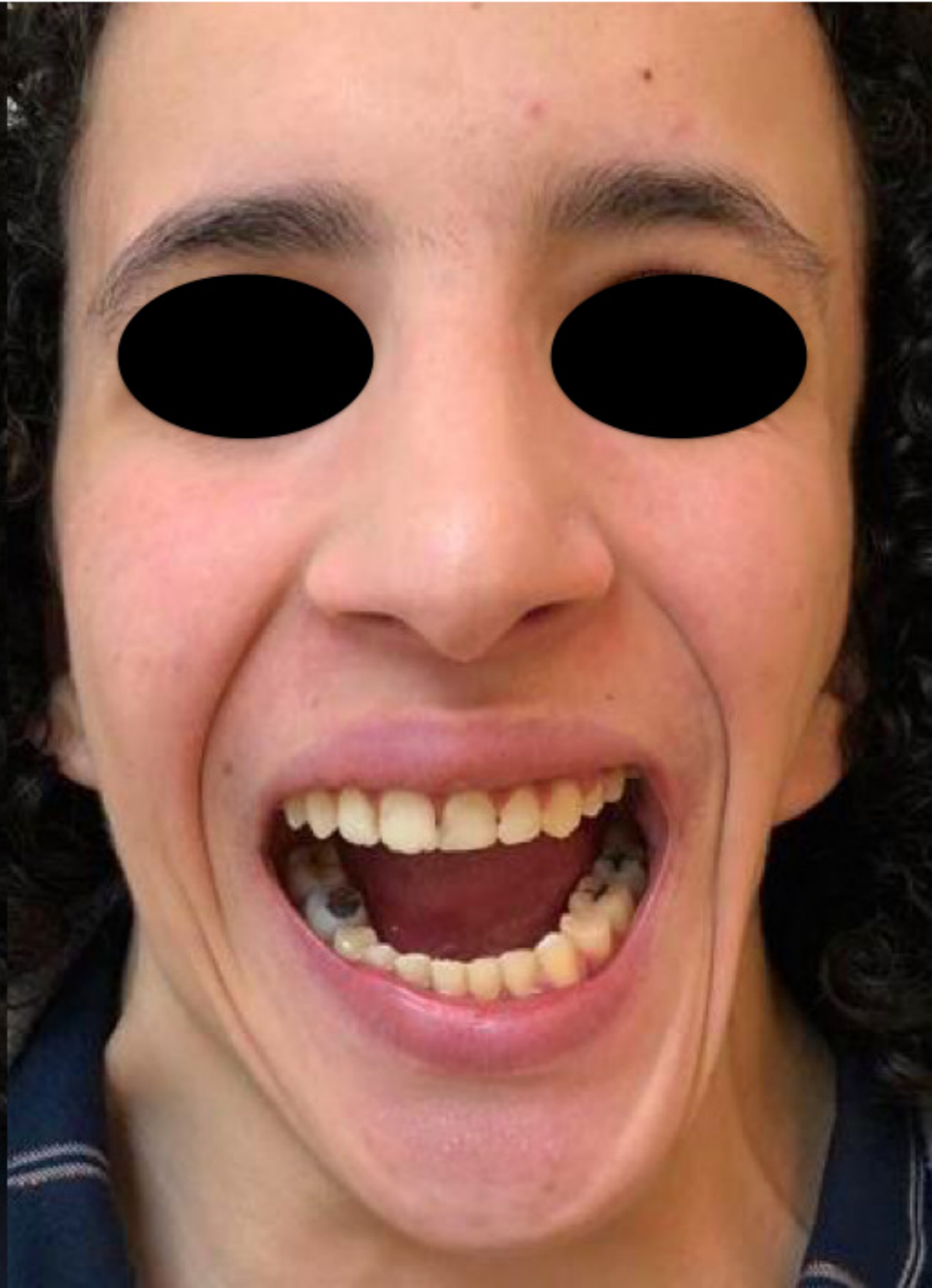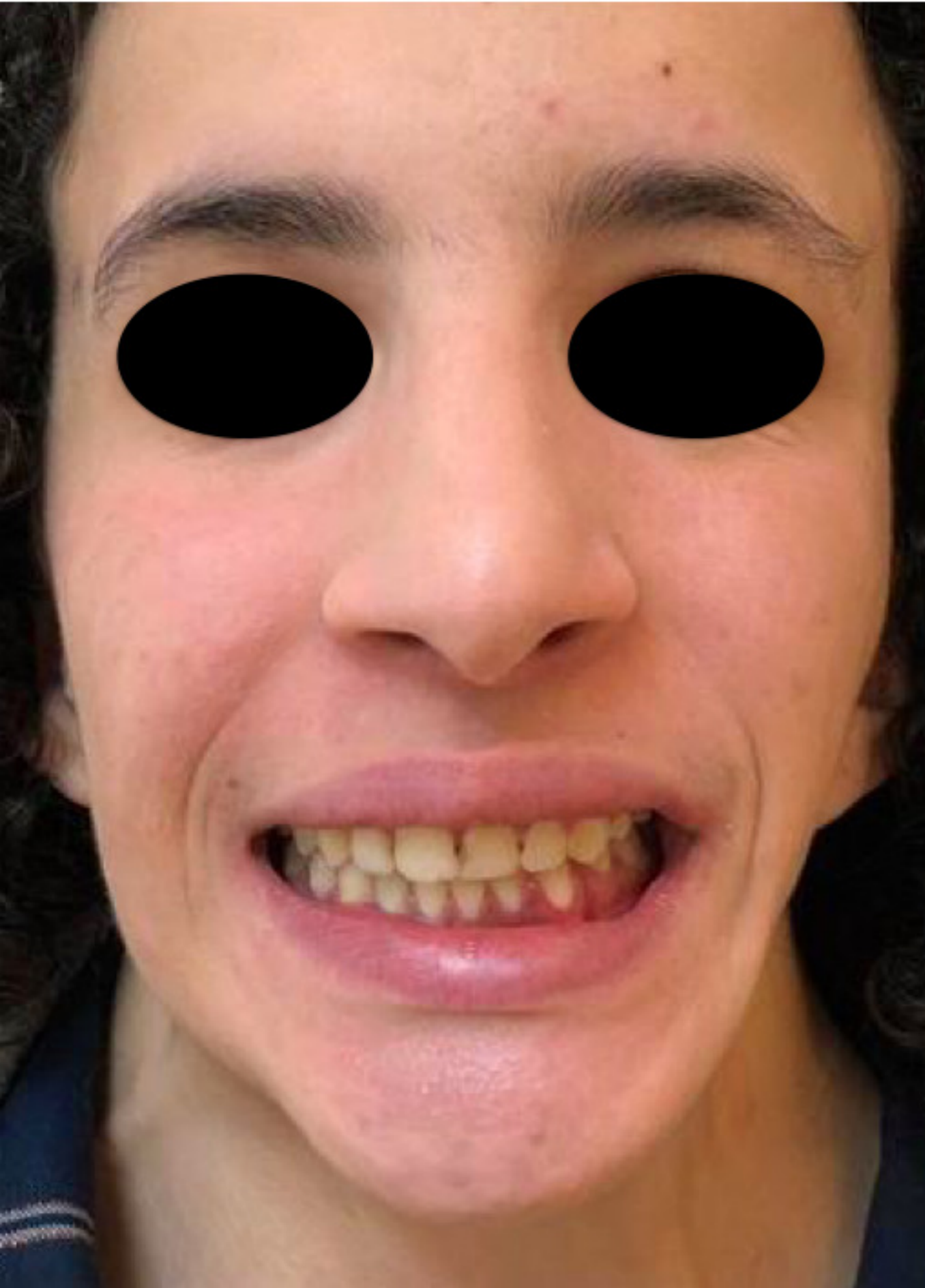6. Dingman RO, Grabb WC. Reconstruction of both mandibular condyles with metatarsal bone grafts. *Plast Reconstr Surg* 1964; 34: 441–445.
7. Glahn MT, Winther JE. Metatarsal transplants for the lost mandibular condyle (3 years' follow-up). *Scand J Plast Reconstr Surg* 1967; 1: 97–100.
8. Spissel B [Au?2], Morscher E, et al. [Au?7] Transplantation of the proximal phalanx of the second toe as a substitute for the temporomandibular joint in cases of ankylosis. In: [Au?8], eds.: *Proceedings of the First International Symposium on Aesthetic Surgery*. Vol. 1. New York: Grune and Stratton, 1972: 217.
9. Entin MA. Reconstruction in congenital deformity of the temporomandibular joint component. *Plast Reconstr Surg* 1958; 21: 461–469.
10. Dierks EJ, Buehler MJ. Complete replacement of the temporomandibular joint with a microvascular transfer of the second metatarsal-phalangeal joint. In: Donlon WC, ed.: *Oral and maxillofacial surgery clinics of North America. Total temporomandibular joint reconstruction*. Philadelphia: Saunders, 2000: 12: 133–137.
11. Ting ZS, Chang TS, Wang TC, Wang W, Feng SZ. Vascular metatarsophalangeal to ankylosed temporomandibular joint replacement. *Ann Plast Surg* 1985; 15: 497–500.
12. Pruzansky S. Not all dwarfed mandibles are alike. *Birth Defects* 1969; 1: 120–129.
13. Sawhney CP. Bony ankylosis of the temporomandibular joint: follow up of 70 patients treated with arthroplasty and acrylic spacer interposition. *Plast Reconstr Surg* 1986; 77: 29–40.
14. Devauchelle BL, Testelin SR, Davrou J, Neiva C, Lengele BG, Dubernard JM, Dakpe S. Face graft? Extrapolation of facial allotransplantation to children. *J Craniomaxillofac Surg* 2016; 44: 925–933. doi: 10.1016/j.jcms.2016.03.006

15. Al-Moraissi EA, El-Sharkawy TM, Mounair RM, El-Ghareeb TI. A systematic review and meta-analysis of the clinical outcomes for various surgical modalities in the management of temporomandibular joint ankylosis. *Int J Oral Maxillofac Surg* 2015; 44: 470–482.
16. Movahed R, Mercuri LG. Management of temporomandibular joint ankylosis. *Oral Maxillofac Surg Clin North Am* 2015; 27: 27–35.
17. Wolford L, Movahed R, Teschke M, Fimmers R, Havard D, Schneiderman E. Temporomandibular joint ankylosis can be successfully treated with TMJ Concepts patient-fitted total joint prosthesis and autogenous fat grafts. *J Oral Maxillofac Surg* 2016; 74: 1215–1227.
18. Hegab AF. Pathogenic TMJ ankylosis and re-ankylosis. *J Oral Maxillofac Surg* 2015: [Au?9].

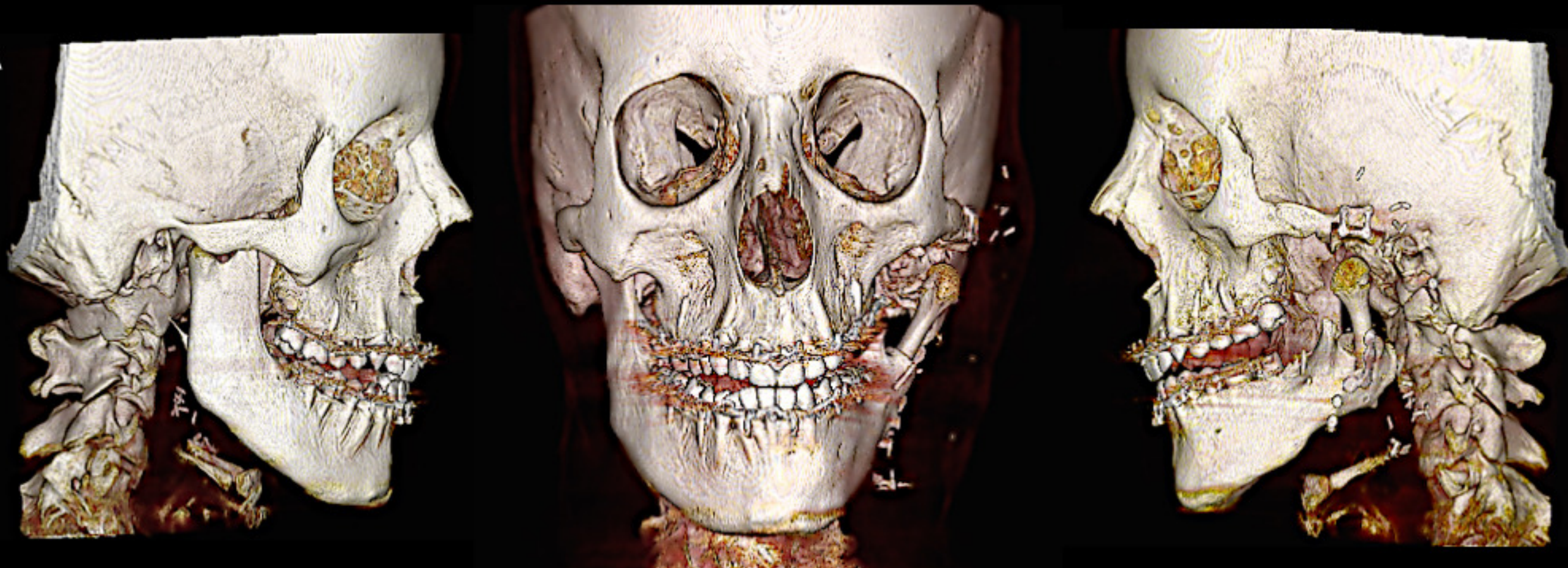Figure captions

Fig. 1. Clinical photographs taken at 10 years postoperative, showing facial symmetry, the dental occlusion, and mouth opening.

Fig. 2. 3D-CT scans of the free transfer obtained (A) immediately postoperative, and (B) at 10 years postoperative, showing the reconstructed condylar process (second metatarsal head into the glenoid fossa (base of the second metatarsal)).



A



B

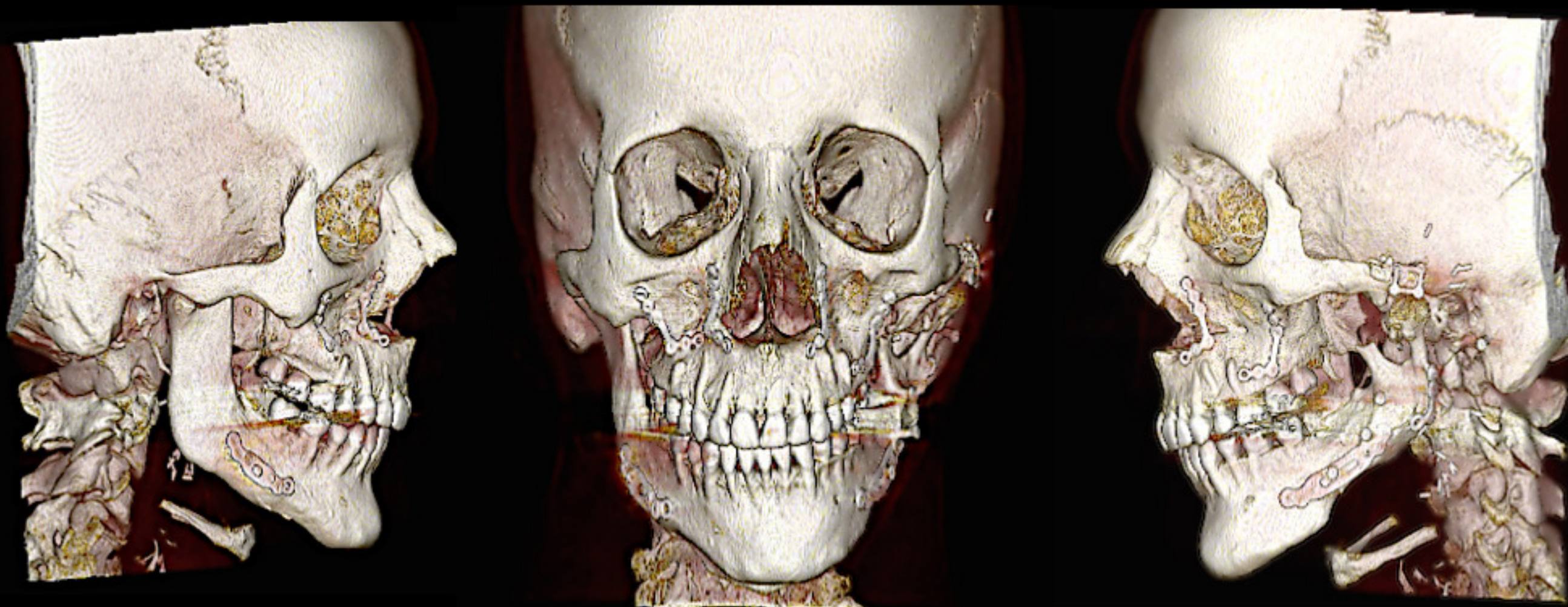


Table 1. Measurements of the magnitude of joint movements at 1 month and 10 years postoperative. [Au?1]

Clinical examination measurements	Postoperative	10-year follow-up
Mouth opening (mm)	32	38
Left side diduction (mm)	3	5
[Au?10]		
Right side diduction (mm)	6	8
[Au?10]		
Propulsion (mm) [Au?11]	3	4

Table 2. Quantitative measurements on CT scans.

Quantitative measurements	Postoperative		10-year follow-up	
	Second metatarsal free transfer side	Contralateral unaffected side	Second metatarsal free transfer side	Contralateral unaffected side
		[Au?12]		[Au?12]
Condylion–gonion height (mm)	53	53	47	58
Total height of the second metatarsal flap (mm)	36.3	-	34.8	-
Thickness of the internal cortical bone (mm)	2.1	2.1	1.9	2.0
Thickness of the external cortical bone (mm)	2.2	2.1	1.9	2.4
Minimum diaphysis width (mm)	7.0	4.5	4.5	5.1

CT, computed tomography.