HAL open science

Asymptomatic palatine swelling with rapid worsening of young children

Julien Bouquet, Jérémie Bettoni, Stéphanie Dakpé, Sylvie Testelin

To cite this version:

Julien Bouquet, Jérémie Bettoni, Stéphanie Dakpé, Sylvie Testelin. Asymptomatic palatine swelling with rapid worsening of young children. Journal of Stomatology, Oral and Maxillofacial Surgery, 2021, 122 (3), pp.325-326. 10.1016/j.jormas.2020.09.010 . hal-03598626

HAL Id: hal-03598626

https://u-picardie.hal.science/hal-03598626v1

Submitted on 24 May 2023

HAL is a multi-disciplinary open access archive for the deposit and dissemination of scientific research documents, whether they are published or not. The documents may come from teaching and research institutions in France or abroad, or from public or private research centers.

L'archive ouverte pluridisciplinaire **HAL**, est destinée au dépôt et à la diffusion de documents scientifiques de niveau recherche, publiés ou non, émanant des établissements d'enseignement et de recherche français ou étrangers, des laboratoires publics ou privés.

Distributed under a Creative Commons Attribution - NonCommercial 4.0 International License

Version of Record: https://www.sciencedirect.com/science/article/pii/S2468785520302226
Manuscript_0766b070f99caffe7bef0d155481217c

Title

Asymptomatic palatine swelling with rapid worsening of young children

Authors:

Julien BOUQUET, M.D.1 ; Jeremie BETTONI, M.D.1 ; Stephanie DAKPE, M.D.-Ph.D.1 Sylvie TESTELIN, M.D.-Ph.D.1

1-Maxillo-facial surgery department, Amiens-Picardie University Hospital, avenue Laennec, 80000 Amiens, France.

Corresponding author :

BOUQUET Julien

Maxillo-facial surgery department,

Amiens-Picardie University Hospital,

Avenue Laennec, 80000 Amiens, France

Julienbouquet2@hotmail.com

© 2020 published by Elsevier. This manuscript is made available under the CC BY NC user license
https://creativecommons.org/licenses/by-nc/4.0/

Manuscript

Observation

A 2-year-old child without a medical history is referred to the paediatric emergency department for advice regarding the aggravation of a right palatal swelling that appeared 3 days earlier. In his letter, the attending physician reports the notion of a suspicion of a primary varicella-zoster-virus infection dating back a week with the initiation of a probabilistic antibiotic therapy with amoxicillin-clavulanic acid (1 dose weight*3 per day) 72 hours ago, when this palatal mass was discovered, suggesting serous dental cellulitis.

Clinically, the child presents a well-limited, painless right palatal mass that slightly crosses the midline and respecting the palatal veil. This tumour is indurated, non-renitent and non-inflammatory (Fig. 1). It presents no dietary difficulties but appears very tired. No dental mobility or pain on percussion or cold test is found.

In view of the atypical history of the disease and the prospect of an injected imaging exam to complete your observation, you decide to carry out a biological assessment (blood count, CRP, kidney function, coagulation test). 30 minutes later, the biologist who wishes to personally give you the results calls you urgently. The child presents anemia at 7.1 g/dl (11<N<14), thrombocytopenia at 22,000 per mm3 (200<N<490), hyperleukocytosis at 76,000 per mm3 (5,000<N<15,000) with a blood smear reporting 48% myeloid blasts.

What is your diagnosis ?

Response

It is a Myeloid Sarcoma (MS) of the right maxilla (= solid tumour with extra-myeloid cells), which in this observation is expressed in the context of acute myeloblastic leukemia with non-hyper-leukocyte t(8;21) translocation.

Discussion

Myeloid sarcoma (MS) is a rare, localized tumour comprising immature granulocytic cells. It is also called Chloroma because of its green colour induced by the concentration of myeloperoxidase[1]. It may occur in pre-existing acute myeloid leukaemia (AML) (3-8%), before the onset of AML (0.6%) or in association with other myelo-proliferative conditions such as blast crisis in chronic myeloid leukaemia and myelodysplastic Syndrome[2,3]. MS is primarily of soft tissue interest and remains extremely rare in the head and neck area[4]. Nevertheless, its knowledge is essential as it represents a real diagnostic and therapeutic emergency.
Confirmation of the diagnosis of MS is based on the performance of flow cytometer of circulating blood and bone marrow, a myelogram, biopsy of the lesion and genetic research since many mutations may be involved. Rapid determination of the phenotype is crucial in order to best adapt the treatment protocol. The assessment must be completed by an imaging examination (CT scan and/or magnetic resonance

imaging with injection of contrast agent) before the introduction of any therapy[2,5]. These examinations will allow the assessment of tumour anatomic ratios and will serve as reference examinations for the evaluation of the efficacy of systemic treatments. Indeed, the prognosis of MS depends essentially on the initial context in which it is diagnosed (age, presence or not of AML)[5]. MS management is based on the rapid introduction of systemic chemotherapy, surgery being only a catch-up solution in case of persistent tumour remnants at the end of treatment.

Keywords : Myeloid sarcoma, Chloroma, Acute Myeloid Leukaemia ; Extramedullary ; Oral tumors.

Conflict of Interest Statement: None

References

[1] Ficarra G, Silverman S, Quivey JM, Hansen LS, Giannotti K. Granulocytic sarcoma (chloroma) of the oral cavity: A case with aleukemic presentation. Oral Surgery, Oral Medicine, Oral Pathology 1987;63:709–14. https://doi.org/10.1016/0030-4220(87)90375-6.

[2] Siraj F, Kaur M, Dalal V, Khanna A, Khan AA. Myeloid sarcoma: a report of four cases at unusual sites. Ger Med Sci 2017;15. https://doi.org/10.3205/000244.

[3] Roby BB, Drehner D, Sidman JD. Granulocytic sarcoma of pediatric head and neck: An institutional experience. International Journal of Pediatric Otorhinolaryngology 2013;77:1364–6. https://doi.org/10.1016/j.ijporl.2013.06.008.

[4] Papamanthos MK, Kolokotronis AE, Skulakis HE, Fericean A-MA, Zorba MT, Matiakis AT. Acute Myeloid Leukaemia Diagnosed by Intra-Oral Myeloid Sarcoma. A Case Report. Head Neck Pathol 2010;4:132–5. https://doi.org/10.1007/s12105-010-0163-9.

[5] Avni B, Koren-Michowitz M. Myeloid Sarcoma: Current Approach and Therapeutic Options. Ther Adv Hematol 2011;2:309–16. https://doi.org/10.1177/2040620711410774.

Captions to illustrations

Figure 1 : Clinical view of the palatine swelling
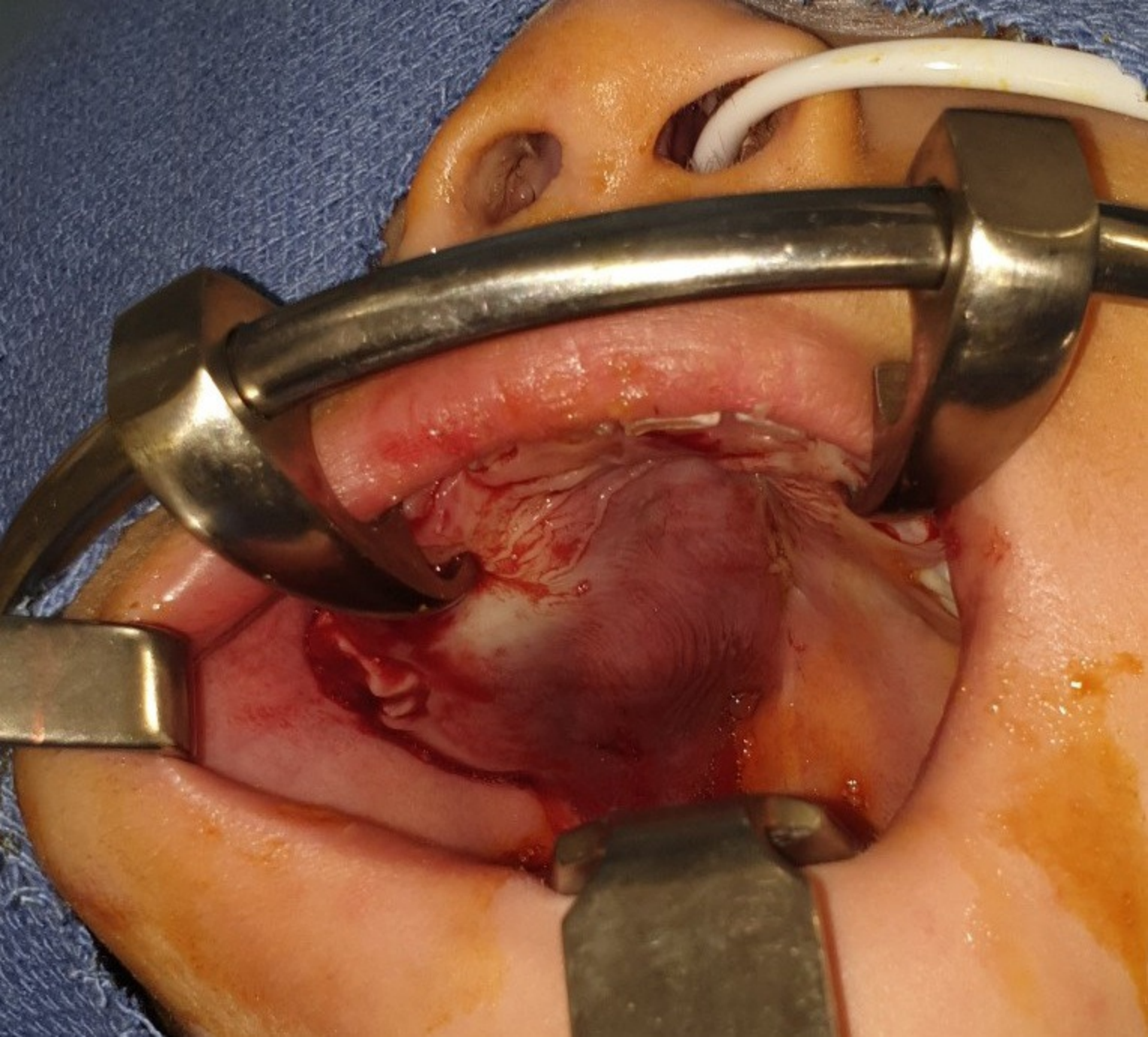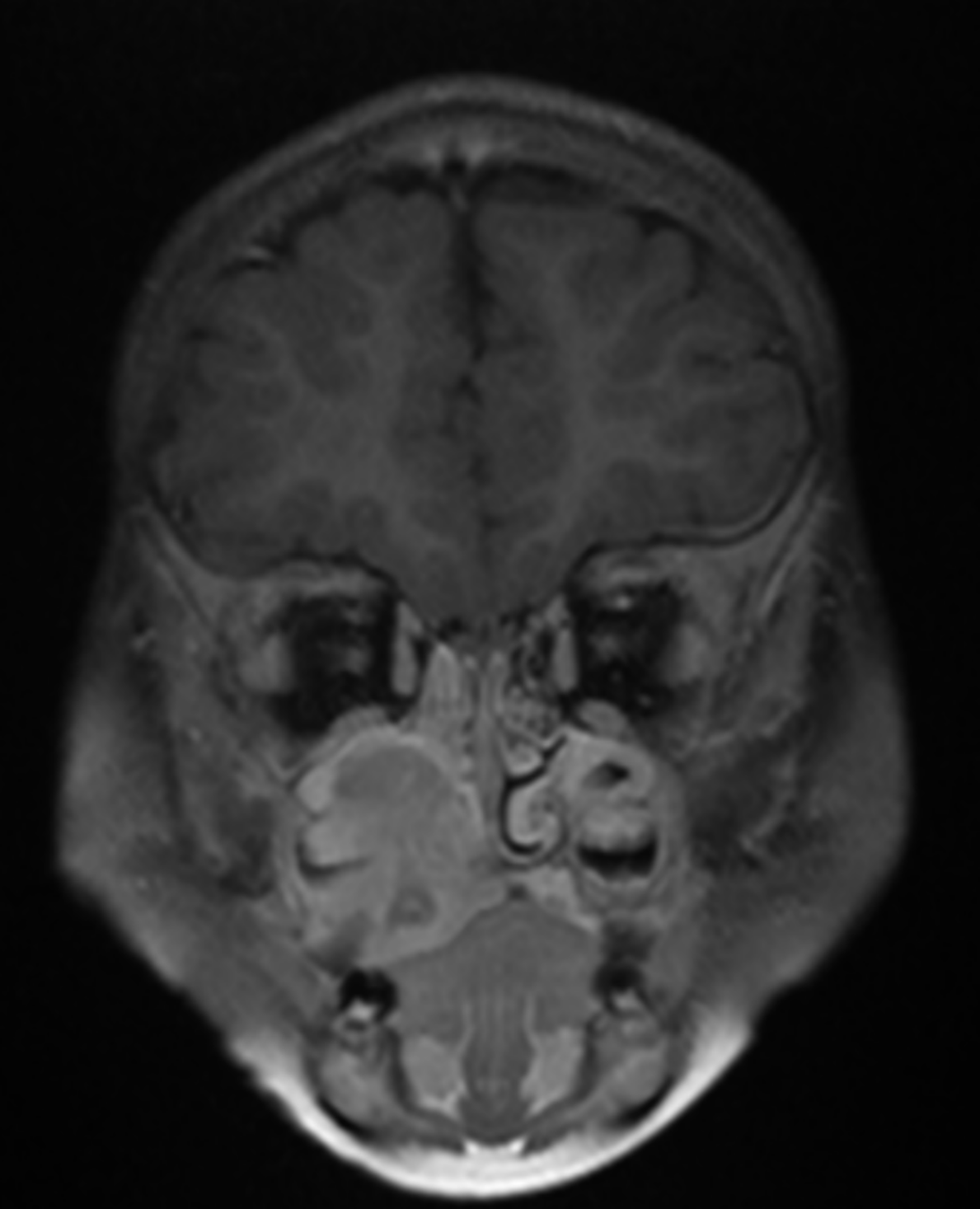
Figure 2 : Coronal T1 with gadolinium MRI acquisition showing the palatine mass of 32mm diameter whithout mass effect.