



HAL
open science

Recommendations for postoperative radiotherapy in head & neck squamous cell carcinoma in the presence of flaps: A GORTEC internationally-reviewed HNCIG-endorsed consensus

Florent Carsuzaa, Michel Lapeyre, Vincent Gregoire, Philippe Maingon, Arnaud Beddok, Pierre-Yves Marcy, Julia Salleron, Alexandre Coutte, Severine Racadot, Yoann Pointreau, et al.

► To cite this version:

Florent Carsuzaa, Michel Lapeyre, Vincent Gregoire, Philippe Maingon, Arnaud Beddok, et al.. Recommendations for postoperative radiotherapy in head & neck squamous cell carcinoma in the presence of flaps: A GORTEC internationally-reviewed HNCIG-endorsed consensus. *Radiotherapy & Oncology*, 2021, 160, pp.140-147. 10.1016/j.radonc.2021.04.026 . hal-03600466

HAL Id: hal-03600466

<https://u-picardie.hal.science/hal-03600466v1>

Submitted on 24 May 2023

HAL is a multi-disciplinary open access archive for the deposit and dissemination of scientific research documents, whether they are published or not. The documents may come from teaching and research institutions in France or abroad, or from public or private research centers.

L'archive ouverte pluridisciplinaire **HAL**, est destinée au dépôt et à la diffusion de documents scientifiques de niveau recherche, publiés ou non, émanant des établissements d'enseignement et de recherche français ou étrangers, des laboratoires publics ou privés.



Distributed under a Creative Commons Attribution - NonCommercial 4.0 International License

Title page: **Recommendations for postoperative radiotherapy in head & neck squamous cell carcinoma in the presence of flaps: a GORTEC internationally-reviewed HNCIG-endorsed consensus**

Running title: **Recommendations for postoperative radiotherapy in head & neck squamous cell carcinoma in the presence of flaps**

Florent Carsuzaa¹, Michel Lapeyre², Vincent Gregoire³, Philippe Maingon⁴, Arnaud Beddok⁵, Pierre-Yves Marcy⁶, Julia Salleron⁷, Alexandre Coutte⁸, Severine Racadot³, Yoann Pointreau⁹, Pierre Graff¹⁰, Beth Beadle¹¹, Karen Benezery¹², Julian Biau², Valentin Calugaru⁵, Joel Castelli¹³, Melvin Chua¹⁴, Alessia Di Rito¹⁵, Melanie Dore¹⁶, Pirus Ghadjar¹⁷, Florence Huguet¹⁸, Pauline Jardel¹⁹, Jorgen Johansen²⁰, Randall Kimple²¹, Marco Krenegli²², Sarbani Laskar²³, Lachlan Mcdowell²⁴, Anthony Nichols²⁵, Silke tribius²⁶, Izaskun Valduvico²⁷, Chaosu Hu²⁸, Xavier Liem²⁹, Antoine Moya-Plana³⁰, Ida D'onofrio³¹, Upendra Parvathanen³², Vinita Takiar³³, Ester Orlandi³⁴, Amanda Psyrris³⁵, George Shenouda³⁶, David Sher³⁷, Conor Steuer³⁸, Xu Shan Sun³⁹, Yungan Tao³⁰, David Thomson⁴⁰, Mu-Hung Tsai⁴¹, Noemie Vulquin⁴², Philippe Gorphe³⁰, Hisham Mehanna⁴³, Sue S. Yom⁴⁴, Jean Bourhis⁴⁵, Juliette Thariat⁴⁶

1 Department of Head and Neck Surgery, CHU de Poitiers, France.

2 Department of Radiation oncology, Centre Jean Perrin – Clermont-Ferrand, France.

3 Department of Radiation oncology, Centre Léon Bérard, Lyon, France.

4 Department of Radiation Oncology, Hôpital de la Pitié-Salpêtrière, Paris, France.

5 Department of Radiation Oncology, Institut Curie, Paris, France

6 Department of Radiology, Clinique du Cap d'Or, La Seyne-sur-mer, France.

7 Department of Biostatistics, Institut de cancérologie de Lorraine, France

8 Department of Radiation Oncology, Amiens Picardie University Medical Center, Amiens, France

9 Department of Radiation Oncology, Centre Jean Bernard, Le Mans, France.

10 Department or Radiation Oncology, Institut C. Regaud, Toulouse, France.

11 Department of Radiation Oncology, Stanford University Medical Center, CA, USA. Stanford University Medical Center

12 Department of Radiation Oncology, Centre Antoine Lacassagne, Nice, France.

13 Department of Radiation Oncology, Centre Eugène Marquis, Rennes, France.

14 Division of Radiation Oncology, National Cancer Centre Singapore; Duke-NUS Medical School, Singapore.

15 Department of Radiation Oncology, OC Radioterapia Ospedale "Mons. A.R. Dimiccoli" di Barletta, Rome, Italy

16 Department of Radiation Oncology, Institut de cancérologie de l'Ouest, St Herblain, France.

17 Department of Radiation Oncology, Charité, Berlin, Germany.

18 Department of Radiation Oncology, Hospital de Tenon, Paris, France.

19 Department of Radiation Oncology, CHU de la Milétrie, Poitiers, France.

20 Department of Radiation Oncology, Odense University Hospital, Denmark.

- 21 Department of Medical Oncology, University of Wisconsin-Madison, WI, USA.
- 22 Department of Translational Medicine University of Piemonte Orientale, Novara, Italy
- 23 Department of Radiation Oncology, TATA, Mumbai, India.
- 24 Department of Radiation Oncology, Peter McCallum Cancer Center, Melbourne, Australia.
- 25 Department of Head and Neck surgery, London Health Sciences Center, Ontario, Canada.
- 26 Department of Radiation Oncology, Hermann-Holthusen-Institute for Radiation Oncology, Asklepios Hospital St. Georg, Hamburg, Germany.
- 27 Department of Radiation Oncology, Hospital clinic, Barcelona, Spain.
- 28 Department of Radiation Oncology, Fundan University, Shanghai, China.
- 29 Department of Radiation Oncology, Centre Oscar Lambret, Lille.
- 30 Department of Head and Neck Surgery, Gustave Roussy, Villejuif, France.
- 31 Department of Radiation Oncology, Hospital Naples, Italy.
- 32 Department of Radiation Oncology, University of Washington, DC, USA.
- 33 Department of Radiation Oncology, University of Cincinnati, Ohio, USA.
- 34 Department of Radiation Oncology, CNAO, Milan, Italy.
- 35 Department of Medical Oncology, Attikon University Hospital, Athens, Greece.
- 36 Department of Radiation Oncology, McGill University Health Centre, Montreal, Quebec.
- 37 Department of Radiation Oncology, UT Southwestern, Dallas, USA.
- 38 Department of Head and Neck Surgery, Winship Cancer Institute, Atlanta, USA.
- 39 Department of Radiation Oncology, Centre Hospitalier André Bouloche, Montbéliard, France.
- 40 Department of Radiation Oncology, The Christie NHS Foundation Trust, Manchester, UK.
- 41 Department of Radiation Oncology, National Cheng Kung University Hospital, Tainan, Taiwan.
- 42 Department of Radiation Oncology, Centre Georges François Leclerc, Dijon, France.
- 43 Department of Radiation Oncology, Institute for Global Innovation, Birmingham, UK.
- 44 Department of Radiation Oncology, NRG Oncology Cancer Research Group, California, USA.
- 45 Department of Radiation Oncology, UNIL-CHUV, Lausanne, Suisse.
- 46 Department of Radiation Oncology, Centre François-Baclesse, Caen, France.

Disclosures : None

Funding : None

Conflict of Interest : None

Authors' contributions : each author has contributed significantly (FC, ML, VG, AB, PYM, AC, SR, JB, JT designed the questions, JS did the statistics, others quoted the proposals, either once (independent international review group) or twice (GORTEC quotation group), all reviewed the final ms) to the manuscript.

Address for reprints / to corresponding author: Juliette Thariat / email : jthariat@gmail.com

Centre François-Baclesse, département de radiothérapie, 3, avenue Général-Harris, 14000 Caen, France ; Laboratoire de physique corpusculaire IN2P3/ENSICAEN - UMR6534, boulevard du Marechal-Juin, 14050 Caen, France.

Corresponding author : Pr Juliette Thariat / email : jthariat@gmail.com

Responsible statistical analysis author : Julia Salleron / email :
j.salleron@nancy.unicancer.fr

1 **Abstract**

2 Introduction: Head and neck reconstructive surgery using a flap is increasingly common. Best
3 practices and outcomes for postoperative radiotherapy (poRT) with flaps have not been
4 specified. We aimed to provide consensus recommendations to assist clinical decision-
5 making highlighting areas of uncertainty in the presence of flaps.

6 Material and methods: Radiation, medical, and surgical oncologists were assembled from
7 GORTEC and internationally with the Head and Neck Cancer International Group (HNCIG).
8 The consensus-building approach covered 59 topics across four domains: 1) identification of
9 postoperative tissue changes on imaging for flap delineation, 2) understanding of tumor
10 relapse risks and target volume definitions, 3) functional radiation-induced deterioration, 4)
11 feasibility of flap avoidance.

12 Results: Across the 4 domains, international consensus (median score $\geq 7/9$) was achieved
13 only for functional deterioration (73.3%); other consensus rates were 55.6% for poRT
14 avoidance of flap structures, 41.2% for flap definition and 11.1% for tumor spread patterns.
15 Radiation-induced flap fibrosis or atrophy and their functional impact was well recognized
16 while flap necrosis was not, suggesting dose-volume adaptation for the former. Flap
17 avoidance was recommended to minimize bone flap osteoradionecrosis but not soft-tissue
18 toxicity. The need for identification (CT planning, fiducials, accurate operative report) and
19 targeting of the junction area at risk between native tissues and flap was well recognized.
20 Experts variably considered flaps as prone to tumor dissemination or not. Discrepancies in
21 rating of 11 items among international reviewing participants are shown.

22 Conclusion: International GORTEC and HNCIG-endorsed recommendations were generated
23 for the management of flaps in head and neck radiotherapy. Considerable knowledge gaps
24 hinder further consensus, in particular with respect to tumor spread patterns.

25 Key words: head and neck, cancer, radiotherapy, postoperative, reconstructive surgery, flap,
26 consensus / recommendation

27 **Introduction**

28 For large head and neck tumors, reconstructive surgery is frequently performed using an
29 autologous flap, harvested from the patient donor site and transferred to the tumor bed to
30 compensate for the loss of substance [1–4]. Increasingly versatile flaps have aimed to
31 achieve high fidelity to the native tissues to improve functional outcomes and quality of life
32 [5].

33 Target volumes have been extensively defined and evaluated for patients undergoing
34 definitive primary radiotherapy [6]. However, postoperative target volumes have been
35 described less extensively [7–11] and new developments in head and neck cancer surgery
36 have yet to be evaluated in terms of their consequences on the performance of poRT
37 [2,12,13]. The poRT clinical target volume (CTV of the primary resection site) is classically
38 defined to include the tissues that contain macroscopic or microscopic tumor at risk for
39 tumor recurrence. On the other hand, flaps are present in about half the patients (oral cavity
40 and oropharynx in particular) undergoing poRT (poRT)[14], and flaps result in substantial
41 tissue changes [11,15]. Additionally, several surgical reports have suggested that
42 radiotherapy has deleterious effects on flaps with respect to functional outcomes
43 (dysphagia/swallowing, speech, cosmesis, range of motion) [16–24]. Current radiation
44 oncology literature lacks recommendations for the delineation and management of poRT
45 target volumes when there is a flap in the tumor bed [24–29].

46 We assessed the current state of knowledge based on literature and expertise. Practice
47 patterns among the Groupe d’Oncologie Radiotherapie des Tumeurs de la tete Et du Cou
48 (GORTEC) were analyzed to develop an initial set of recommendations. Subsequently, these
49 proposals were circulated to an international reviewing group from the Head and Neck
50 Cancer International Group (HNCIG) for validation and endorsement. The goal was to
51 develop an international consensus to aid clinical decision-making and to identify areas of
52 controversy and uncertainty related to postoperative irradiation of flaps.

53

54 **Material and methods**

55 A stepwise consensus-building method was used [30,31](Figure 1). The GORTEC steering
56 group, defined by the GORTEC and French Head and Neck InterGroup (HNFIG) coordinator
57 (JT, FC) and composed of head and neck radiation oncologists (N=4), surgical oncologists
58 (N=2) and one radiologist, defined relevant questions based on a systematic review of the

59 literature (Figure 1). A search of MESH terms including “radiotherapy” and “flap” in title
60 yielded 82 references from 1971 to 2021. After eliminating, based on a review of titles and
61 abstracts, non-head, and neck references (N= 41 (>80% breast)), references addressing
62 salvage flap surgery after prior radiotherapy (N= 25), and neoadjuvant radiotherapy and
63 delayed reconstruction (N= 5), there remained 15 articles. These included three case reports
64 in English or other language (N=1) (evidence-based grade C), five retrospective series of 13
65 to 100 patients [24,25,32–34] (grade C) and seven prospective series of 12 to 44 patients
66 [33,35–40], addressing flap changes (N=2) or functional and quality of life outcomes
67 (N=5)(grade B).

68 As a first step, the GORTEC steering group designed a 59-item online questionnaire
69 (www.easy-crf.com/Delphi-Flap-RT). The questionnaire included numerous statements or
70 proposals, covering four major domains, to be agreed or disagreed with. The four domains
71 were: 1) identification of flaps on imaging for flap delineation, 2) understanding of the risk of
72 tumor relapse and tumor spread patterns and definition of target volumes, 3) functional
73 deterioration with respect to expectations of reconstructive surgery with a flap, and 4)
74 feasibility of dose painting using intensity modulated radiotherapy (IMRT) considering a
75 need to adapt poRT in the presence of flaps.

76 In the second step, a GORTEC rating group of 15 radiation oncologists from academic
77 university and general hospitals, comprehensive cancer centers and private clinics, with ≥
78 10-year experience in head and neck cancers, rated all of the statements in two successive
79 rounds (Figure, Table 1). Each proposal was rated between 1 and 9 (1: disagree; 9: totally
80 agree) in rounds 1 and 2 (Table 1). They were informed of their scores and others between
81 rounds 1 and 2. Items not reaching strong or relative agreement (defined in Table 1,
82 requiring a median score of ≥7/9) following round 1 were submitted to the same panelists to
83 be rated again in light of the answers (quantitative feedback) and corresponding arguments
84 (qualitative feedback) of the other panelists (collected during round 2). Proposals not
85 yielding strong or relative agreement after round 2 were eliminated.

86 All items reaching strong or relative agreement following round 2 (Table 1) were then rated
87 by 30 international reviewers. This group was composed of radiation oncologists (N=26),
88 surgical oncologists (N=2) and medical oncologists (N=2), selected for their international
89 reputation for expertise in head and neck cancer management and leadership.

90 Items were accepted when rated between 5 to 9 by 90% of the reviewer Head and Neck
91 Cancer International Group (HNCIG)-endorsed committee and these constituted the final
92 recommendations (Figure 1). Surgeons and medical oncologists reviewed all of the
93 statements related to combined modality treatments; they were invited to review the
94 statements from a multidisciplinary perspective and their responses were incorporated and
95 analyzed separately.

96

97 **Results**

98 After the two successive rounds, strong agreement, relative agreement, or no consensus
99 was achieved for 26, 9 and 24 items out of the initial 59 items, respectively (Table 2). Median
100 scores and final consensus categorizations are provided in table 2. In all, after external
101 review, overall consensus was only clearly achieved across of the four domains, with 11/15
102 items (73.3%) achieving consensus on the risk of radiation-induced functional deterioration
103 of flaps. In the other domains, there was consensus achieved on specific items: 5/9 items
104 (55.6%) on feasibility of poRT dose-painting for flap avoidance; 7/17 (41.2%) items on flap
105 definition; and 2/18 items (11.1%) on risk of tumor relapse and patterns of tumor spread in
106 the presence of a flap (Table 2). Among the items initially validated as achieving
107 strong/relative consensus in the rating group, those not achieving consensus in the third-
108 round reviewing group (n=10) were related to flap delineation (n=3) and tumor spread
109 pattern (n=7).

110 Flap definition on imaging has hardly been addressed in the literature and is described with
111 grade C evidence at best [2,14,15,25,41]. Still, at final review, flap definition was able to
112 achieve strong agreement for 6 items (Table 2). The final recommendations were as follows:
113 (1) surgeons should accurately describe the flap with respect to the native anatomy
114 following tumor resection in standardized operating reports; (2) surgeons should also report
115 whether clips were used in the tumor bed point to areas of dubious R0 or R1 resection or
116 hemostasis; (3) clips should be placed in a standardized manner and regardless of the
117 negligible artifacts that they produce, which do not interfere with delineation and dose
118 calculation; (4) the planning CT should be contrast-enhanced for better flap visualization and
119 to help pick up ignored residual tumor or early relapse.

120 Ten items were controversial: 7 after the second round and 3 after external review (Table 2).
121 Experts disagreed on the degree of difficulty in identifying flap contours or components on a

122 planning CT as well as identification of the junctional area [15]. More importantly, no
123 consensus was reached within the committee as to how the flap should be delineated (Table
124 2). Uncertainties remained on whether to place clips at the flap-tissue junction [42], the
125 usefulness of contrast enhancement to distinguish the vascular anastomosis, and acquisition
126 of magnetic resonance imaging to visualize the flap versus referring to a surgeon for
127 delineation.

128 Tumor risk assessment with respect to the installed flap has only been addressed in a few
129 grade C publications [42–44]. Only 2 items that achieved strong agreement after the rating
130 phase were validated by the reviewing group (Table 2) stating that: (1) clinicians should be
131 aware that the flap-tissue junction is at higher risk of tumor recurrence compared to other
132 areas of the flap and (2) the dose delivered to the junctional area should be the same as the
133 dose delivered to the primary high-risk CTV, if the final resection margin is involved (R2),
134 close (R1) or if there is ambiguity about complete clearance (Table 2). Nine items did not
135 achieve consensus after the rating phase and were not circulated to the review group. The
136 rating group disagreed on enlarged expansions around the preoperative GTV to compensate
137 for delineation uncertainties. The rating group was uncertain about the likelihood of
138 microscopic tumor spread from the junctional area toward the “mucosal or cutaneous” flap
139 surface and the impact of histology or tumor primary site on risk of recurrence. No
140 consensus was reached as to whether the “junctional area” should be considered to be 10
141 mm or more [41]. No consensus was reached as to whether the body of the flap should be
142 included in the low-risk area to decrease morbidity, or if it should be included in the high-risk
143 area to compensate for delineation uncertainties. For pedicled flaps, no consensus was
144 reached as to whether the vascular pedicle should be included in the CTV. For free flaps, it
145 was uncertain as to whether vascular anastomosis is a means of tumor dissemination.

146 Interestingly, 7 items related to tumor spread patterns into flaps and flap definition as a CTV
147 or organ at risk, previously achieving strong/relative agreement after round 2, were not
148 supported by the international review group (Figure 1, Table 2). The review group disagreed
149 on the need for systematic coregistration of the preoperative imaging with the
150 postoperative CT scan to define the postoperative CTV, and on the inclusion in the CTV of
151 "direct" postoperative modifications (edema, hematoma, lymphocele) due to flap surgery.
152 The review group did not agree on the likelihood of microscopic tumor spread patterns from
153 the junctional area toward deep native tissues or whether tumor spread pattern was

154 dependent on flap components (mucosa / skin, fat, muscle / fascia, bone) [15]. The review
155 group also would not endorse consensus on a 6 mm size to define the junction area [44].
156 Similarly, no consensus was reached as to whether very large flaps and vascular anastomosis
157 should be included in the CTV, nor was consensus reached as to which dose should be
158 delivered to the junction area if the resection is R0.

159 A functional deleterious impact of radiotherapy on flaps has been repeatedly suggested in
160 the surgical literature (grade B or C) but has not been formally assessed using controlled
161 studies [24,35]. Strong agreement was achieved for 9 items and relative agreement for 2
162 items (Table 2). The rating group did not reach consensus on differential effects of poRT on
163 vascular anastomosis from free vs pedicled flap, the impact of flap atrophy on functional
164 deterioration or the need for surgical overcompensation. These items were therefore not
165 submitted to the review group. There was consensus after the rating phase that flap necrosis
166 could not result from damage of vascular anastomosis or thrombosis, but rather would occur
167 in the early postoperative period (caused by the vessel quality, morbidity, or technical
168 procedure) regardless of poRT. However, the international recommendation was to consider
169 that poRT altered soft-tissue flap versatility and its functional results (swallowing,
170 phonation) as well as increased the risk of osteoradionecrosis in bone flaps. The final
171 recommendation stated that flap fibrosis or (fat) atrophy occurred spontaneously but could
172 increase with poRT and with dose.

173 Feasibility of complex IMRT modulation for flap avoidance was controversial. The rating
174 group did not achieve consensus on the risk of osteoradionecrosis in the presence of metal
175 in the poRT field, or on the need to avoid irradiating the titanium plate fixing the flap and
176 whether such materials should be substituted. Thus, these items were not submitted to the
177 review group and no final recommendation can be made about them. In the end, strong and
178 relative agreement was achieved for 3 and 2 items, respectively, on international review
179 (Table 2). The final, internationally validated recommendations were (1) to use steep
180 gradients to achieve elimination of maximum dose (hot spots) to a delineated vascular
181 pedicle if feasible but (2) that avoidance might not be achievable in thin flaps and (3) the flap
182 mean dose or maximum dose be reduced if necessary, to limit the risks of fatty atrophy,
183 muscle fibrosis or osteoradionecrosis.

184 One should note that there was substantial variability between the international reviewers
185 for 11 items which had achieved strong/relative consensus in the rating committee but were
186 rejected by the review group (Figure 2). There were also trends by country.

187

188

189 **Discussion**

190 In the past, experience with flaps and radiotherapy was usually limited to salvage surgery
191 occurring in irradiated tissues. With increasing surgical expertise, immediate rather than
192 delayed reconstruction has become standard. Flaps have been used in primary
193 reconstructive head and neck surgery increasingly over the last 2 decades although the
194 pioneering works date to the 70's [1,4,19,20,45,46]. Because tumors that require a flap are
195 usually large and of advanced T stage [47], they often require poRT. In our initial systemic
196 review, we found abundant surgical grade B-C literature suggesting radiation-induced flap
197 changes [34,38,39] and deteriorated functional outcomes [24,33,35–40]. Additional
198 anecdotal (grade C) case studies reported flap loss after poRT. However, no references to
199 flaps appear in the latest postoperative radiotherapy recommendations [11,47]. This reflects
200 heterogeneity in practice but also that the management of flaps during radiotherapy is an
201 area of high ambiguity [2].

202 Our stepwise consensus-building approach among an international community of head and
203 neck experts, mostly radiation oncologists, was able to generate novel recommendations
204 regarding the importance of surgeons reporting on clip placement and operating procedures
205 more accurately. However, due to continuing knowledge gaps concerning flap definition on
206 imaging and more importantly flaps as possible routes for tumor dissemination, there were
207 major uncertainties that translated into significant variability at the international reviewing
208 phase.

209 Our international panel could not agree on in-flap tumor spread patterns and could not
210 determine whether a flap should be considered as part of the clinical target volume. There
211 was no agreement on risk based on tumor site, tumor histology, or flap components as
212 factors influencing tumor spread patterns. It should be emphasized that these subjects
213 lacking consensus are the areas about which future related research and publications should
214 be directed. The results of retrospective non-interventional and prospective multicentric
215 studies will be of importance to better characterize tumor spread patterns in the presence
216 of flaps. There was also lack of agreement on whether the whole flap (+/- its vascular
217 anastomosis) should be included or only its area next to the flap-tissue junction as suggested
218 by one team based on their practice rather than evidence [42–44]. There is concern about
219 irradiation of large pedicled flaps, such as pectoralis major flaps, as including the whole flap

220 in the CTV can inflate irradiated normal tissue volumes significantly and result in more
221 toxicities [25].

222 The international group agreed on the concern about radiation-induced fibrosis and atrophy
223 which might affect function. Therapeutic recommendations were to achieve flap and
224 vascular pedicle dose avoidance through steep gradients potentially using complex fluence
225 modulation. The surgical literature mostly reports small surgical series of fibrosis and
226 atrophy. As the true prevalence of flap atrophy of large fatty flaps is unknown, this is an area
227 requiring further future assessment. There is limited but higher-quality literature (grade B-C)
228 concerning functional outcomes following flap irradiation, which underscores the
229 importance of defining the volumes and doses given to these flaps to better study their
230 effects. There remains a need for better reports of literature and experience-based
231 knowledge of functional outcomes following flap irradiation.

232 Items regarding the management of metal materials for bone flaps were controversial from
233 scratch and could not reach the review phase.

234 An important factor in variability, and a potential limitation of this process, is shown by the
235 11 items that passed the initial rating phase but were rejected by the international group.
236 While in part due to a lack of published evidence or data, there may also be variable
237 experience with postoperative radiotherapy across countries, or even individual centers.
238 There may be various strategies regarding the use of surgery followed by radiotherapy or
239 upfront radiotherapy and consequently the management of flaps [48].

240

241 **Conclusion**

242 The major GORTEC internationally-validated HNCIG-endorsed consensus statements were
243 that the flap-tissue junction should be considered at higher risk of tumor spread compared
244 to other areas of the flap and that postoperative planning should be based on a contrast-
245 enhanced CT. Surgeons should report the placement of flaps more accurately and consider
246 clip placement to guide radiotherapy planning. It was also recommended to consider the
247 risks of radiation-induced atrophy, fibrosis, and osteoradionecrosis and limit the maximum
248 and mean doses during the radiotherapy planning process. There remain substantial
249 knowledge gaps and as result, large areas of international variability. Patterns of tumor
250 spread, and the results of dose-avoidance should be analyzed prospectively with assessment
251 of functional outcomes and quality of life.

252

253 **References**

- 254 [1] Urken ML. Advances in head and neck reconstruction. *The Laryngoscope*
255 2003;113:1473–6. <https://doi.org/10.1097/00005537-200309000-00008>.
- 256 [2] Thariat J, Leleu T, Micault E, Gery B, Bastit V, Jeanne C, et al. [Ten years of advances
257 in head and neck surgery, how does this influence postoperative radiotherapy?]. *Bull Cancer*
258 (Paris) 2020;107:823–9. <https://doi.org/10.1016/j.bulcan.2020.04.011>.
- 259 [3] Cormack GC, Lamberty BG. A classification of fascio-cutaneous flaps according to
260 their patterns of vascularisation. *Br J Plast Surg* 1984;37:80–7.
261 [https://doi.org/10.1016/0007-1226\(84\)90049-3](https://doi.org/10.1016/0007-1226(84)90049-3).
- 262 [4] Lamberty BG, Cormack GC. Progress in flap surgery: greater anatomical
263 understanding and increased sophistication in application. *World J Surg* 1990;14:776–85.
264 <https://doi.org/10.1007/BF01670524>.
- 265 [5] Bozec A, Demez P, Gal J, Chamorey E, Louis M-Y, Blanchard D, et al. Long-term quality
266 of life and psycho-social outcomes after oropharyngeal cancer surgery and radial forearm
267 free-flap reconstruction: A GETTEC prospective multicentric study. *Surg Oncol* 2018;27:23–
268 30. <https://doi.org/10.1016/j.suronc.2017.11.005>.
- 269 [6] Grégoire V, Evans M, Le Q-T, Bourhis J, Budach V, Chen A, et al. Delineation of the
270 primary tumour Clinical Target Volumes (CTV-P) in laryngeal, hypopharyngeal,
271 oropharyngeal and oral cavity squamous cell carcinoma: AIRO, CACA, DAHANCA, EORTC,
272 GEORCC, GORTEC, HKNPCSG, HNCIG, IAG-KHT, LPRHHT, NCIC CTG, NCRI, NRG Oncology,
273 PHNS, SBRT, SOMERA, SRO, SSHNO, TROG consensus guidelines. *Radiother Oncol J Eur Soc*
274 *Ther Radiol Oncol* 2018;126:3–24. <https://doi.org/10.1016/j.radonc.2017.10.016>.
- 275 [7] Chao KSC, Ozyigit G, Tran BN, Cengiz M, Dempsey JF, Low DA. Patterns of failure in
276 patients receiving definitive and postoperative IMRT for head-and-neck cancer. *Int J Radiat*
277 *Oncol Biol Phys* 2003;55:312–21. [https://doi.org/10.1016/s0360-3016\(02\)03940-8](https://doi.org/10.1016/s0360-3016(02)03940-8).
- 278 [8] Grégoire V, Eisbruch A, Hamoir M, Levendag P. Proposal for the delineation of the
279 nodal CTV in the node-positive and the post-operative neck. *Radiother Oncol J Eur Soc Ther*
280 *Radiol Oncol* 2006;79:15–20. <https://doi.org/10.1016/j.radonc.2006.03.009>.
- 281 [9] Grégoire V, Levendag P, Ang KK, Bernier J, Braaksma M, Budach V, et al. CT-based
282 delineation of lymph node levels and related CTVs in the node-negative neck: DAHANCA,
283 EORTC, GORTEC, NCIC, RTOG consensus guidelines. *Radiother Oncol J Eur Soc Ther Radiol*
284 *Oncol* 2003;69:227–36. <https://doi.org/10.1016/j.radonc.2003.09.011>.
- 285 [10] Cho Y, Yoon HI, Lee IJ, Kim JW, Lee CG, Choi EC, et al. Patterns of local recurrence
286 after curative resection and reconstruction for oropharyngeal and oral cancers: Implications
287 for postoperative radiotherapy target volumes. *Head Neck* 2019;41:3916–23.
288 <https://doi.org/10.1002/hed.25928>.
- 289 [11] Evans M, Beasley M. Target delineation for postoperative treatment of head and
290 neck cancer. *Oral Oncol* 2018;86:288–95.
291 <https://doi.org/10.1016/j.oraloncology.2018.08.011>.
- 292 [12] Bernier J, Cooper JS, Pajak TF, van Glabbeke M, Bourhis J, Forastiere A, et al. Defining
293 risk levels in locally advanced head and neck cancers: a comparative analysis of concurrent
294 postoperative radiation plus chemotherapy trials of the EORTC (#22931) and RTOG (# 9501).
295 *Head Neck* 2005;27:843–50. <https://doi.org/10.1002/hed.20279>.
- 296 [13] Bernier J, Dommene C, Ozsahin M, Matuszewska K, Lefèbvre J-L, Greiner RH, et al.
297 Postoperative irradiation with or without concomitant chemotherapy for locally advanced
298 head and neck cancer. *N Engl J Med* 2004;350:1945–52.

299 <https://doi.org/10.1056/NEJMoa032641>.

300 [14] Racadot S, Vérillaud B, Serre A-A, Le Guevelou J, Guzène L, Laude C, et al. [Impact of
301 reconstructive or minimal invasive surgery on the assessment of current definitions of
302 postoperative clinical target volume for head and neck cancers]. *Cancer Radiother J Soc*
303 *Francaise Radiother Oncol* 2020;24:649–57. <https://doi.org/10.1016/j.canrad.2020.05.012>.

304 [15] Le Guevelou J, Bastit V, Marcy PY, Lasne-Cardon A, Guzène L, Gerard M, et al. Flap
305 delineation guidelines in postoperative head and neck radiation therapy for head and neck
306 cancers. *Radiother Oncol J Eur Soc Ther Radiol Oncol* 2020;151:256–65.
307 <https://doi.org/10.1016/j.radonc.2020.08.025>.

308 [16] Yi CR, Jeong WS, Oh TS, Koh KS, Choi J-W. Analysis of Speech and Functional
309 Outcomes in Tongue Reconstruction after Hemiglossectomy. *J Reconstr Microsurg*
310 2020;36:507–13. <https://doi.org/10.1055/s-0040-1709493>.

311 [17] Pierre CS, Dassonville O, Chamorey E, Poissonnet G, Riss J-C, Ettaiche M, et al. Long-
312 term functional outcomes and quality of life after oncologic surgery and microvascular
313 reconstruction in patients with oral or oropharyngeal cancer. *Acta Otolaryngol (Stockh)*
314 2014;134:1086–93. <https://doi.org/10.3109/00016489.2014.913809>.

315 [18] Rihani J, Lee MR, Lee T, Ducic Y. Flap selection and functional outcomes in total
316 glossectomy with laryngeal preservation. *Otolaryngol--Head Neck Surg Off J Am Acad*
317 *Otolaryngol-Head Neck Surg* 2013;149:547–53.
318 <https://doi.org/10.1177/0194599813498063>.

319 [19] Bozec A, Poissonnet G, Chamorey E, Laout C, Vallicioni J, Demard F, et al. Radical
320 ablative surgery and radial forearm free flap (RFFF) reconstruction for patients with oral or
321 oropharyngeal cancer: postoperative outcomes and oncologic and functional results. *Acta*
322 *Otolaryngol (Stockh)* 2009;129:681–7. <https://doi.org/10.1080/00016480802369260>.

323 [20] Bozec A, Poissonnet G, Chamorey E, Casanova C, Vallicioni J, Demard F, et al. Free-
324 flap head and neck reconstruction and quality of life: a 2-year prospective study. *The*
325 *Laryngoscope* 2008;118:874–80. <https://doi.org/10.1097/MLG.0b013e3181644abd>.

326 [21] Bozec A, Poissonnet G, Chamorey E, Casanova C, Laout C, Vallicioni J, et al. Quality of
327 life after oral and oropharyngeal reconstruction with a radial forearm free flap: prospective
328 study. *J Otolaryngol - Head Neck Surg J Oto-Rhino-Laryngol Chir Cervico-Faciale*
329 2009;38:401–8.

330 [22] Zhang X, Li M-J, Fang Q-G, Sun C-F. A comparison between the pectoralis major
331 myocutaneous flap and the free anterolateral thigh perforator flap for reconstruction in
332 head and neck cancer patients: assessment of the quality of life. *J Craniofac Surg*
333 2014;25:868–71. <https://doi.org/10.1097/SCS.0000000000000443>.

334 [23] van Hinte G, Wetzels J-WGH, Merckx MAW, de Haan AFJ, Koole R, Speksnijder CM.
335 Factors influencing neck and shoulder function after oral oncology treatment: a five-year
336 prospective cohort study in 113 patients. *Support Care Cancer Off J Multinatl Assoc Support*
337 *Care Cancer* 2019;27:2553–60. <https://doi.org/10.1007/s00520-018-4534-1>.

338 [24] Shin YS, Koh YW, Kim S-H, Jeong JH, Ahn S, Hong HJ, et al. Radiotherapy deteriorates
339 postoperative functional outcome after partial glossectomy with free flap reconstruction. *J*
340 *Oral Maxillofac Surg Off J Am Assoc Oral Maxillofac Surg* 2012;70:216–20.
341 <https://doi.org/10.1016/j.joms.2011.04.014>.

342 [25] Gérard M, Le Guevelou J, Jacksic N, Lequesne J, Bastit V, Géry B, et al. Postoperative
343 radiotherapy after flap reconstructive surgery in patients with head and neck cancer: A
344 retrospective monocentric study with flap delineation to assess toxicity and relapse. *Cancer*
345 *Radiother J Soc Francaise Radiother Oncol* 2020;24:851–9.

346 <https://doi.org/10.1016/j.canrad.2020.06.024>.

347 [26] Las DE, de Jong T, Zuidam JM, Verweij NM, Hovius SER, Mureau MAM. Identification
348 of independent risk factors for flap failure: A retrospective analysis of 1530 free flaps for
349 breast, head and neck and extremity reconstruction. *J Plast Reconstr Aesthetic Surg JPRAS*
350 2016;69:894–906. <https://doi.org/10.1016/j.bjps.2016.02.001>.

351 [27] Ooishi M, Motegi A, Kawashima M, Arahira S, Zenda S, Nakamura N, et al. Patterns of
352 failure after postoperative intensity-modulated radiotherapy for locally advanced and
353 recurrent head and neck cancer. *Jpn J Clin Oncol* 2016;46:919–27.
354 <https://doi.org/10.1093/jjco/hyw095>.

355 [28] Halle M, Eriksson BO, Docherty Skogh A-C, Sommar P, Hammarstedt L, Gahm C.
356 Improved Head and Neck Free Flap Outcome-Effects of a Treatment Protocol Adjustment
357 from Pre- to Postoperative Radiotherapy. *Plast Reconstr Surg Glob Open* 2017;5:e1253.
358 <https://doi.org/10.1097/GOX.0000000000001253>.

359 [29] Choi S, Schwartz DL, Farwell DG, Austin-Seymour M, Futran N. Radiation therapy does
360 not impact local complication rates after free flap reconstruction for head and neck cancer.
361 *Arch Otolaryngol Head Neck Surg* 2004;130:1308–12.
362 <https://doi.org/10.1001/archotol.130.11.1308>.

363 [30] Jones J, Hunter D. Consensus methods for medical and health services research. *BMJ*
364 1995;311:376–80. <https://doi.org/10.1136/bmj.311.7001.376>.

365 [31] French Haute autorité de santé. Elaboration de recommandation de bonne pratique -
366 Recommandations par consensus formalisé 2010.

367 [32] Tai H-C, Hsieh C-H, Chao KSC, Liu S-H, Leu Y-S, Chang Y-F, et al. Comparison of
368 radiotherapy strategies for locally advanced hypopharyngeal cancer after resection and
369 ileocolic flap reconstruction. *Acta Otolaryngol (Stockh)* 2009;129:311–7.
370 <https://doi.org/10.1080/00016480802163366>.

371 [33] Haymerle G, Enzenhofer E, Lechner W, Stock M, Schratte-Sehn A, Vyskocil E, et al.
372 The effect of adjuvant radiotherapy on radial forearm free flap volume after soft palate
373 reconstruction in 13 patients. *Clin Otolaryngol Off J ENT-UK Off J Neth Soc Oto-Rhino-*
374 *Laryngol Cervico-Facial Surg* 2018;43:742–5. <https://doi.org/10.1111/coa.13042>.

375 [34] Yamazaki M, Suzuki T, Hiraga C, Yoshida Y, Baba A, Saitou H, et al. Effect of
376 postoperative radiotherapy for free flap volume changing after tongue reconstruction. *Oral*
377 *Radiol* 2020. <https://doi.org/10.1007/s11282-020-00489-0>.

378 [35] Winter SCA, Cassell O, Corbridge RJ, Goodacre T, Cox GJ. Quality of life following
379 resection, free flap reconstruction and postoperative external beam radiotherapy for
380 squamous cell carcinoma of the base of tongue. *Clin Otolaryngol Allied Sci* 2004;29:274–8.
381 <https://doi.org/10.1111/j.1365-2273.2004.00812.x>.

382 [36] Leu Y-S, Hsiao H-T, Chang Y-C, Yang C-C, Lee J-C, Chen Y-J, et al. Ileocolic free flap
383 reconstruction, concomitant chemotherapy and radiotherapy and assessment of speech and
384 swallowing function during management of advanced cancer of the larynx and hypopharynx:
385 preliminary report. *Acta Otolaryngol (Stockh)* 2005;125:642–6.
386 <https://doi.org/10.1080/00016480510027457>.

387 [37] Airoidi M, Garzaro M, Raimondo L, Pecorari G, Giordano C, Varetto A, et al.
388 Functional and psychological evaluation after flap reconstruction plus radiotherapy in oral
389 cancer. *Head Neck* 2011;33:458–68. <https://doi.org/10.1002/hed.21471>.

390 [38] Higgins KM, Erovic BM, Ravi A, Yeung R, Lee JW, Yao C, et al. Volumetric changes of
391 the anterolateral thigh free flap following adjuvant radiotherapy in total parotidectomy
392 reconstruction. *The Laryngoscope* 2012;122:767–72. <https://doi.org/10.1002/lary.22509>.

393 [39] Tarsitano A, Battaglia S, Cipriani R, Marchetti C. Microvascular reconstruction of the
394 tongue using a free anterolateral thigh flap: Three-dimensional evaluation of volume loss
395 after radiotherapy. *J Cranio-Maxillo-Fac Surg Off Publ Eur Assoc Cranio-Maxillo-Fac Surg*
396 2016;44:1287–91. <https://doi.org/10.1016/j.jcms.2016.04.031>.

397 [40] Lilja M, Markkanen-Leppänen M, Viitasalo S, Saarilahti K, Lindford A, Lassus P, et al.
398 Olfactory and gustatory functions after free flap reconstruction and radiotherapy for oral
399 and pharyngeal cancer: a prospective follow-up study. *Eur Arch Oto-Rhino-Laryngol Off J Eur*
400 *Fed Oto-Rhino-Laryngol Soc EUFOS Affil Ger Soc Oto-Rhino-Laryngol - Head Neck Surg*
401 2018;275:959–66. <https://doi.org/10.1007/s00405-018-4883-x>.

402 [41] Fleury B, Thariat J, Barnoud R, Buiret G, Lebreton F, Bancel B, et al. [Microscopic
403 extensions of head and neck squamous cell carcinomas: impact for clinical target volume
404 definition]. *Cancer Radiother J Soc Francaise Radiother Oncol* 2014;18:666–71.
405 <https://doi.org/10.1016/j.canrad.2014.04.006>.

406 [42] Bittermann G, Wiedenmann N, Bunea A, Schwarz SJ, Grosu A-L, Schmelzeisen R, et al.
407 Clipping of tumour resection margins allows accurate target volume delineation in head and
408 neck cancer adjuvant radiation therapy. *Radiother Oncol J Eur Soc Ther Radiol Oncol*
409 2015;116:82–6. <https://doi.org/10.1016/j.radonc.2015.04.025>.

410 [43] Bittermann G, Voss P, Duttenhoefer F, Zimmerer R, Vach K, Metzger MC. The validity
411 of surgical clips as radiographic markers for the tumour resection cavity in head and neck
412 cancer treatment. *J Cranio-Maxillo-Fac Surg Off Publ Eur Assoc Cranio-Maxillo-Fac Surg*
413 2015;43:758–62. <https://doi.org/10.1016/j.jcms.2015.04.005>.

414 [44] Bittermann G, Wiedenmann N, Voss P, Zimmerer R, Duttenhoefer F, Metzger MC.
415 Marking of tumor resection borders for improved radiation planning facilitates reduction of
416 radiation dose to free flap reconstruction in head and neck cancer surgery. *J Cranio-Maxillo-*
417 *Fac Surg Off Publ Eur Assoc Cranio-Maxillo-Fac Surg* 2015;43:567–73.
418 <https://doi.org/10.1016/j.jcms.2015.02.021>.

419 [45] Jose B, Banis J, Flynn M, Lindberg R, Spanos WJ, Paris K, et al. Irradiation and free
420 tissue transfer in head and neck cancer. *Head Neck* 1991;13:213–6.
421 <https://doi.org/10.1002/hed.2880130308>.

422 [46] Nakamizo M, Yokoshima K, Yagi T. Use of free flaps for reconstruction in head and
423 neck surgery: a retrospective study of 182 cases. *Auris Nasus Larynx* 2004;31:269–73.
424 <https://doi.org/10.1016/j.anl.2004.03.003>.

425 [47] Margalit DN, Sacco AG, Cooper JS, Ridge JA, Bakst RL, Beadle BM, et al. Systematic
426 review of postoperative therapy for resected squamous cell carcinoma of the head and neck:
427 Executive summary of the American Radium Society appropriate use criteria. *Head Neck*
428 2021;43:367–91. <https://doi.org/10.1002/hed.26490>.

429 [48] Culié D, Garrel R, Viotti J, Schiappa R, Chamorey E, Fakhry N, et al. Impact of HPV-
430 associated p16-expression and other clinical factors on therapeutic decision-making in
431 patients with oropharyngeal cancer: A GETTEC multicentric study. *Eur J Surg Oncol J Eur Soc*
432 *Surg Oncol Br Assoc Surg Oncol* 2018;44:1908–13.
433 <https://doi.org/10.1016/j.ejso.2018.05.022>.

434

435

436

437

438

439

440 **Figures and Tables legend**

441 Figure 1 **consensus methodology** (adapted from the French Health authorities
442 'recommendation, https://www.has-sante.fr/upload/docs/application/pdf/2011-06/guideline_by_formal_consensus_quick_methodology_guide_110531.pdf)

443 Legend: GORTEC : Groupe d'Oncologie Radiotherapie des tumeurs de la Tete Et du Cou,
444 HNFIG : Head and Neck French InterGroup, international Head and Neck Cancer experts /
445 HNCIG : Head and Neck Cancer International Group

447

448 Figure 2 **Analysis of items** that passed the initial rating phase but were rejected by the
449 international review group, with voting by country.

450

451 Table 1 **Criteria for acceptance of proposals** based on median value and distribution of
452 ratings.

453

454 Table 2 **Proposals submitted and rated** across successive rounds.

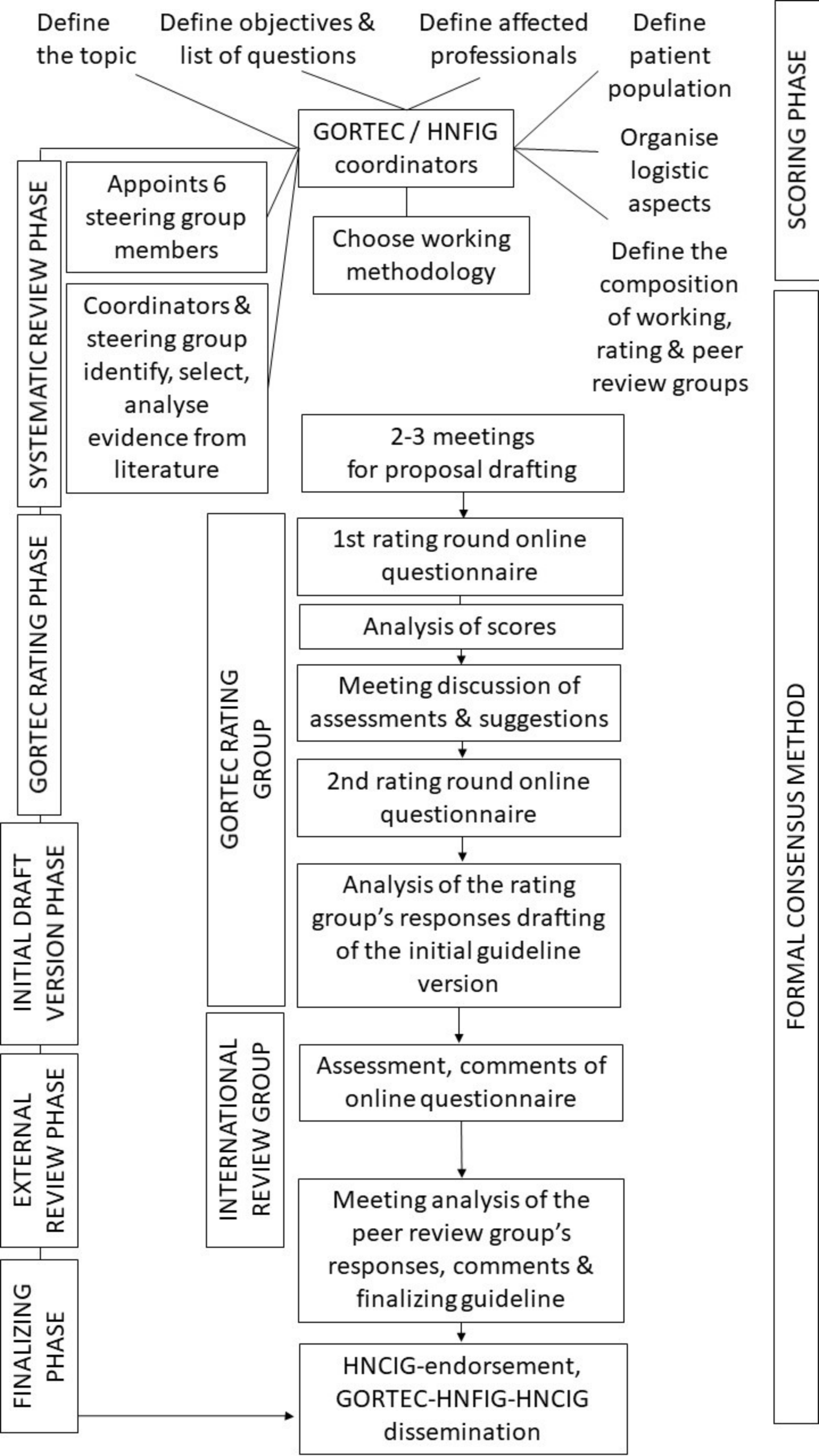


Table 1: Criteria for acceptance of proposals based on median value and distribution of ratings.

Proposal evaluation		Median value	Distribution of responses
Appropriate	Strong agreement	≥ 7	All between [7- 9]
	Relative agreement	≥ 7	All between [5- 9]
Inappropriate	Strong agreement	≤ 3	All between [1- 3]
	Relative agreement	≤ 3.5	All between [1- 5]
Uncertain	Indecision	$4 \leq \text{median} \leq 6,5$	All between [1-9]
	Lack of consensus	All others	

For a group of more than 15 experts, analysis in the second round allowed exclusion of a missing value or a value opposite to that dominant group.

Table 2: Proposals submitted and rated across successive rounds.

Item	Proposals established by a GORTEC steering committee and present at:	GORTEC Rating Committee		External Review group
		Round 1	Round 2	Round 3
Flap Delineation				
1	It is not well defined how to identify the flap contours on a planning CT	NC [6]	RA [7]	NC
2	It is difficult to identify the components of a flap according to their density on the planning CT	NC [7]	SA [7]	NC
3	The junction area (as defined by Bittermann) is difficult to define on a postoperative CT scan	NC [7]	SA [8]	NC
4	Surgeons should report on the position of the flap with respect to the native anatomy following tumor resection in their operating report	NC [8]	SA [8]	FR
5	It is important that surgeons report whether they used clips for hemostasis in the flap area	NC [5]	RA [7]	FR
6	It is important that surgeons report on using clips to define areas of questionable (dubious R0 or R1) resection	NC [5]	SA [8]	FR
7	The placement of clips around the tumor bed should be standardized between surgeons and described in the operating report	NC [8]	SA [8]	FR
8	The use of clips does not induce significant artifacts and should not interfere with delineation and dose calculation	NC [6.5]	SA [8]	FR
9	It is important that the planning CT be contrast enhanced to better visualize the flap	NC [7.5]	SA [8]	FR
10	It is important that the planning CT be contrast enhanced so as not to ignore an early evolution or a macroscopic postoperative tumor residue	SA [9]		FR
11	It is important to contour the flap	NC [5]	NC [7]	
12	It is not necessary to contour the flap because it is systematically positioned in an area to be irradiated (in the primary CTV T or in the prophylactic lymph node volumes N)	NC [5]	NC [3]	
13	It is important for surgeons to describe in their operating report whether they are using clips to show the junction area between the flap and native tissues remaining after tumor resection	NC [5]	NC [7]	
14	It is important to inject the planning CT to visualize the vascular pedicle	NC [7]	NC [7]	

15	Postoperative MRI might be helpful to improve visualization of the flap	NC [6]	NC [6]	
16	The recommendations for delineating CTVs are applicable whether there is a flap in the operating area or not (recommendations of Evans 2018 postoperatively)	NC [6]	NC [5]	
17	It is essential to carry out the delineation in the presence of the surgeon	NC [4]	NC [3]	
Tumor spread pattern in a flap				
18	Coregistration of the preoperative imaging with the postoperative CT scan should be performed systematically to define the postoperative CTV	NC [8]	RA [8]	NC
19	Coregistration uncertainties (of the preoperative imaging with postoperative planning CT) should be compensated by expanding larger margins (than recommended for postoperative radiotherapy) around the preoperative GTV	NC [6]	NC [5]	
20	"Direct" postoperative modifications (edema, hematoma, lymphocele) of the flap should be included in the CTV	NC [7]	SA [7]	NC
21	The risk of microscopic tumor spread is centrifugal from the junction area to the depth of the remaining native tissues	NC [7]	SA [8]	NC
22	The risk of spreading microscopic disease is centrifugal from the junction area to the "mucous or cutaneous" surface of the flap	NC [4.5]	NC [5]	
23	The risk of microscopic diffusion into the flap may vary depending on the histology (squamous cell carcinoma and variants, adenoid cystic carcinoma, adenocarcinoma...)	NC [5]	NC [6]	
24	The risk of microscopic diffusion into the flap may vary depending to the tumor location (parotid vs pharynx vs sinus)	NC [6.5]	NC [6]	
25	The junction area between the native tissues (remaining after tumor resection) and the deep part of the flap is an area at higher risk of cancer	SA [8]		FR
26	The junction area is an area of the order of 6 mm thick in the depth of the flap as described by Bittermann (2015)	NC [6]	RA [7]	NC
27	The junction area at risk is about 10 mm thick in the depth of the flap	NC [5.5]	NC [5]	
28	The junction area varies in thickness depending on the nature of the components of the flap (mucosa / skin, fat, muscle / fascia, bone)	NC [7]	SA [7]	NC
29	The body of the flap (including all the rest of the flap beyond the junction area) should be irradiated entirely in the low-risk area	NC [4]	NC [3]	

30	When the flap is very large, some of the flap body may not be included in the low-risk area	NC [6.5]	SA [8]	NC
31	The delineation uncertainties are so great in the postoperative situation that it is better to irradiate wide even if it means including the entire flap	NC [4.5]	NC [7]	
32	For pedicled flaps, it is not useful to include the vascular pedicle in the CTV. Its tumor colonization is unlikely, and its distal part is far from the operating bed of the primary patient	NC [4.5]	NC [7]	
33	For free flaps, vascular anastomosis is not a way of tumor dissemination	NC [5]	NC [7]	
34	The dose level delivered to the junction area corresponds to primary low-risk CTV if the resection is R0	NC [7.5]	RA [8]	NC
35	The dose level delivered to the junction area corresponds to primary high-risk CTV if the final quality of the resection is dubious R0 or R1 or R2	SA [8]		FR
Functional flap outcomes				
36	Flap necrosis occurs in early postoperative (vessel quality, morbidity, technical procedure) and radiotherapy does not induce any specific risk	NC [7]	SA [8]	FR
37	Irradiation of the vascular pedicle of a flap induces a risk of necrosis of the flap that is negligible (=unlikely) (strong agreement)	NC [7]	SA [8]	FR
38	The dose received at the vascular anastomosis is not correlated with an increased risk of vascular thrombosis	NC [7]	RA [8]	FR
39	Irradiation of the vascular pedicle from a free flap is at higher risk of necrosis than irradiation of a vascular pedicle from a pedicled flap (no consensus)	NC [5]	NC [5]	
40	Radiotherapy alters the flexibility of the flap	NC [7]	SA [8]	FR
41	Radiotherapy can alter the functional results (swallowing, phonation) of the flap	NC [7]	SA [7]	FR
42	Irradiation of a bone flap is at risk of radionecrosis of the flap	NC [7]	SA [8]	FR
43	Atrophy of the fat flaps is possible spontaneously even in the absence of radiotherapy	NC [7]	SA [8]	FR
44	The risk of atrophy of the flap fat increases with radiotherapy	NC [8]	SA [8]	FR
45	Flap fat atrophy is associated with deterioration of functional results	NC [5.5]	NC [5]	
46	Flap fat atrophy MUST BE anticipated by surgeons by overcompensating tissue / flap thickness	NC [7]	NC [7]	
47	The radiation-induced atrophy of the fatty component of the flaps is related to the dose received	NC [5]	NC [7]	
48	Fibrosis changes of flaps are possible spontaneously even in the absence of radiotherapy	NC [6]	RA [7]	FR

49	Fibrosis of the muscle flap component can be favored by radiotherapy (significantly more than surgery alone)	NC [7]	SA [7]	FR
50	Radiation-induced flap fibrosis increases with dose	NC [7]	SA [7]	FR
Technical IMRT feasibility (dose painting for structure avoidance)				
51	For thin flap, it may not be possible to achieve sufficiently steep gradients to spare the flap of the part	NC [7.5]	SA [8]	FR
52	Limiting the average dose to the flap could limit the risk for fatty atrophy and muscle fibrosis	NC [6]	RA [7]	FR
53	Limiting the average dose to the bone of the flap could limit the risk for flap osteoradionecrosis	NC [7]	RA [7]	FR
54	Limiting the maximum dose to the bone flap could limit the risk for osteoradionecrosis	NC [8]	SA [8]	FR
55	In the case of a bone flap, the presence of titanium, or other metal, in the irradiation area induces an increased risk of osteoradionecrosis	NC [7.5]	NC [6]	
56	In the case of a bone flap, avoid irradiating the titanium plate fixing the flap allows to reduce the risk of osteoradionecrosis	NC [4.5]	NC [3]	
57	In the case of a bone flap, titanium-type materials must be substituted to reduce the risk of osteoradionecrosis	NC [4.5]	NC [5]	
58	Limiting the maximum dose (hot spots) to the vascular pedicle seems feasible technically if the pedicle is delineated	NC [7]	SA [7]	FR
59	Limiting the maximum dose (hot spots) to the vascular pedicle would reduce the risk of necrosis of the flap	NC [5]	NC [6]	

Legend: SA strong agreement, RA relative agreement, NC no consensus, FR final recommendation; GORTEC steering committee and GORTEC rating committee are independent; median is indicated between brackets (median = 7-9 is required but ≥ 2 eliminating grades qualify items as NC for the first two rounds).