



## Technical recommendations and interpretation guidelines for electroencephalography for premature and full-term newborns

Genevieve Malfilatre, Luc Mony, Daniele Hasaerts, Patricia Vignolo-Diard, Marie-Dominique Lamblin, Emilie Bourel-Ponchel

### ► To cite this version:

Genevieve Malfilatre, Luc Mony, Daniele Hasaerts, Patricia Vignolo-Diard, Marie-Dominique Lamblin, et al.. Technical recommendations and interpretation guidelines for electroencephalography for premature and full-term newborns. *Neurophysiologie Clinique = Clinical Neurophysiology*, 2021, 51 (1), pp.35-60. 10.1016/j.neucli.2020.10.005 . hal-03604345

**HAL Id: hal-03604345**

**<https://u-picardie.hal.science/hal-03604345>**

Submitted on 14 Feb 2023

**HAL** is a multi-disciplinary open access archive for the deposit and dissemination of scientific research documents, whether they are published or not. The documents may come from teaching and research institutions in France or abroad, or from public or private research centers.

L'archive ouverte pluridisciplinaire **HAL**, est destinée au dépôt et à la diffusion de documents scientifiques de niveau recherche, publiés ou non, émanant des établissements d'enseignement et de recherche français ou étrangers, des laboratoires publics ou privés.



Distributed under a Creative Commons Attribution - NonCommercial 4.0 International License

## GUIDELINES

# Technical recommendations and interpretation guidelines for electroencephalography for premature and full-term newborns

Geneviève Malfilâtre<sup>1</sup>, Luc Mony<sup>2</sup>, Danièle Hasaerts<sup>3</sup>, Patricia Vignolo-Diard<sup>4</sup>, Marie-Dominique Lamblin<sup>5</sup>, Emilie Bourel-Ponchel<sup>6,7,\*</sup>

<sup>1</sup> Neonatal Intensive Care Unit, CHU Tivoli, 7100 La Louvière Belgium

<sup>2</sup> Neurophysiology unit, Le Mans Hospital center, 72037 Le Mans Cedex, France

<sup>3</sup> Dienst kinderneurologie, UZ Brussel, Laerbeeklaan 101, 1090 Brussels Belgium

<sup>4</sup> Department of Clinical Neurophysiology, APHP, Necker-Enfants Malades Hospital, Paris, France

<sup>5</sup> Clinical Neurophysiology, Roger Salengro Hospital, CHRU Lille

<sup>6</sup> INSERM UMR 1105, Research Group on Multimodal Analysis of Brain Function, University of Picardie Jules Verne, 80036 Amiens Cedex, France

<sup>7</sup> INSERM UMR 1105, Pediatric Neurophysiology unit, Amiens University Hospital, 80054 Amiens Cedex, France

Corresponding author:

*Emilie Bourel-Ponchel, EFSN Pédiatrique, CHU Amiens-Picardie*

*1 rond-point du Pr Christian Chabrol, 80054 Amiens cedex, France,*

*Telephone number: +33 322 887 775,*

*Fax number: +33 322 889 757*

*E-mail: emilie.bourel@u-picardie.fr*

**Running title:** EEG for premature and full-term newborns: technical recommendations

## Abstract

Electroencephalography (EEG) of neonatal patients is amongst the most valuable diagnostic and prognostic tool. EEG recordings, acquired at the bedside of infants, evaluate brain function and the maturation of premature and extremely premature infants. Strict conditions of acquisition and interpretation must be respected to guarantee the quality of the EEG and ensure its safety for fragile children. This article provides guidance for EEG acquisition including: (1) the required equipment and devices, (2) the modalities of installation and asepsis precautions, and (3) the digital signal acquisition parameters to use during the recording. The fundamental role of a well-trained technician in supervising the EEG recording is emphasized. In parallel to the acquisition recommendations, we present a guideline for EEG interpretation and reporting. The successive steps of EEG interpretation, from reading the EEG to writing the report, are described. The complexity of the EEG signal in neonates makes artefact detection difficult. Thus, we provide an overview of certain characteristic artefacts and detail the methods for eliminating them.

**Keywords:** artefacts, EEG, EEG indication, EEG report, electroencephalography, newborn infant, premature infant, recording techniques

## Introduction

Electroencephalography (EEG) of neonatal patients is amongst the oldest and most valuable diagnostic and prognostic tools available at the bedside of the infant [5,20,30,33,43,57]. The didactic objective of this section is to facilitate the accessibility of acquisition and interpretation of EEG within neonatal units. To be relevant, this technique must ideally be made available 24 hours a day by the medical and nursing staff of neonatal intensive care units (NICUs) or a team of on-call neurophysiological technicians [6,31]. Technological advances have made the development of ergonomic and high-performance digital acquisition stations possible. These stations can record the EEG signals within the incubators. Nevertheless, the quality of an EEG of a premature newborn depends on addressing certain specific challenges. Respect for homeostasis, biorhythms, positioning, and continuity of care of premature newborns are essential [4,15]. The application of aseptic rules must be rigorous. Under these conditions, the EEG is a valuable and safe tool to assess the brain function of newborns in the NICU. The technical specificities related to the young age, immaturity, and morphology of these fragile patients are herein detailed.

## Equipment

The system equipment can be set up in various ways. However, all configurations share a common set of core components, including sensors (electrodes), one amplifier, and a data-acquisition computer. The sensors are connected to the amplifier. The amplifier filters and measures the EEG signals from the sensors and samples them at millisecond intervals. The digitized samples are transferred to the data-acquisition computer in real time.

### *Data-acquisition computer and amplifiers*

High quality amplifiers are required to acquire dependable data. Certain technical characteristics must be considered, including the **hardware filtering** and **sampling rate**. The analogical signal is filtered (hardware filtering) before amplification and digitization. The technical characteristics of the bandwidth must be carefully considered before purchasing the hardware. In routine EEG, the generally recommended bandwidth must be between 0.0053 – 500 Hz [56]. With direct current (DC) amplifiers, there is no high-pass filter, allowing the digitization of all low frequencies [53]. After filtering and amplification, the biological (analogical) electrical signal is converted into a digital signal. Before digitization, the EEG signal must be sampled. Sampling rates must respect the theorem of Shannon-Nyquist.

Therefore, the digital sampling rate of the converter must be at least two times higher than the useful maximum frequency [42]. If this rate is lower, high-frequency signals will be “aliased” to lower frequencies that will be superimposed on the original, true, signal, inducing artefacts (aliasing artefact) [42]. Moreover, the signal should be filtered using an anti-aliasing passband filter for the useful frequency band (0—70 Hz) necessary for EEG interpretation [55,56]. A rate of 256 samples per second is sufficient for common clinical practice, but 512 Hz is preferred to avoid aliasing phenomena in high-definition screening [56].

The headbox should include sufficient EEG inputs and bipolar channels for an electrocardiogram (ECG), electromyogram (EMG), electrooculogram (EOG), the measurement of respiratory signals, pulse oximetry, etc (at least 22 inputs). The amplifier design must be easy to use. To aid the technician, the headbox should include a 10-20 head stamp (i.e. mimics an anatomical representation of the head, with electrode location on the scalp), including an on-board impedance check.

A high-resolution video synchronized in real time with the EEG acquisition is required [56].

A high-definition monitor is recommended for EEG visualization. Interpreters should be aware that some loss at high-frequency resolution will otherwise occur, along with the possibility of lower-frequency distortion due to spatial aliasing [28]. EEG-software is also important to consider. The EEG software should allow easy modification of the signal display parameters for each channel (noise filter, high- and low-pass filters, signal amplitude). A quick change between existing montages or creation of a new one should be easily possible. The archiving of data must be secure [45].

### ***EEG electrodes and headcaps***

The electrodes (sensors) pick up changes in voltage originating at the surface of the subject’s head, along with a certain amount of electrical noise from the room environment. Physically, the sensors are connected to the amplifier via cables. The electrodes and cables must respect high technical requirements, especially when recording in the NICU [12,16,56].

- ***Silver-silver chloride and gold-cup electrodes*** have been shown to be the best electrical conductors. In common practice, 10-mm diameter silver-silver chloride electrodes are recommended [45,47,49]. They are fixed by an adhesive conducting gel or paste and secured by an elastic net around the head (Figures 1A, 1B).

- **Disposable electrodes**, such as ECG electrodes, can also be used but require more care/attention when placing them because the conductive paste must not extend from one electrode to another to avoid a shunting effect [55,56]. They are less efficient for an agitated baby.
- **Needle electrodes** have been used for critically ill and comatose infants; they must now only be used exceptionally in the NICU according to the developmental care program (*Initiative Hôpital Ami des Bébés* (IHAB) and the practice of the Newborn Individualized Developmental Care Assessment Program (NIDCAP) [28].
- **Integrated headcap EEG systems** specifically designed for neonatal patients are now available on the market. They can contain from 12 to 128 electrodes and combine ease of use and speed of placement with high density/resolution electrogenesis analysis. Various sizes are available for preterm and term infants according to the size of the head.

Regardless of the electrode type, at least 11 electrodes based on the 10/20 system adapted from neonates are required [5,26,30,45,56] (Figure 1).

### ***Annexed records [12,40,56]***

To precisely study sleep organization or abnormal movements and help in artefact recognition, neonatal EEGs must consist of a polygraphic recording and, aside from the EEG, also require at least an ECG and a trace of the respiratory movements. Ocular movements, muscle activity (EMG), and the measurement of oximetry saturation (SaO<sub>2</sub>) can complete the recording of the EEG. Synchronized video acquisition is mandatory.

The technical details concerning these devices are listed in Table 1 [5,56]:

- **ECG**: the ECG recording provides information about the heart rate and allows the recognition of ECG artefacts for the EEG leads. It is generally performed using specific single-use ECG electrodes.
- **Respiration**: recording thoracic and abdominal movements provides information about the respiratory rate, which is essential for artifact recognition. The techniques most often used are a thoracic strain gauge or abdominal belt. It can be completed with a nasal thermistor [22,28].

- ***SaO<sub>2</sub>***: measuring oximetry saturation provides information about the general condition of the infant and complements the analysis of the cardiac and respiratory rhythms if there are neuro-vegetative events.
- ***Ocular movements***: the measurement of eye movements is essential for classification of the sleep state; they can be detected by EOG recording or visual observation. EOG electrodes are applied slightly lateral to and above the left canthus and below the right canthus (Figure 1). The reference electrode is placed on the base of the nose (i.e. the nasion) [5,22,26,28,40].
- ***EMG***: muscle tone is recorded via two surface electrodes filled with Ag-AgCl or flat-skin ECG electrodes. The active electrode is placed on the muscle of interest (chin muscle, deltoids, etc.) and the reference electrode is placed 2 cm from the active electrode (mastoid for the chin muscle). A monopolar montage can also be used.
- ***Synchronized video recording***: the video recording is mandatory [5,45]. It documents paroxysmal motor events and is helpful in excluding artefacts, such as nursing intervention, manual ventilation in case of acute degradation, pulmonary physiotherapy, endotracheal suction, artificial ventilation, patting or rocking movements, and sucking on a pacifier or endotracheal tube.

### ***Abrasive pastes and conducting gels***

Conducting gels and pastes are essential for acquisition of the EEG signal. They reduce and stabilize the impedance, ideally below 5 k $\Omega$  during the recording. Numerous gels are available on the market. Studies on their conductive performance and their safety are rare. The best conduction and stability are obtained with gels containing a sufficient amount of chloride ions [49].

Previously, ether and acetone were used in the preparation of the scalp to improve the impedance and fixation of the electrodes. Similarly, collodion was used for fixation of the electrodes. Their use is now prohibited due to their toxicity and flammability [6,12,28]. They have been replaced by pastes based on sweet almond oil, oleo-limestone liniment, or pumice stone. Very little is known about local tolerance to conducting gels. Some allergies, redness, or breakdown of the skin have been described [24,34,36,48]. A comprehensive description of the composition of these gels is difficult to obtain. As European recommendations relating to

health devices are being drawn up, the use of EEG pastes and gels must similarly be subject to a thorough evaluation.

## **Installation, preparation, and course of the recording (video)**

### ***Environment – surroundings – positioning of the infant***

The recording of an EEG in premature infants should be performed in their usual environment, under the same conditions of sound and light. The EEG set-up procedure must coincide with the usual care of the child. The infant should not be woken up during the set-up procedure. For children fed by gavage or bottle or breastfeeding, the ideal time for sensor placement is just before the meal. For fasting patients, very regular heart and respiratory rhythms on the monitor indicate that the child is asleep [4]. The NIDCAP principle suggests not disturbing the child at that precise moment. The material can be preparing while waiting for the newborn to awaken. The installation of a bedside EEG in neonatology is always performed in agreement with the local nursing staff. Performing a conventional EEG on these tiny babies requires teamwork between neurophysiologists and the neonatal team.

These actions must be carried out by experienced personnel who are familiar with the techniques to minimize the intrusion into the child's routine [6,31]. The assistance of the nurse in charge of the child is essential. She can support and install the child to respect the principles of NIDCAP care and reduce the time of intrusion and handling of the patient [4,15].

The premature patient should be comfortably placed in a supine or lateral position. The support devices used in developmental care should be adapted to ensure good visibility of the patient during video recording.

### ***Aseptic rules (Table 2)***

Hygienic rules are very strict and must follow the department's hygiene protocols, such as a short-sleeved work uniform, no jewelry on the hands or wrists, short nails, mandatory hand washing before preparing the equipment and before handling the patient and putting on a clean over-blouse before any contact.



All materials that may possibly contact the child must be disinfected. The hardware of the equipment is prepared in advance (mobile EEG station, EEG electrodes, respiratory sensor, cardiac, muscle, and eye electrodes, abrasive paste, conductive paste, sterile compresses, etc.).

### ***Scalp preparation***

The installation of an EEG is performed on a clean and dry scalp. The scalp is carefully cleaned with a neutral soap in its entirety. Abrasive pastes should be used with caution, especially for very premature babies due to the fragility of the skin and the risk of infection [40].

### ***EEG electrode installation***

Eleven active surface electrodes are positioned according to the 10/20 system modified for neonates: Fp1, Fp2, C3, C4, T3, T4, O1, O2, Fz, Cz, and Pz (Figures 1A, 1B) [5,28,30,31,45]. By convention, even electrodes are placed on the right-hand side and odd electrodes on the left-hand side. “z” describes the electrodes positioned on the vertex line. This system respects the equidistance between the electrodes and the left-right symmetry [58].

First, the distance between the two ears and between the nasion (root of the nose) and inion (occiput) are measured. The central Cz electrode is placed first, in the middle of the line joining the two ears and that joining the nasion and inion. Based on the nasion-inion distance, the Fz electrode is placed 20% forward of Cz and the Pz electrode 20% backward from Cz. Central electrodes C3 and C4 are placed on each side of Cz, at a distance representing 20% of the distance between the two ears. Temporal electrodes T3 and T4 are placed on each side of C3 and C4, respectively, at a distance representing 20% of the distance between the two ears. The fronto-polar electrodes, Fp1 and Fp2, are placed forward of the central electrodes (C3 and C4, respectively; 20% of the nasion-inion distance). The occipital electrodes, O1 and O2, are placed behind the central electrodes (C3 and C4, respectively; 20% of the nasion-inion distance).

The choice of the reference is important. The reference electrode is usually placed in the fronto-medial position. The ground electrode can be the reference electrode, but it can also be a separate electrode. Depending on the child's head size, the reference electrode may also be placed on the ear, mastoid, or cheek [28,56].

### ***Choice of the annexed records***

Neonatal EEG consists of polygraphy and must contain at least one ECG channel and at least one respiratory sensor for the recognition of artefacts and the diagnosis of cardiorespiratory events [5,6,28,31,43,45,56]. Synchronized video is mandatory [45]. The other annexed records depend on the indication of the EEG. The recording of the SaO<sub>2</sub> +/- thermistor is required for evaluating apnea [22]. If seizures are suspected, the recording of muscular activity is systematic [26,45]. For the precise scoring of sleep states, EOG and chin muscle activity and a second respiratory sensor recording are necessary [12,22,26].

### ***Quality control and impedance verification***

It is recommended to maintain the skin impedance around 5 k $\Omega$ , but an impedance of 10 k $\Omega$  is also acceptable [6,28,45,56]. Because of the low voltage of the EEG signal in premature infants, EEG background noise for a 5 k $\Omega$  input resistance should be < 1.5  $\mu$ volt to validate electro-cerebral inactivity [56]. It is recommended to verify the impedance at the beginning and end of the examination, as well as during each degradation in the quality of the EEG trace and/or the presence of artefacts. This quality control must be accessible during the interpretation of the trace [6,25].

At the beginning of the recording and in the absence of any filter, it is important to ensure that there is minimal sector noise. Such noise is common in the NICU because of the many devices surrounding the patient. Sector noise is more visible on the monopolar reference montage, i.e. in which all active electrodes are referred to the physical reference. After this check, the 50 Hz/60 Hz notch filter can be activated (see artefact identification) [6,31,56].

### ***Course of the EEG***

The technician plays a crucial role during the acquisition. He or she has to simultaneously observe the behavior of the newborn and the EEG activity [6,12,31,45]. To help the technician, it is recommended to modify the amplification gain, filters, and montages as soon as necessary at any time during the acquisition (see interpretation section).

### ***Observation and stimulation of the patient***

The acquisition device should be placed as close as possible to the child to allow observation and annotation of the child's behavior during recording. Observation of the patient starts during electrode placement; the reactivity of the infant must be noted. The observation of the

patient's behavior can be transcribed into the acquisition software via the computer keyboard, which directly integrates the remarks into the child's plot. Live observation is important, even in the presence of a video recording, because normal or abnormal movements may be very subtle and of insufficient resolution to be captured by video [6,12,31].

The following aspects are important to consider: opening and closing of the eyes, eye movements, body movements, fine movements of the extremities, facial expressions, sighs, suction movements, and possible abnormal events, such as tremors, myoclonus, shouts, automatic movements, or brady-apneic events. Caregiver intervention should also be reported, as it generates many confounding artefacts that mimic an ictal episode. It is also important to know the installation/position of the patient, as well as the existence of scalp abnormalities, such as cutaneous lesions, edema, or a cephalohematoma [6,12,22,31].

During data acquisition, the technicians should constantly monitor the newborn and note all clinical, technical, or EEG events on the recording. Technicians must be trained to recognize all states of alertness and clinical and EEG symptoms of seizures in the premature patient [6,22,31,56].

Neurosensory stimulation (tactile or auditory) is carried out at the end of the recording to test EEG reactivity [6,31,55,56].

### ***Duration of the recording***

The duration of the recording depends on the EEG indication [5,29,31].

An EEG performed to evaluate brain maturation should include all states of alertness normally present at the newborn's postmenstrual age at the time of the EEG. After 28 wPMA, the minimal duration of an EEG acquisition aims to record a complete sleep-wake cycle. For the earliest gestational ages (GAs), sleep states are still immature and difficult to identify. In critically ill patients, cycling is less obvious. Thus, at least one hour of interpretable EEG is necessary [26,28,31,40,56].

In preterm newborns, the time between two feedings provides sufficient time to record more than one sleep-wake cycle. The electrodes can be placed before or during breastfeeding or bottle or gavage feeding. Soon after feeding, the neonate is expected to fall asleep, giving the opportunity to record active and quiet sleep. A recording during wakefulness can be expected at the end of the inter-meal period [22,28].

Certain clinical conditions, such as the search for critical discharges, may require an extension of the recording time, or even an EEG monitoring of several hours, or days. Indeed, 24-hour monitoring has been shown to be necessary for high-risk populations [14,39,41,44,52].

## **Indications for EEG in the premature infant**

EEG is an essential diagnostic tool. EEG highlights specific pathological figures, such as positive Rolandic sharp waves (PRSW) in the early diagnosis of periventricular leukomalacia (PVL) [32,33,35,37,38,43,51,57]. EEG is also required to distinguish seizures from other paroxysmal events [8,9,33,43,54,57].

EEG is also an important prognostic tool [8,9,17,18,33,38,51,54,57]. Through evaluation of the physiological organization and maturation of electrogenesis, it aids in the determination of GA. The presence of pathological features and/or abnormalities of background activity, the absence of specific features, and the evolution of EEG activity between successive recordings are important in neuro-developmental prognoses.

EEG can be performed at any time after birth, but its diagnostic and prognostic value depends on when it is performed. For premature infants, it is important to record EEGs in specific time-windows. These time-windows are determined by the GA at birth, the post-menstrual GA (PMA), and the presence of neurological risk factors (Table 3). They are also guided by the occurrence of clinical events. The EEG must be repeated to determine maturation dynamics (Table 4) [5,29–31].

### ***Indications according to gestational age and risk factors (Table 4)*** ***[5,29]***

*Extreme prematurity* is in itself a neurological risk factor. Systematic surveillance is required below 28 weeks gestational age (wGA). Two recordings during the first week of life, one between 31 and 32 weeks post menstrual age (wPMA or gestational corrected age) and one at 36 wPMA are recommended.

*For premature infants born between 29 and 33 wGA*, in the absence of known risk factors, a systematic tracing is recommended during the first week of life. This should be repeated at close intervals if abnormalities are present. In the presence of risk factors, it is recommended to perform two EEG recordings in the first week of life, one at 31-32 wPMA and one at 36 wPMA.

*For premature infants born after 33 wGA, an EEG is performed systematically only if risk factors are present during the first week of life. It must be repeated if abnormalities are present.*

### ***Indications according to clinical paroxysmal events (Table 5)***

EEG is mandatory in the presence of clinical events suggesting seizures (Table 5) [29,43,44]. EEG is the only way to accurately identify and quantify whether or not such paroxysmal clinical events are seizures [23,29,44,45]. The International League Against Epilepsy (ILAE) task force emphasizes the role of EEG in the diagnosis of seizures in the neonate. Although certain types of seizures, such as clonic seizures, can be identified more reliably than other types, certain autonomic seizures and seizures with behavioral arrest require EEG confirmation [59].

The chronology of the recordings varies depending on the clinical evolution. The diagnosis of seizures requires EEG monitoring for at least several hours, ideally 24, to guide treatment and establish the prognosis [29,44]. After the acute phase, it is important to perform an EEG at least once a week. In the event of an abnormal trace in conjunction with sedation, a control EEG should be carried out once sedation has been stopped [29].

## **Anamnesis and request form [3,6,29,30,56]**

For a valid EEG trace, the request form must include the following information:

- The reason for the examination
- Gestational age at birth and postmenstrual/gestational corrected age on the day of recording
- Existence of pre- and postnatal risk factors of neurologic complications (Table 3)
- Clinical history: pregnancy history, birth history, Apgar score, specific events (Table 3)
- Medical and surgical procedures
- Neurological diagnosis: history of possible seizures and location (Table 5)
- Neuroimaging results
- Current medications: doses and timing of drug therapy given to the child or his/her mother, especially benzodiazepines and anti-epileptic drugs
- Type of respiratory support, invasive or non-invasive ventilation settings

- Blood gas results:  $\text{paO}_2$ ,  $\text{pCO}_2$
- The infant's temperature
- History of family illness

## **Interpretation guidelines and report**

### ***Reading conditions***

With the digitalization of the data, acquisition settings can be modulated easily during review/reading to choose the accurate EEG data and eliminate artefacts:

- The gain or amplification is initially set to 10  $\mu\text{V}/\text{mm}$  and regularly adjusted on the digital device [5,12,29].
- The bandwidth of the neonatal EEG frequencies varies from 0.5 to 70 Hz [28]. High-pass filters (0.25-0.5 Hz or time constant of 0.3 sec) eliminate low frequencies. Low-pass filters (70-120 Hz) eliminate high frequencies, such as muscle artefacts [55,56].
- Notch filters (50 Hz in Europe and 60 Hz in USA) should be added and retrieved during reading [6,29].
- Adjustable speed (15 mm/sec-30 mm/sec) can help to diagnose asymmetry or asynchrony.
- Montages: various types of montages are used. The best montages in clinical practice, which use 11 electrodes, are longitudinal and transverse (Figures 2) [5,28,29,31,40,45]. Longitudinal montages enable the highlighting of features in phase opposition in temporal or Rolandic position, such as PPR. Transverse montages enable easier comparison of homologous areas to check for the asymmetry of activity. Monopolar montages (reference or average montages) using a small number of electrodes should not be used. Such monopolar montages may reintroduce signals of very high-amplitude features (theta temporal and slow-wave activity (TTA-SW) or delta brush) to other electrodes, as such high-amplitude signals cannot be minimized by the average of the electrodes.

### ***Interpretation guidelines***

In addition to the information included in the request form, information given by the technician during the recording must be first considered:

- *Conditions of the recording*: position of the newborn, notably the position of the head, description of skull and scalp lesion topography, current medications (doses

and timing of drug therapy), type of respiratory support, SaO<sub>2</sub>/pCO<sub>2</sub>, infant's temperature, presence of intravenous line(s), technical difficulties.

- *Events before and during the recording*: infant behavior during electrode placement (reactivity), as well as during the recording (reactivity to sensorial stimulation, spontaneous eye and body movement, eyes opened or closed), environment (walking in the room, medical and nursing care, etc.), artefact correction, impedance adjustment, etc.

Interpretation of the EEG is carried out in successive steps [6,26,31,43] :

### ***Global analysis of the EEG background***

In the first step, a global analysis of the entire acquired EEG is performed. This overview allows an assessment of:

- the technical quality of the EEG
- global lability and confirmation of the presence of vigilance states related to gestational age
- continuity, if the minimal and maximal duration of the discontinuous active periods (burst of activity) and maximal duration of the quiescent periods (interburst intervals: IBI) are measured
- the global spatio-temporal organization, as well as interhemispheric symmetry and synchrony
- the global amplitude

### ***Identification (analysis) of each differentiated stage on the tracing***

In the second step, EEG characteristics and polygraphic parameters (respiration and cardiac rates and ocular movements, facial mimics, sucking, limb movements, etc.) are analyzed to identify each vigilance state.

### ***Analysis of the EEG features***

In the third step, all normal (specific age-related features) [5,10,30] and abnormal EEG patterns (disorganized or dysmature patterns, positive or negative spikes) [7–9,17,33,35,35,51,57] are assessed for each vigilance state:

- Morphology
- Frequency
- Amplitude

- Spatial organization (localization and distribution (symmetry))
- Synchrony or not
- Density (number per minute)
- Dynamics: isolated or repeated in brief sequences

### ***Description of ictal EEG discharges***

If EEG seizures are observed, they are described:

- Morphology, location, frequency, and spatio-temporal dynamics of ictal features
- Duration of seizures and number and, seizure burden for EEG monitoring
- Correlation with the clinical behavior on the synchronized video
- Response to drug administration

### ***Provoked reactivity***

The EEG reactivity after sensorial stimulation in the different vigilance states is evaluated.

### ***Description of artefacts***

See below.

### ***Specificity of monitoring interpretation***

The modalities of interpreting EEG monitoring are the same as those for standard EEG. The interpretation of EEG monitoring is time-consuming. Quantitative EEG plots have thus been developed, such as color density spectral arrays (DSAs) or amplitude-integrated electroencephalography (aEEG), to help neurophysiologists and neonatologists to analyze the EEG activity [11,21,27,50]. The DSA is a quantitative EEG plot that applies fast-Fourier transformation to convert raw EEG data into a time-compressed and color-coded display, whereas aEEG displays conventional EEG data in a rectified semi-logarithmic, time-compressed scale. DSAs and aEEG must be considered solely as interpretation aids, notably for the evaluation of cyclicity and seizure quantification. Due to the high rate of misinterpretation (false negatives and false positives), they must not be considered without simultaneous conventional EEG, which is still the gold standard of cerebral brain evaluation [19,31,39,41,44–46].

### ***Reporting guidelines [6,43]***



The EEG report should provide a minimum of information about the newborn: the name, date of birth, gestational age at birth, and gestational post-menstrual age at recording.

The report should be divided into three parts:

- The report must begin by a summary of the conditions of the recording (medications received by the newborn, technical difficulties, total recording time)
- Second, all EEG patterns (normal and abnormal) for each successive vigilance state must be objectively described in detail (c.f. integration guidelines)
- Third, EEG patterns are interpreted according to gestational age. Their normality with respect to gestational age must be described. Abnormal features must be described and quantified. The EEG activity must be compared to former recordings if available. The correlation of EEG patterns with the clinical history should be discussed (confirmation or overturning of the clinical suspicion of seizures, abnormal EEG features of intraventricular hemorrhage or periventricular leukomalacia, etc.). Their diagnostic and prognostic value must be precise. The need and timing for follow-up must be proposed.

## **Artefact identification**

This paragraph is adapted from Walls-Esquivel E et al., 2007 and Wallois et al., 2007 which clearly described artefact detection in premature babies [55,56].

Artefact identification is a critical step in EEG acquisition and interpretation and can be more difficult in neonates than for adults. For adults, artefacts are generally of higher amplitude and lower frequency than those of background activity and can be easily visually identified. In premature infants, EEG activity is more variable and of higher amplitude. Artefacts can be difficult to identify because they have patterns similar to physiological EEG features. Many authors have highlighted the need to develop specific tools for artefact rejection to correctly monitor newborn cerebral activity before using automatic seizure detection methods at this [13]. Various tools for artefact detection have thus been developed for newborns, in particular using neural networks and methods of independent component analysis [1,2]. Nevertheless, the ability to visually detect artefacts is essential in routine practice.

The objective of this section is to highlight the principle artefacts observed in clinical practice, present their biological, technical, or environmental origin, and propose solutions to reduce their presence on EEG recordings and/or their impact on EEG interpretation.

## ***Technical artefacts***

### ***Mains electricity noise [55,56] (Figure 3)***

Mains electricity noise (Figure 3) is characterized by a continuous added frequency coming from the power supply (50 Hz in Europe and 60 Hz in the USA) observed for one or more channels. They are frequently filterable by traditional filters generally dampened to  $-3$  dB. Nevertheless, the artefact signal is not always completely removed, even with a high-quality filter, and harmonics of 50 Hz (100-200 Hz) or 60 Hz (120-240 Hz) may persist. Noise of 50 Hz may also be highly attenuated in a bipolar montage (cancelling of noise contained in both signals). Major noise can also be observed for electrodes recording cardiac and respiratory activity.

Mains electricity noise is often the result of a poor contact and/or high impedances between the skin and an electrode. If this contact concerns the grounding electrode, all EEG channels will be overloaded with major artefacts. Moreover, the NICU is a hostile environment for EEG recordings. Newborn infants are often placed in incubators, of which the base is filled with a metallic heating element, requiring temperature probes. The infants often require invasive or non-invasive ventilation support. In addition, they benefit from cardiac and respiratory monitoring, and intravenous treatments require the use of electric syringes. Such monitoring systems and electric syringes, even those that are Class 2, can have defects and induce a low amplitude alternating current signal on the ground electrode.

It may be necessary to disconnect one or more systems to reduce the major noise artefacts. Setting electric syringes to battery power is sometimes sufficient. Disconnecting the temperature probe can also efficiently suppress noise artefacts. When an EEG channel is disturbed by such an artefact, one should check that the EEG cables are not in contact with a perfusion catheter. Indeed, the saline solution contained in perfusions is highly conductive and easily propagates noise. Sometimes it is necessary to improve the connection with the ground by using a second ground electrode.

### ***Electrode artefacts [55,56] (Figures 4-5-6-7)***

Electrode artefacts consist of various types of transient artefacts. They can appear as theta activity with a rectangular morphology or as negative slow spikes followed by a slow wave (Figure 4). They are generally of high amplitude and short duration (less than 500 ms). They can also appear as very rapid activity (electrode jitter) (Figure 5). Furthermore, they can be associated with reinforcement of the 50- (60-) Hz power supply artefacts. Transient electrode

artefacts can sometimes show a repetitive aspect (Figures 5-6-7), with more or less regular intervals of one or a few seconds. It may be difficult to distinguish them from seizures (Figures 6-7).

They can also be related to a defective skin electrode contact. The pressure between skin and electrode should thus be kept constant and should not be too high, as this can generate a pulsing phenomenon, which can perturb the signal. This type of activity requires the eye of a trained technician. Only observation during recording makes it possible to check and immediately restore a good contact between electrode and skin.

### ***Artefacts of biological origin***

#### ***Muscular artefacts [55,56] (Figure 8)***

The frequency of muscular artefacts is high (above 50 Hz) and spreads over a broader range than the main artefacts. They are often symmetrical and synchronous, as they result from muscle activity subjacent to EEG electrodes on the frontal (closing or opening of the eyes) and temporal muscles (Figure 8). However, they can be asymmetrical, and observed only on one side. They are often associated with body movement artefacts.

Muscular artefacts cannot be completely removed by a standard main filter. Moreover, the use of filters may modify the shape of such artefacts and thus create false EEG features. They can be slightly attenuated in the bipolar assembly. In certain cases, it may be necessary to use a neuro-muscular blocking agent to confirm the muscular origin of certain activities. This may be particularly important to confirm an inactive EEG.

#### ***Baby movement artefacts [55,56] (Figure 8)***

Baby movement artefacts consist of high amplitude slow waves over one or more channels (Figure 8), frequently associated with muscular artefacts. They can also appear as rhythmic activity. EMG and/or ECG electrodes can also help to identify such artefacts. Synchronized video is essential to confirm the correlation between baby movements and artefacts and thus distinguish them from EEG activity.

#### ***Eye movement artefacts [55,56] (Figure 9)***

Eye movement generates an electric field that moves in space, which is likely to disturb recordings in the frontal areas. These artefacts are recorded on frontal derivations. They are characterized by transient high-amplitude often synchronous delta or theta activities (Figure

9). It may be difficult to distinguish them from frontal EEG activity, notably transient (“encoches frontales”) (Figure 9), if they have an immature aspect (33-36 wGA) [5,10]. Video and/or bedside monitoring helps to easily identify them.

#### ***Sucking artefacts [55,56] (Figure 10)***

Non-nutritive sucking is observed as soon as 24 wGA. Sucking and swallowing actions are coordinated at 35 to 40 wGA. Sucking artefacts are frequent in sleep at all stages. They are composed of fast rhythms of muscular origin superimposed on slow theta—delta waves (Figure 10A, 10B). Nevertheless, muscular activities are sometimes replaced by very angular, possibly rhythmic, activities. They occur mostly at temporal areas and are often bilateral, even if the amplitude can be marked on one side. Sucking can be associated with head movements (Figure 10C). Slow delta waves, synchronous with movements, can be observed. Video and/or bedside monitoring helps to easily identify them.

#### ***Cardiac artefacts [55,56] (Figure 11)***

Cardiac artefacts are characterized by transient monotonous, regular activity. They often have the same pattern as cardiac activity but can also appear as spikes (Figure 11A). A cardiac artefact is generally recorded on only one channel but can also be recorded by several electrodes. Sometimes, inactive EEGs exhibit these artefacts on almost all channels, which is almost always a poor prognosis. This type of artefact is synchronous or a few milliseconds out of phase with the ECG signal itself, but with a stable phase difference. They differ from seizures by their regular rhythm, without a temporo-spatial evolution (Figure 11B).

Increasing the ECG channel amplitude can enable the visualization of this superimposition (Figure 11). It may be useful to check whether an artery is near an electrode and then move the sensor. Sometimes slackening the tension between the sensor and skin is sufficient.

#### ***Respiratory artefacts [55,56] (Figures 12-13-14-15)***

Respiratory artefacts appear as more or less regular slow delta waves on one or more channels (Figures 12, 13A). These artefacts do not always present the same pattern as the respiratory signal. They may be intermingled with background EEG activities and may be more polymorphic than the respiratory signal itself. Respiratory gasps can also appear as slow spikes (Figures 15A, 15B). Respiration can sometimes imitate a critical sequence in a premature infant (Figures 13B, 14). The temporo-spatial organization of the periodic activity

must guide the analysis. In preterm newborns, electrographic seizures are characterized by sudden repetitive evolving stereotyped waveforms with a beginning and an end [59]. Sometimes, the paroxysmal activity shows spatial evolution, gradually increasing the number of EEG channels involved from the beginning to the end of the seizure. In respiratory artefacts, evolution from one frequency and amplitude to another associated with spatial diffusion is infrequently observed. Nevertheless, seizure discharges may have the same frequency as respiratory movements in premature newborns due to the immaturity of the cardio-respiratory center (Figures 13B, 14). In this situation, it becomes difficult to distinguish between respiratory artefacts and pathological discharges.

Recording the respiratory signal is essential at this developmental period. As for cardiac artefacts, increasing the amplitude of the respiratory signal enables visualization of the superposition of respiratory activity and respiratory artefacts.

#### ***Hiccup artefacts [55,56] (Figure 15).***

Hiccup artefacts can be isolated; they often come in series and often have a repetitive, rhythmic aspect (Figure 15). These can induce significant alterations in the EEG signal. They occur simultaneously on the respiratory channels, where their amplitude varies widely, depending on where the respiratory sensor is placed.

#### ***Environmental artefacts (Figure 16)***

Any movement in the room (walking, manipulations around the incubator, changes in perfusion, etc.) in which the acquisition of the EEG takes place can be a source of artefacts. These artefacts can show highly variable morphology and localization. They can be rhythmic or not, are often of low frequency, and are sometimes difficult to identify without help from the technician. It is necessary to be particularly vigilant in the presence of such artefacts in the event of a poor or inactive trace (Figure 16A).

Caring for newborns can also induce artefacts. Among them, rocking entails monomorphic, smooth, theta-frequency artefacts, usually affecting all derivations (Figure 16B). They can sometimes be more acute or irregular and are likely to be considered seizures (Figure 16C). Synchronized video makes it easy to identify the origin of such artefacts.

The best way to avoid such artefacts is to avoid non-emergency care during EEG acquisition. This requires perfect collaboration between the technician teams and the nurses.

## Conclusion

EEG is an essential tool for assessing brain function during the neonatal period. They must be carried out in compliance with technical constraints to ensure the quality of the acquisition and the safety of fragile premature and term newborns. These specificities must be considered during the purchase of a system. The procedures for recording and interpreting EEGs require well-trained technicians, as well as neurophysiologists specialized in children and newborns.

## Acknowledgement

Special thanks to Ms Chloé Lepape, EEG technician of Port-Royal Hospital center, Paris for her precise and didactic video and to Dr Claire Héberlé for the English translation. Thanks to the EEG technicians of the Pediatric Neurophysiology unit of Amiens-Picardie University Hospital for the images of EEG electrodes, headcap, and annex records.

## Conflict of interest

The authors disclose no conflict of interest related to this work.

## References

- [1] Aarabi A, Grebe R, Wallois F. A multistage knowledge-based system for EEG seizure detection in newborn infants. *Clin Neurophysiol* 2007;118: 2781–97.
- [2] Aarabi A, Wallois F, Grebe R. Automated neonatal seizure detection: a multistage classification system through feature selection based on relevance and redundancy analysis. *Clin Neurophysiol* 2006;117: 328–40.
- [3] Alix JJP, Ponnusamy A, Pilling E, Hart AR. An introduction to neonatal EEG. *Paediatrics and Child Health* 2017;27: 135–42.
- [4] Als H, Duffy FH, McAnulty GB, Rivkin MJ, Vajapeyam S, Mulkern RV, et al. Early experience alters brain function and structure. *Pediatrics* 2004;113: 846–57.
- [5] André M, Lamblin M-D, d’Allest AM, Curzi-Dascalova L, Moussalli-Salefranque F, S Nguyen The T, et al. Electroencephalography in premature and full-term infants. Developmental features and glossary. *Neurophysiol Clin* 2010;40: 59–124.
- [6] André-Obadia N, Sauleau P, Cheliout-Heraut F, Convers P, Debs R, Eisermann M, et al. French guidelines on electroencephalogram. *Neurophysiol Clin* 2014;44: 515–612.
- [7] Baud O, d’Allest AM, Lacaze-Masmonteil T, Zupan V, Nedelcoux H, Boithias C, et al. The early diagnosis of periventricular leukomalacia in premature infants with positive rolandic sharp waves on serial electroencephalography. *J Pediatr* 1998;132: 813–7.

- [8] Biagioni E, Bartalena L, Biver P, Pieri R, Cioni G. Electroencephalographic dysmaturity in preterm infants: a prognostic tool in the early postnatal period. *Neuropediatrics* 1996;27: 311–6.
- [9] Biagioni E, Bartalena L, Boldrini A, Cioni G, Giancola S, Ipata AE. Background EEG activity in preterm infants: correlation of outcome with selected maturational features. *Electroencephalogr Clin Neurophysiol* 1994;91: 154–62.
- [10] Bourel-Ponchel E, Gueden S, Hasaerts D, Heberle C, Malfilâtre G, Mony L et al. Normal EEG during the neonatal period: maturational aspects from premature to full-term newborns. *Clinical neurophysiol* in press.
- [11] Burdjalov VF, Baumgart S, Spitzer AR. Cerebral function monitoring: a new scoring system for the evaluation of brain maturation in neonates. *Pediatrics* 2003;112: 855–61.
- [12] Curzi-Dascalova L, Mirmiran M. Manuel des techniques d'enregistrement et d'analyse des stades de sommeil et de veille chez le prématuré et le nouveau-né à terme. 1996.
- [13] Faul S, Boylan G, Connolly S, Marnane L, Lightbody G. An evaluation of automated neonatal seizure detection methods. *Clin Neurophysiol* 2005;116: 1533–41.
- [14] Glass HC, Shellhaas RA, Tsuchida TN, Chang T, Wusthoff CJ, Chu CJ, et al. Seizures in Preterm Neonates: A Multicenter Observational Cohort Study. *Pediatr Neurol* 2017;72: 19-24.
- [15] Griffiths N, Spence K, Loughran-Fowlds A, Westrup B. Individualised developmental care for babies and parents in the NICU: Evidence-based best practice guideline recommendations. *Early Hum Dev* 2019;139: 104840.
- [16] Guerit J-M. Clinical neurophysiology in neonatology. *Neurophysiol Clin* 2013;43: 265–6.
- [17] Hayakawa F, Okumura A, Kato T, Kuno K, Watanabe K. Disorganized patterns: chronic-stage EEG abnormality of the late neonatal period following severely depressed EEG activities in early preterm infants. *Neuropediatrics* 1997;28: 272–5.
- [18] Hayashi-Kurahashi N, Kidokoro H, Kubota T, Maruyama K, Kato Y, Kato T, et al. EEG for predicting early neurodevelopment in preterm infants: an observational cohort study. *Pediatrics* 2012;130: e891-7.
- [19] Hellström-Westas L. Continuous electroencephalography monitoring of the preterm infant. *Clin Perinatol* 2006;33: 633–47.
- [20] Hellström-Westas L, Rosén I. Electroencephalography and brain damage in preterm infants. *Early Hum Dev* 2005;81: 255–61.
- [21] Hellström-Westas L, Rosén I, Svenningsen NW. Cerebral function monitoring during the first week of life in extremely small low birthweight (ESLBW) infants. *Neuropediatrics* 1991;22: 27–32.
- [22] Husain AM. Review of Neonatal EEG. *American Journal of Electroneurodiagnostic Technology* 2005;45: 12–35.

- [23] Janáčková S, Boyd S, Yozawitz E, Tsuchida T, Lamblin M-D, Gueden S, et al. Electroencephalographic characteristics of epileptic seizures in preterm neonates. *Clin Neurophysiol* 2016;127: 2721–7.
- [24] Jarrar R, Buchhalter J, Williams K, McKay M, Luketich C. Technical tips: Electrode safety in pediatric prolonged EEG recordings. *Am J Electroneurodiagnostic Technol* 2011;51: 114–7.
- [25] Kaminska A, Cheliout-Heraut F, Eisermann M, Touzery de Villepin A, Lamblin MD. EEG in children, in the laboratory or at the patient's bedside. *Neurophysiol Clin* 2015;45: 65–74.
- [26] Koszer SE, Moshé SL, Holmes GL. Visual Analysis of the Neonatal. In *Clinical Neurophysiology of Infancy, Childhood, and Adolescence*. Elsevier Inc. 2006. 70-86.
- [27] Kuhle S, Klebermass K, Olischar M, Hulek M, Prusa AR, Kohlhauser C, et al. Sleep-wake cycles in preterm infants below 30 weeks of gestational age. Preliminary results of a prospective amplitude-integrated EEG study. *Wien Klin Wochenschr* 2001;113: 219–23.
- [28] Kuratani J, Pearl PL, Sullivan LR, Riel-Romero RMS, Cheek J, Stecker MM, et al. American Clinical Neurophysiology Society Guideline 5: Minimum Technical Standards for Pediatric Electroencephalography. *Neurodiagn J* 2016;56: 266–75.
- [29] Lamblin MD, André M, Auzoux M, Bednarek N, Bour F, Charollais A, et al. [Indications of electroencephalogram in the newborn]. *Arch Pediatr* 2004;11: 829–33.
- [30] Lamblin MD, André M, Challamel MJ, Curzi-Dascalova L, d'Allest AM, De Giovanni E, et al. [Electroencephalography of the premature and term newborn. Maturational aspects and glossary]. *Neurophysiol Clin* 1999;29: 123–219.
- [31] Lamblin MD, de Villepin-Touzery A. EEG in the neonatal unit. *Neurophysiol Clin* 2015;45: 87–95.
- [32] Le Bihannic A, Beauvais K, Busnel A, de Barace C, Furby A. Prognostic value of EEG in very premature newborns. *Arch Dis Child Fetal Neonatal Ed* 2012;97: F106-9.
- [33] Marret S, Parain D, Ménard JF, Blanc T, Devaux AM, Ensel P, et al. Prognostic value of neonatal electroencephalography in premature newborns less than 33 weeks of gestational age. *Electroencephalogr Clin Neurophysiol* 1997;102: 178–85.
- [34] Netherton BL, Stecker MM, Patterson T. Mechanisms of electrode induced injury. Part 3: practical concepts and avoidance. *Am J Electroneurodiagnostic Technol* 2007;47: 257–63.
- [35] Okumura A, Hayakawa F, Kato T, Kuno K, Watanabe K. Positive rolandic sharp waves in preterm infants with periventricular leukomalacia: their relation to background electroencephalographic abnormalities. *Neuropediatrics* 1999;30: 278–82.
- [36] Patterson T, Stecker MM, Netherton BL. Mechanisms of electrode induced injury. Part 2: Clinical experience. *Am J Electroneurodiagnostic Technol* 2007;47: 93–113.



- [37] Pavlidis E, Lloyd RO, Boylan GB. EEG - A Valuable Biomarker of Brain Injury in Preterm Infants. *Dev Neurosci* 2017;39: 23–35.
- [38] Périvier M, Rozé J-C, Gascoin G, Hanf M, Branger B, Rouger V, et al. Neonatal EEG and neurodevelopmental outcome in preterm infants born before 32 weeks. *Arch Dis Child Fetal Neonatal Ed* 2016;101: F253-9.
- [39] Rennie JM, Chorley G, Boylan GB, Pressler R, Nguyen Y, Hooper R. Non-expert use of the cerebral function monitor for neonatal seizure detection. *Arch Dis Child Fetal Neonatal Ed* 2004;89: F37-40.
- [40] Samson-Dollfus D. *Électro-encéphalographie de l'enfant*. Elsevier Masson; 2001.
- [41] Shah DK, Mackay MT, Lavery S, Watson S, Harvey AS, Zempel J, et al. Accuracy of bedside electroencephalographic monitoring in comparison with simultaneous continuous conventional electroencephalography for seizure detection in term infants. *Pediatrics* 2008;121: 1146–54.
- [42] Shannon C, Weaver W. *The Mathematical Theory of Communication*. The university of Illinois. Urbana. 1964.
- [43] Shany E, Berger I. Neonatal electroencephalography: review of a practical approach. *J Child Neurol* 2011;26: 341–55.
- [44] Shellhaas RA. Continuous Electroencephalography Monitoring in Neonates. *Curr Neurol Neurosci Rep* 2012;12: 429–35.
- [45] Shellhaas RA, Chang T, Tsuchida T, Scher MS, Riviello JJ, Abend NS, et al. The American Clinical Neurophysiology Society's Guideline on Continuous Electroencephalography Monitoring in Neonates. *J Clin Neurophysiol* 2011;28: 611–7.
- [46] Shellhaas RA, Soaita AI, Clancy RR. Sensitivity of amplitude-integrated electroencephalography for neonatal seizure detection. *Pediatrics* 2007;120: 770–7.
- [47] Sinha SR, Sullivan LR, Sabau D, Orta DSJ, Dombrowski KE, Halford JJ, et al. American Clinical Neurophysiology Society Guideline 1: Minimum Technical Requirements for Performing Clinical Electroencephalography. *Neurodiagn J* 2016;56: 235–44.
- [48] Stecker MM, Patterson T, Netherton BL. Mechanisms of electrode induced injury. Part 1: theory. *Am J Electroneurodiagnostic Technol* 2006;46: 315–42.
- [49] Tallgren P, Vanhatalo S, Kaila K, Voipio J. Evaluation of commercially available electrodes and gels for recording of slow EEG potentials. *Clinical Neurophysiology* 2005;116: 799–806.
- [50] Tao JD, Mathur AM. Using amplitude-integrated EEG in neonatal intensive care. 2010 *J Perinatol* 2010;30: S73-81.
- [51] Tich SNT, d'Allest AM, Villepin AT de, de Belliscize J, Walls-Esquivel E, Salefranque F, et al. Pathological features of neonatal EEG in preterm babies born before 30 weeks of gestationnal age. *Neurophysiol Clin* 2007;37: 325–70.

- [52] Toet MC, van der Meij W, de Vries LS, Uiterwaal CSPM, van Huffelen KC. Comparison between simultaneously recorded amplitude integrated electroencephalogram (cerebral function monitor) and standard electroencephalogram in neonates. *Pediatrics* 2002;109: 772–9.
- [53] Vanhatalo S, Tallgren P, Andersson S, Sainio K, Voipio J, Kaila K. DC-EEG discloses prominent, very slow activity patterns during sleep in preterm infants. *Clin Neurophysiol* 2002;113: 1822–5.
- [54] Vermeulen RJ, Sie LTL, Jonkman EJ, Strijers RLM, Lafeber HN, Uitdehaag BMJ, et al. Predictive value of EEG in neonates with periventricular leukomalacia. *Dev Med Child Neurol* 2003;45: 586–90.
- [55] Wallois F, Vecchierini M-F, Héberlé C, Walls-Esquivel E. [Electroencephalography (EEG) recording techniques and artifact detection in early premature babies]. *Neurophysiol Clin* 2007;37: 149–61.
- [56] Walls-Esquivel E, Vecchierini MF, Héberlé C, Wallois F. Electroencephalography (EEG) recording techniques and artefact detection in early premature babies. *Neurophysiol Clin* 2007;37: 299–309.
- [57] Watanabe K, Hayakawa F, Okumura A. Neonatal EEG: a powerful tool in the assessment of brain damage in preterm infants. *Brain Dev* 1999;21: 361–72.
- [58] Jasper, H.H. The ten twenty system of the International Federation. *Electroencephalography and Clinical Neurophysiology* 1958;10: 371375.
- [59] Neonatal Seizure Classification. International League Against Epilepsy. Available at: <https://www.ilae.org/guidelines/definition-and-classification/neonatal-seizure-classification>. Accessed September 4, 2020.

## **Legends**

### **Figure 1. EEG electrodes, headcap, and annex records**

**1A.** Neonatal EEG requires 11 Ag-AgCl electrodes (1), with at least a thoracic strain gauge for respiratory movements (2), and two electrodes (one active, one passive) for ECG (3). Electrodes for Ocular movements (OCG), muscle activity (EMG), and the measure of oximetry saturation (SaO<sub>2</sub>) (4) can complete the recording of the EEG.

**1B.** The 11 electrodes are positioned on the scalp according to the 10/20 system adapted for neonates.

**1C.** Integrated headcap EEG systems (19 electrodes) Head cap developed in Amiens-Picardie University Hospital in collaboration with Malterre enterprise ®.

### **Figure 2. Longitudinal (A) and transverse (B) bipolar montages**

### **Figure 3. Mains electricity noise artefact**

Mains electricity noise artefact observed for FP2-C4, Fp2-T4 derivations and ECG for a 27-wPMA premature newborn.

*Low-pass filter: 70 Hz, high-pass filter: 0.5 Hz, notch filter: 50 Hz*

### **Figure 4. Electrode artefacts and positive spikes**

**4A-B.** High amplitude electrode artefacts on the Fp1 (A) and C3 - C4 channels (B) for a 28-wPMA premature infant.

**4C.** Positive Rolandic spike and wave (PRSW) for C3 electrodes (Fp1-C3, C3-T3) (square) must be distinguished from an electrode artefact (premature infant recorded at 31 wPMA, intraventricular hemorrhage: grade 3 on the right, grade 4 on the left).

*Low-pass filter: 70 Hz, high-pass filter: 0.5 Hz, notch filter: 50 Hz*

### **Figure 5. Electrode jitter**

**5A.** C3 electrode artefact (leads Fp1-C3, C3-T3), initially characterized by rapid activity (jitter) (1), for which the frequency decreased to take on an alpha (2) and then theta angular frequency (3).

**5B.** Intervention of the technician (4), who corrected the artefact but awakened the child (muscular and movement artefacts).

*Low-pass filter: 70 Hz, high-pass filter: 0.5 Hz, notch filter: 50 Hz*

**Figure 6. Theta angular electrode artefacts in a term newborn**

**6A.** Artefact of the Cz electrode (leads Fz-Cz, Cz-Pz) showing a rhythmic aspect that is difficult to differentiate from an ictal event. Sucking artefact in left and right temporal electrodes (star).

**6B.** Persistence of the artefact for the Cz electrode for the same premature newborn showing an angular theta aspect.

*Low-pass filter: 70 Hz, high-pass filter: 0.5 Hz, notch filter: 50 Hz*

**Figure 7. Repetitive electrode artefacts (premature newborn at 34 wPMA)**

Electrode artefacts appear as rhythmic activity for the FP1 electrode (leads Fp1-C3, Fp1-T3). The frequency of the artefact changes over time, mimicking ictal activity. The angular morphology of the theta activity, as well as the absence of spatial diffusion over time, help to distinguish them from a seizure. Nevertheless, verification of the impedances and Fp1 electrode by the technician is essential.

*Low-pass filter: 70 Hz, high-pass filter: 0.5 Hz, notch filter: 50 Hz*

**Figure 8. Muscular and body movement artefacts**

**8A.** Muscular artefacts observed for the bilateral frontal areas (Fp1-C3, Fp1-T3, Fp2-C4, Fp2-T4) associated with body movements (on the left part) in a term newborn.

**8B.** More diffuse muscular and body movements artefacts and sucking artefacts (star) of a 33-wPMA premature newborn.

*Low-pass filter: 70 Hz, high-pass filter: 0.5 Hz, notch filter: 50 Hz).*

**Figure 9. Eye movement artefacts and 'encoches frontales'**

**9A-B.** Bilateral high-amplitude frontal (Fp2-C4, Fp2-T4, Fz-Cz, Fp1-C3, Fp1-T3) delta activity induced by eye movements. \*: sucking artefact. §: electrode artefact of a 36-wPMA premature newborn.

**9C.** Synchronous bilateral frontal transients (*encoches frontales*) must not be confounded with eye-movement artefacts of a 35 wPMA premature newborn.

*Low-pass filter: 70 Hz, high-pass filter: 0.5 Hz, notch filter: 50 Hz)*

**Figure 10. Sucking artefacts**

**10A.** Unilateral right temporal (Fp2-T4, T4-O2) sucking artefacts (squares), showing aspects of angular delta-theta activity with spikes in a 38-wPMA premature newborn.

*Low-pass filter: 15 Hz, high-pass filter: 0.5 Hz, notch filter: 50 Hz*

**10B.** Bilateral right and left temporal sucking artefacts (squares) composed of fast rhythms of muscular origin superimposed on slow theta—delta waves for a 36-wPMA premature newborn.

*Low-pass filter: 70 Hz, high-pass filter: 0.5 Hz, notch filter: 50 Hz*

**10C.** Unilateral right temporal delta rhythmic activity due to head movements during sucking for a premature newborn lying down on the right side (36 wPMA).

*Low-pass filter: 70 Hz, high-pass filter: 0.5 Hz, notch filter: 50 Hz*

### **Figure 11. Cardiac artefacts and seizure**

**11A.** Monotonous, regular activity at the same rhythm as that of the ECG, appearing as spikes recorded on Fp2 channel (leads Fp2-T4, Fp2-T4) in a term newborn (40 wPMA).

**11B.** Critical sequence in a 26-wPMA premature infant. The temporo-spatial organization of the periodic activity must guide the analysis. The electrographic seizure is characterized by sudden repetitive evolving stereotyped waveforms with a spatial evolution marked by a gradual increase in the number of EEG channels involved from the beginning to the end of the seizure.

*Low-pass filter: 70 Hz, high-pass filter: 0.5 Hz, notch filter: 50 Hz*

### **Figure 12. Respiratory artefacts**

**12A.** Monotonous delta waves for the T4 channels (Fp2-T4, T4-O2) with the same rhythm as the respiratory rate for a 26-wPMA premature newborn.

**12B.** Monotonous angular theta waves for the O2 channels (C4-O2, T4-O2) with the same rhythm as the respiratory rate for a 27-wPMA premature newborn.

**12C.** High-frequency oscillations on the T3 channels (Fp1-T3, T3-O1) induced by high-frequency oscillation ventilation (abnormal activity recorded at 29 wPMA).

*Low-pass filter: 70 Hz, high-pass filter: 0.5 Hz, notch filter: 50 Hz*

### **Figure 13. Respiratory artefacts and seizures**

**13A.** Angular monotonous artefact with the same rhythm as the respiratory rate observed for the frontal channels in an inactive EEG.

**13B.** Seizure discharges may have the same morphology as respiratory artefacts (smooth slow delta waves). The increase in the frequency of the discharge allows distinguishing seizure discharges from respiratory artefacts. \*: electrode artefact. Isoelectric activity of the T3-O2 lead (27-wPMA premature newborn).

*Low-pass filter: 70 Hz, high-pass filter: 0.5 Hz, notch filter: 50 Hz*

#### **Figure 14. Seizures in a premature newborn (27 wPMA)**

Two focal slow delta rhythmic discharges that evolve in frequency and amplitude over time. Seizure discharges in premature newborns transitorily have the same frequency as respiratory movements due to the immaturity of cardio-respiratory center.

*Low-pass filter: 70 Hz, high-pass filter: 0.5 Hz, notch filter: 50 Hz*

#### **Figure 15. Gasps and hiccup artefacts**

**15A-B.** Gasp artefacts on an inactive EEG. Gasp artefacts appearing as diffuse (A) or more localized (B) theta angular activity, synchronous with respiratory movements.

**15C.** Hiccup artefacts characterized by repetitive, rhythmic low-voltage and high-frequency amplitude occurring simultaneously on the respiratory channels (33 wPMA).

*Low-pass filter: 70 Hz, high-pass filter: 0.5 Hz, notch filter: 50 Hz*

#### **Figure 16. Environmental artefacts**

**16A.** Low-amplitude artefacts induced by moving in the room on an inactive EEG (square) associated with diffuse ECG artefacts predominantly observed in the left hemisphere.

**16B.** Monomorphic, smooth, theta-frequency artefacts, under all derivations but predominantly observed on the C4 channels (Fp2-C4, C4-O2), induced by rocking (39 wPMA).

**16C.** Rocking can entail acute or irregular waves that can be wrongly considered to be seizures (40 wPMA).

*Low-pass filter: 70 Hz, high-pass filter: 0.5 Hz, notch filter: 50 Hz*

#### **Table 1. Polygraphic settings and EEG recording for the premature infant**

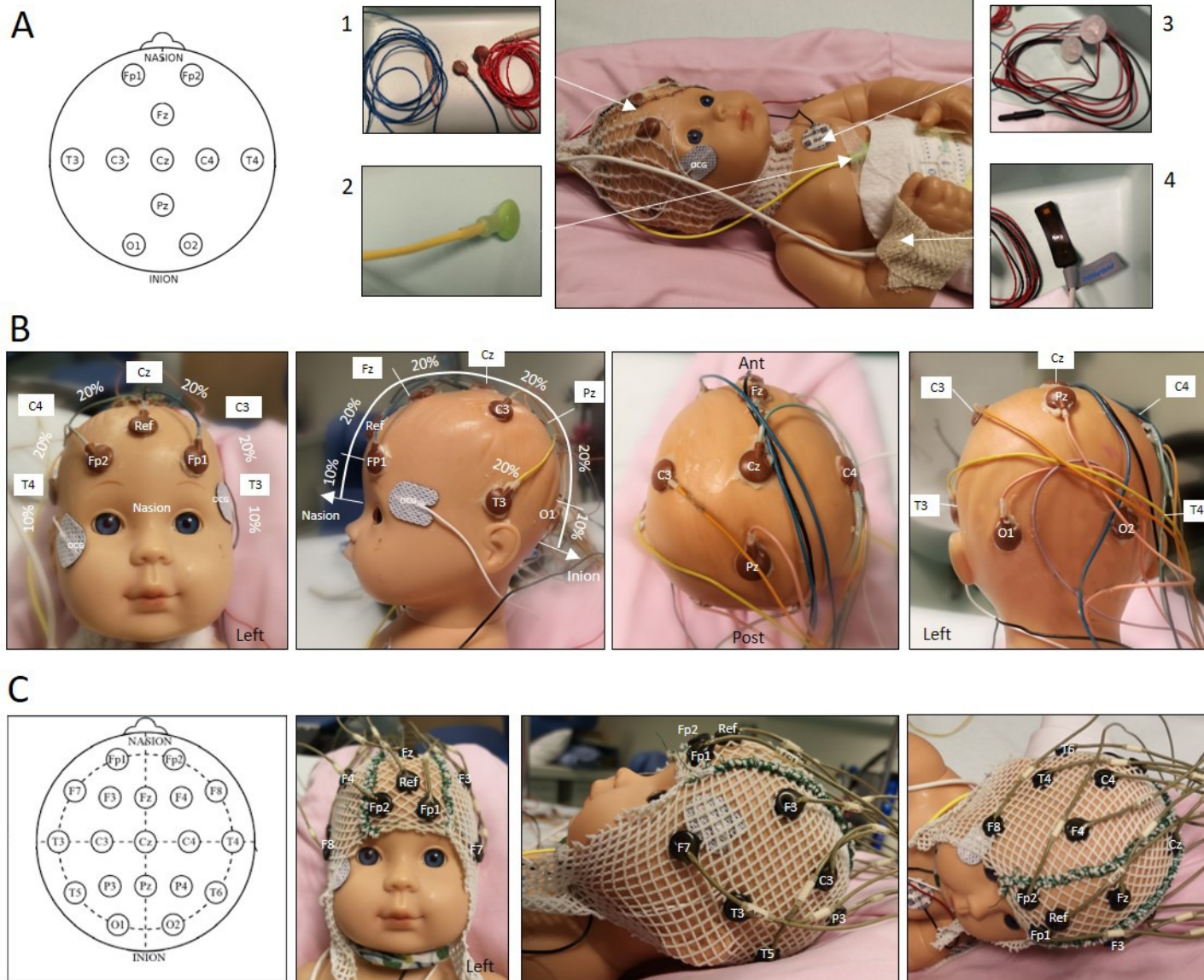
#### **Table 2. Proposal for an installation procedure that respects the rules of hygiene**

**Table 3: Risk factors for neurological complications**

**Table 4. Recommended EEG recording schedule according to gestational age and risk factors.**

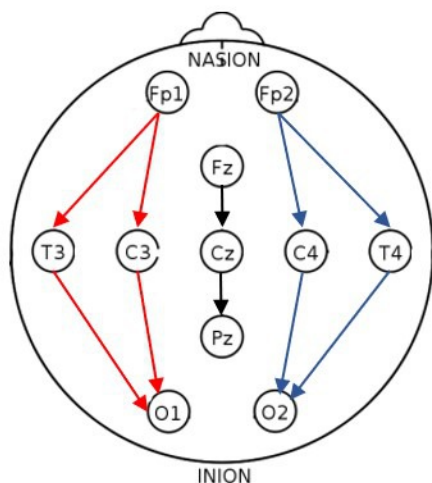
**Table 5. Paroxysmal clinical events suggesting seizures**

Figure 1



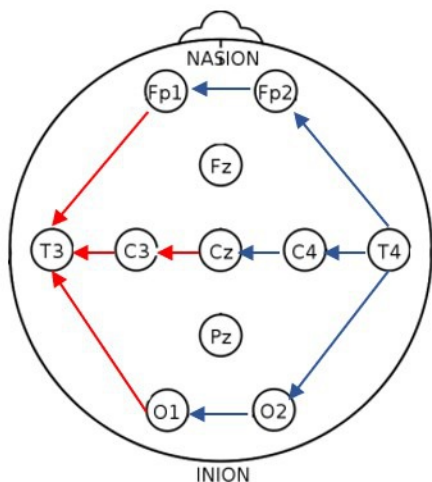


# A Longitudinal montage

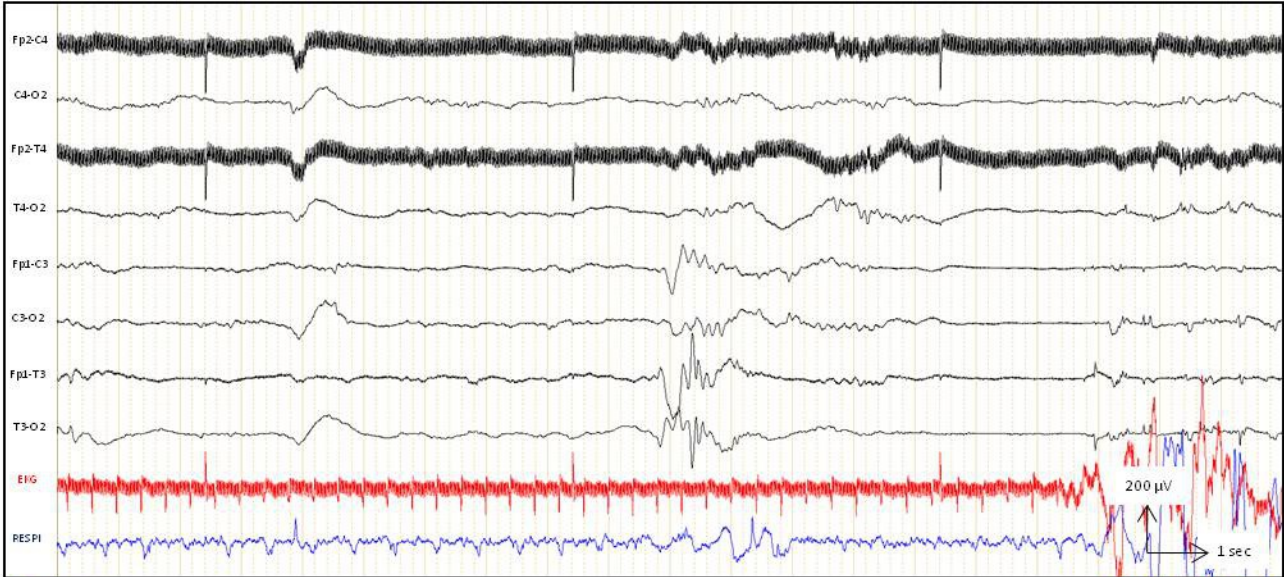


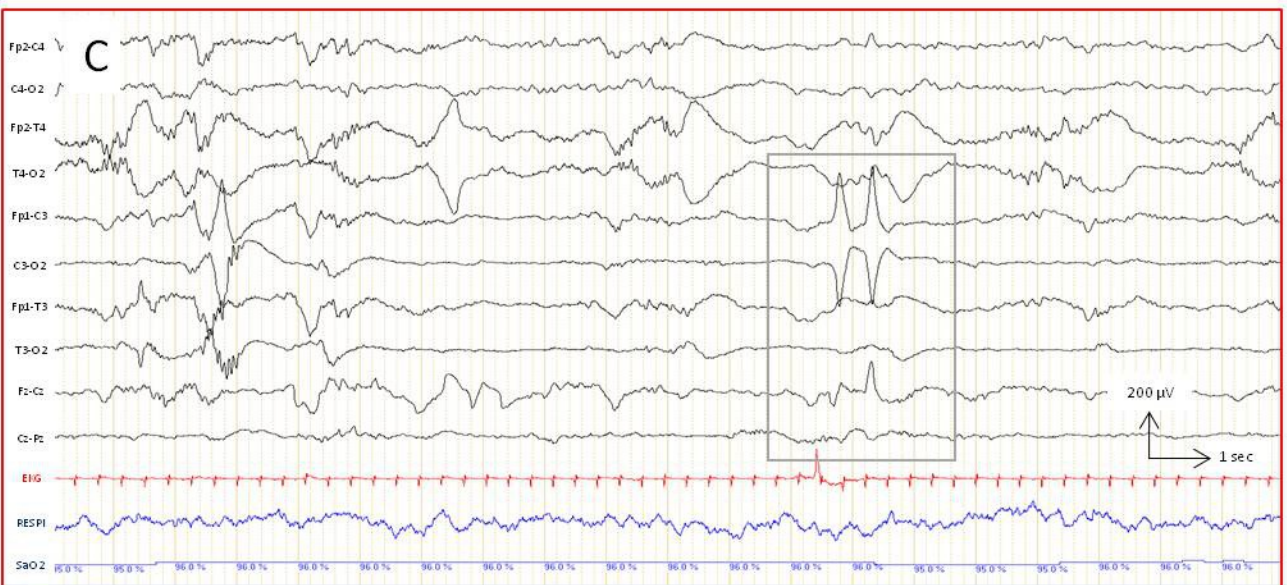
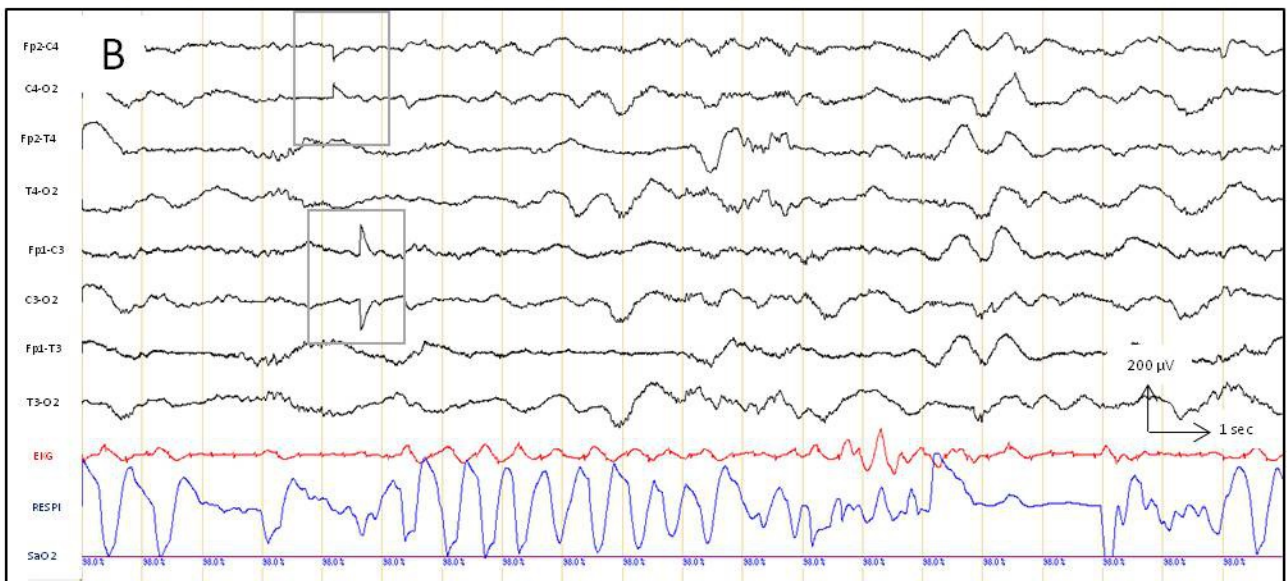
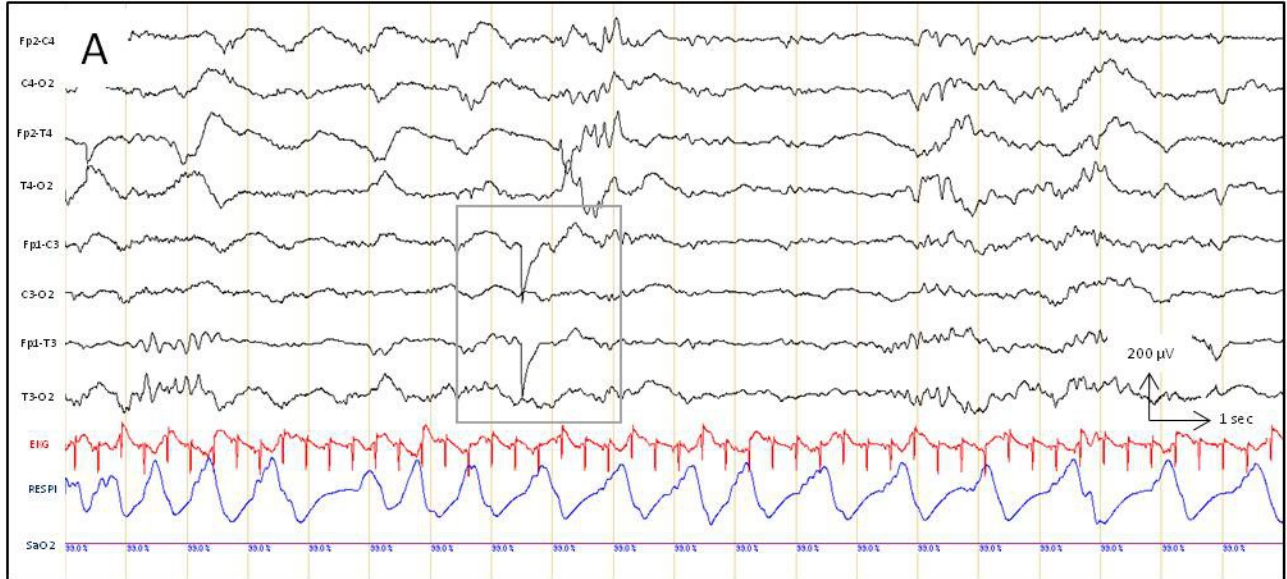
Channel	Lead
1	Fp2-C4
2	C4-O2
3	Fp2-T4
4	T4-O2
6	Fz-Cz
7	Cz-Pz
8	Fp1-C3
9	C3-O1
10	Fp1-T3
11	T3-O1

# B Transverse montage

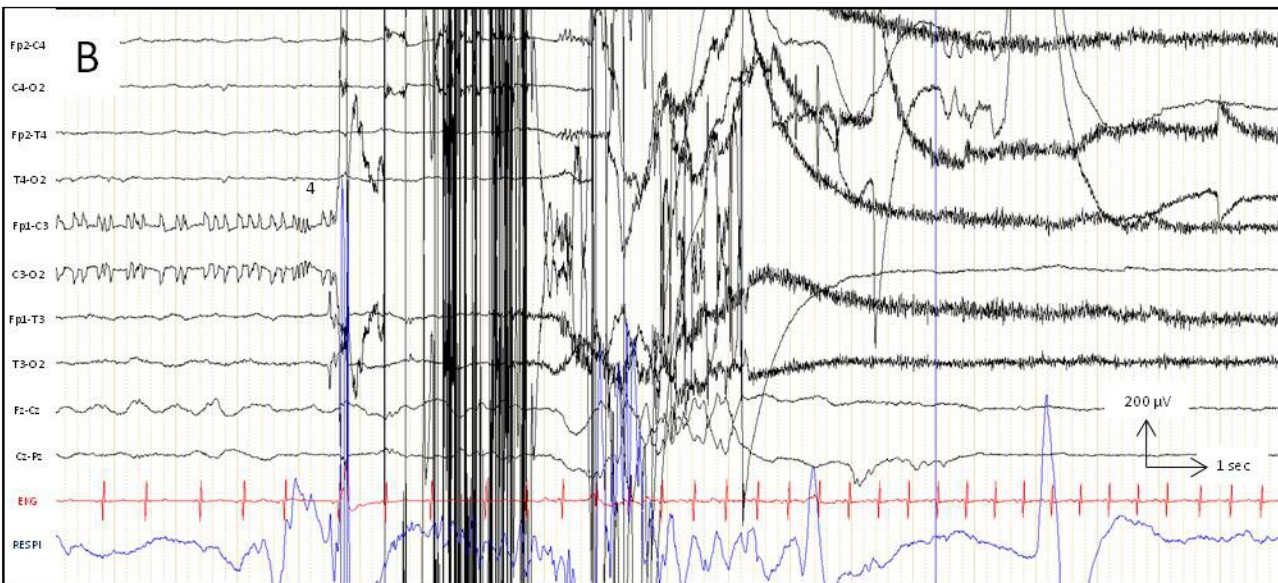
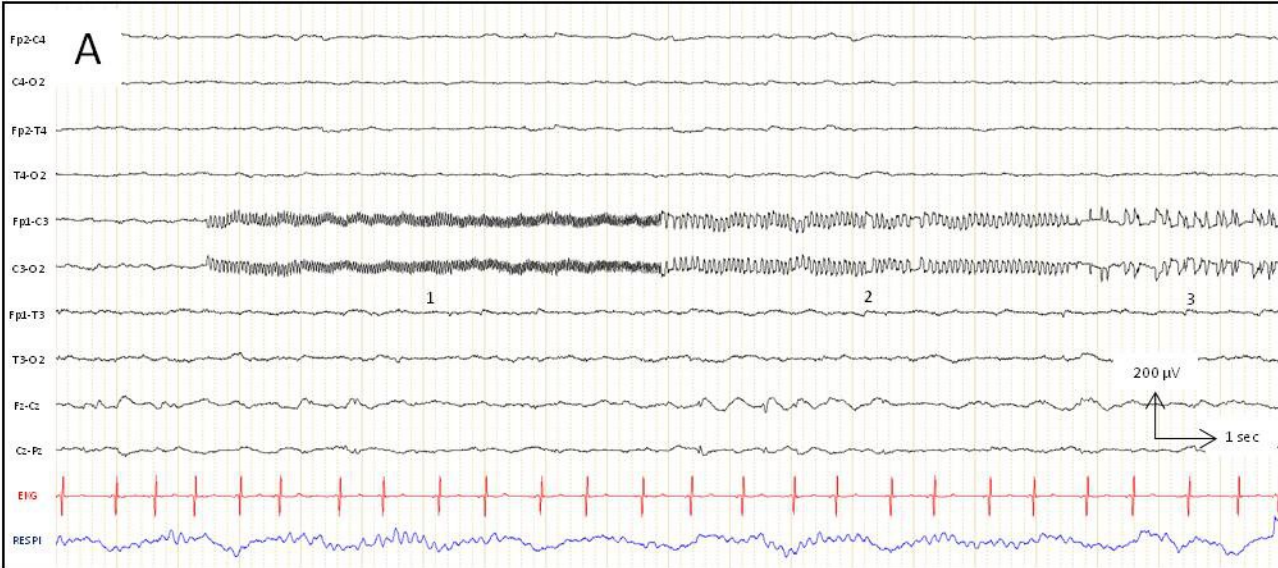


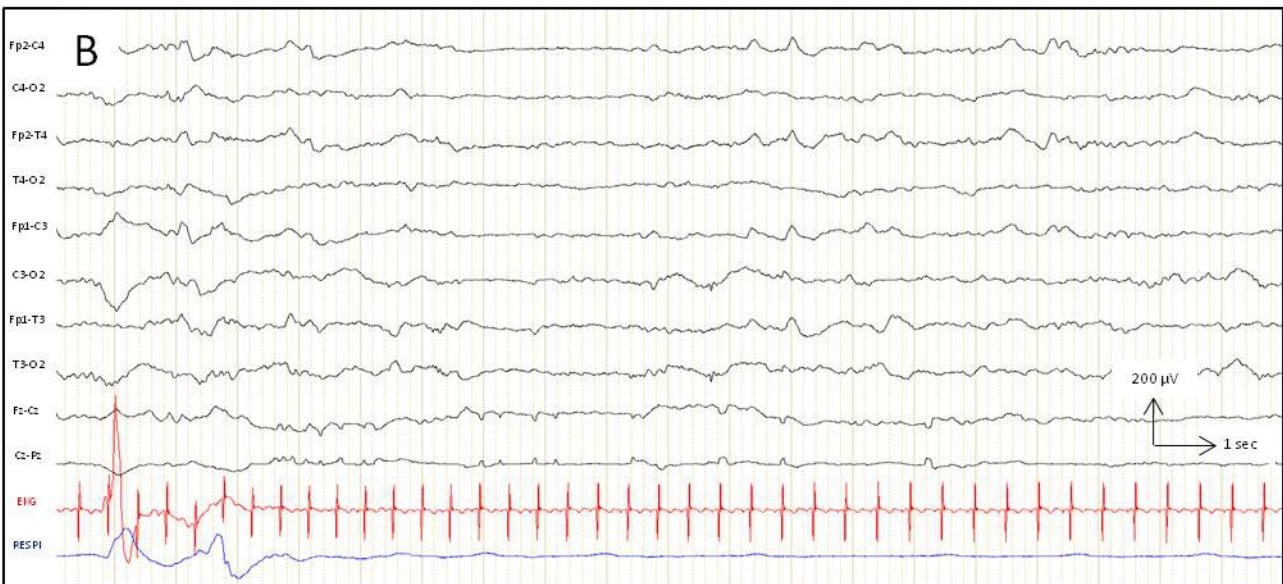
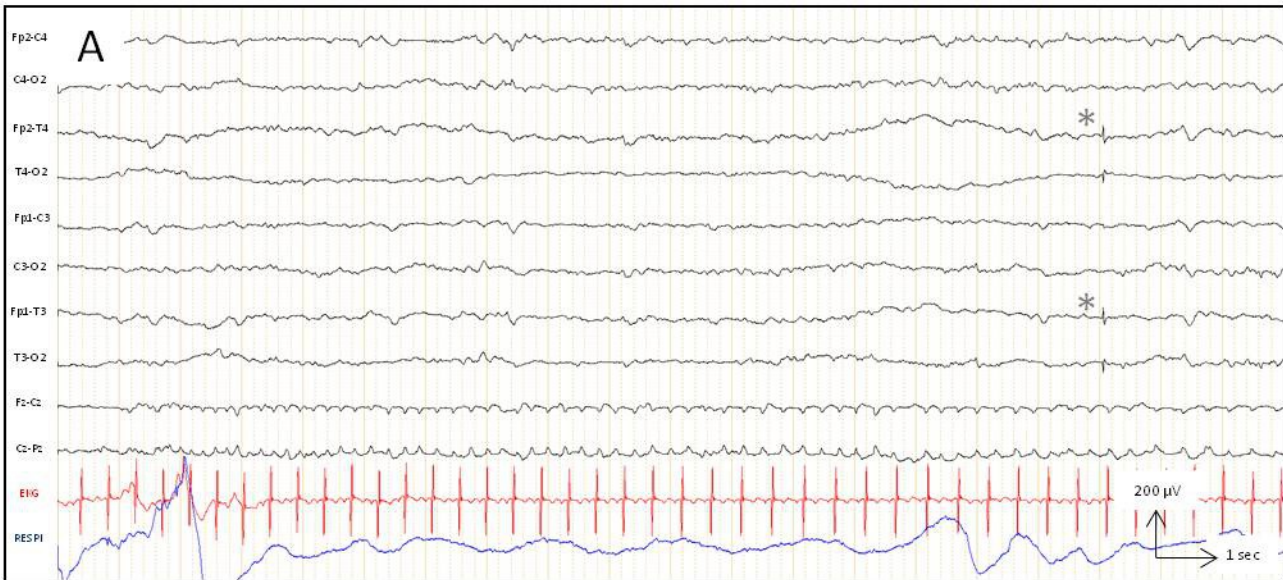
Channel	Lead
1	T4-Fp2
2	FP2-FP1
3	FP1-T3
4	T4-C4
6	C4-Cz
7	Cz-C3
8	C3-T3
9	T4-O2
10	O2-O1
11	O1-T3



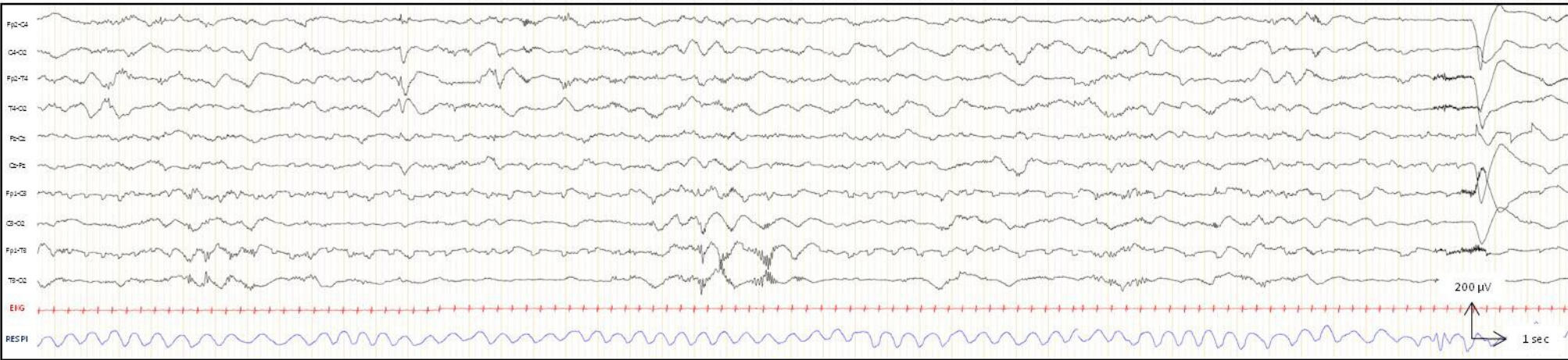
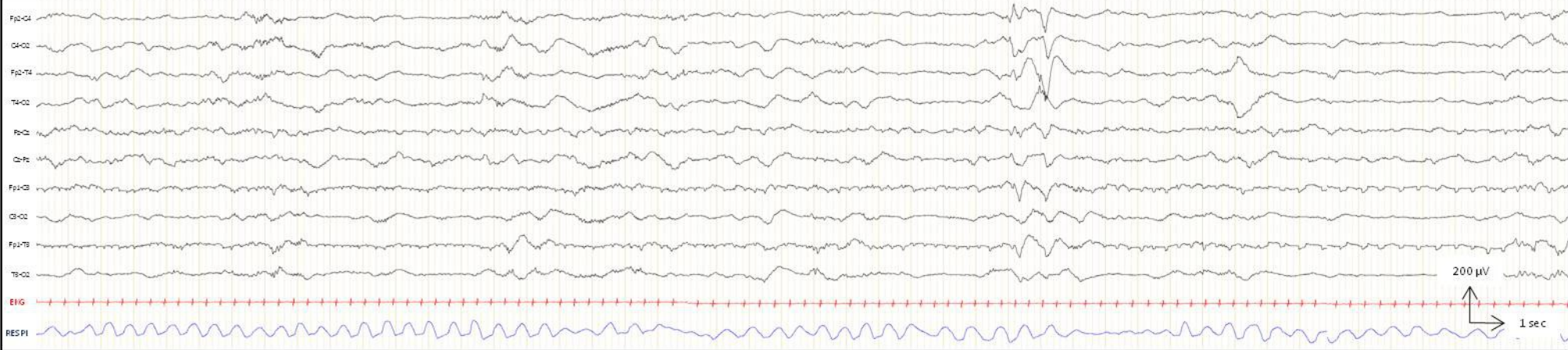


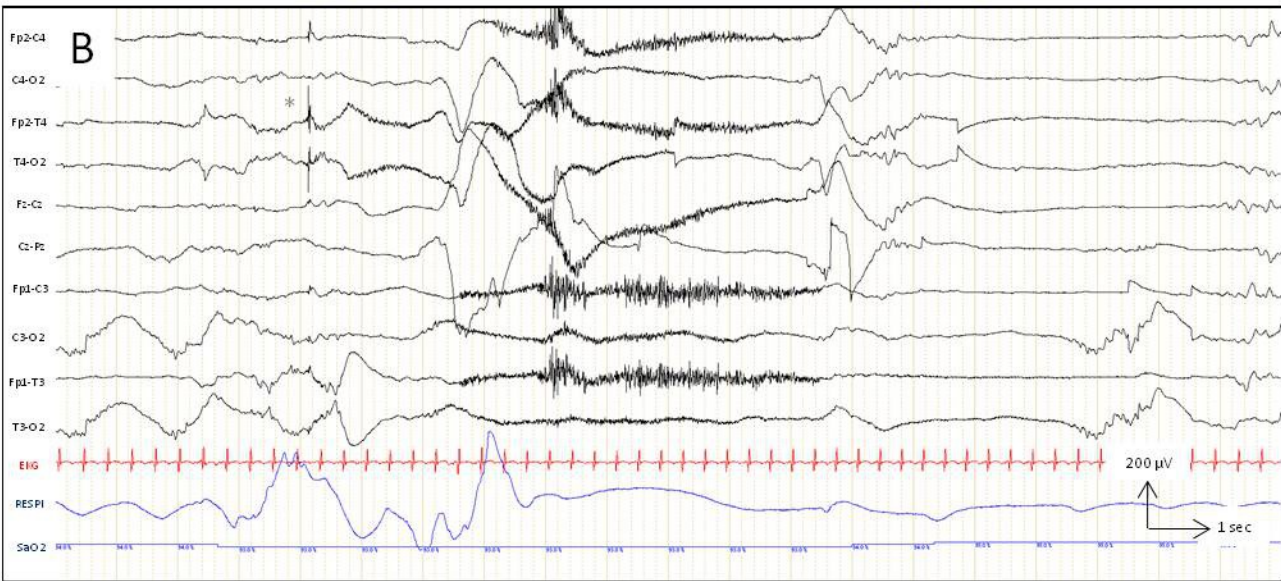
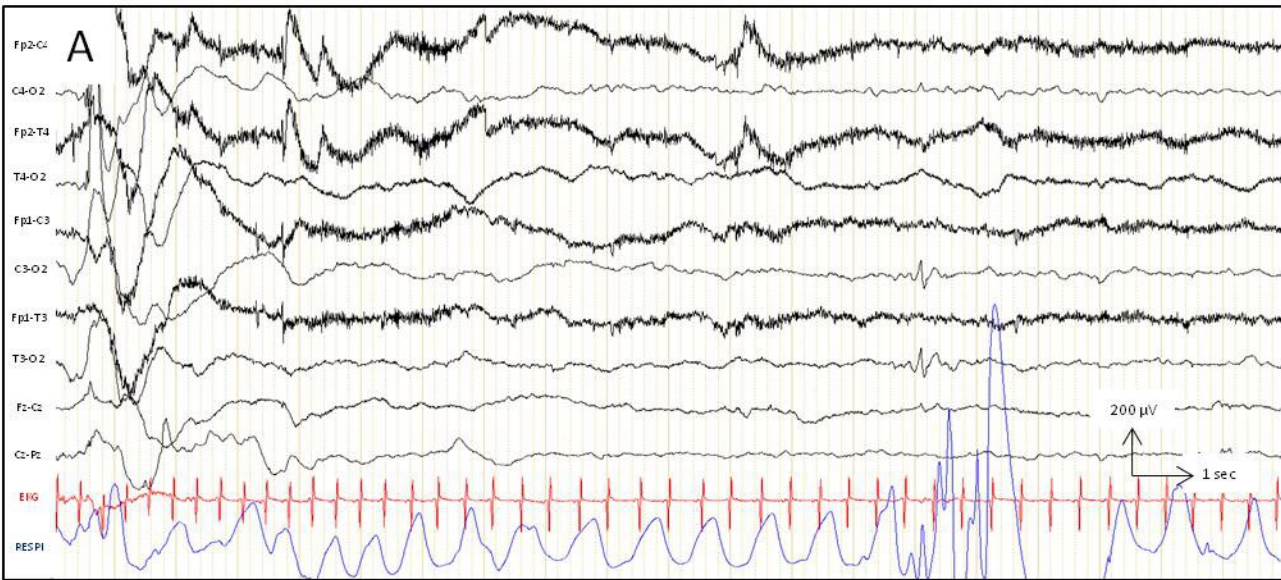




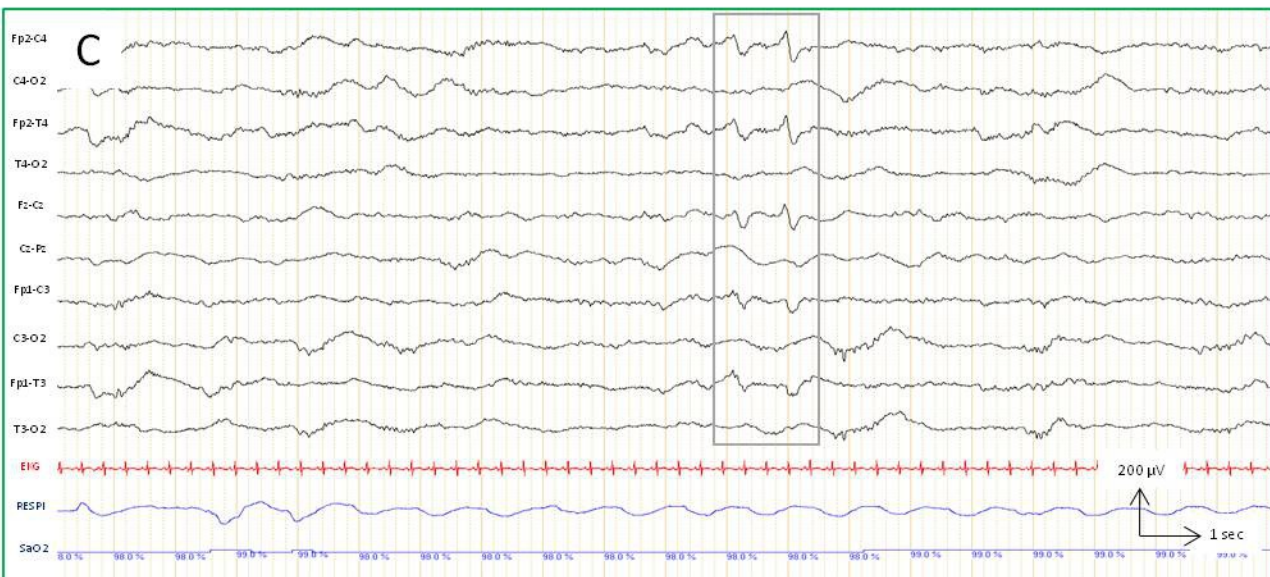
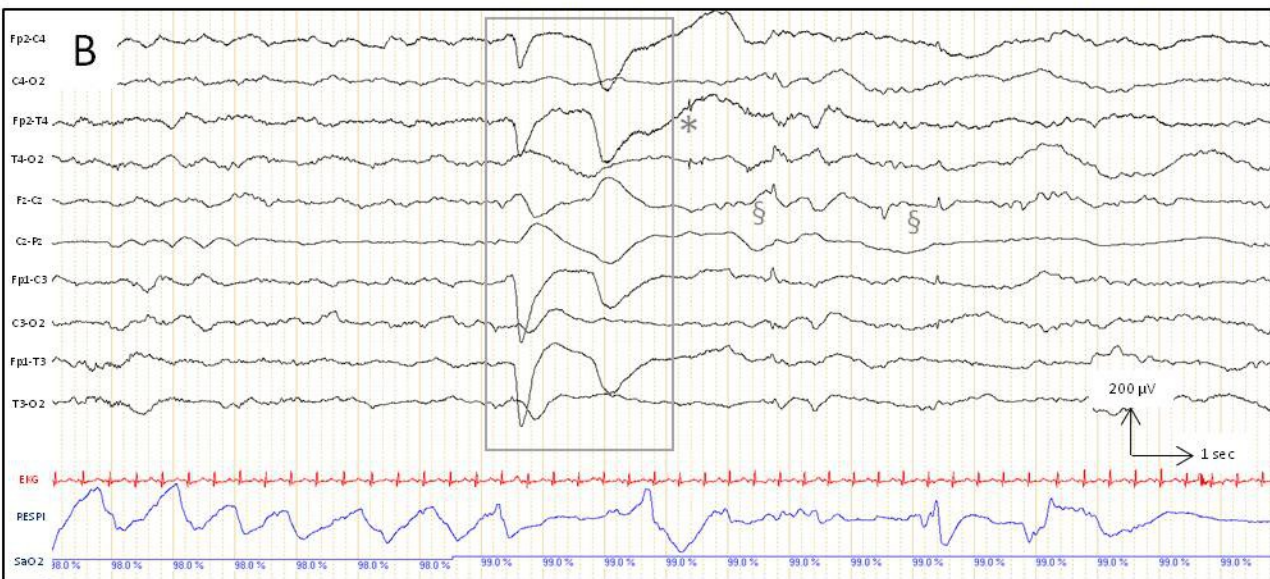
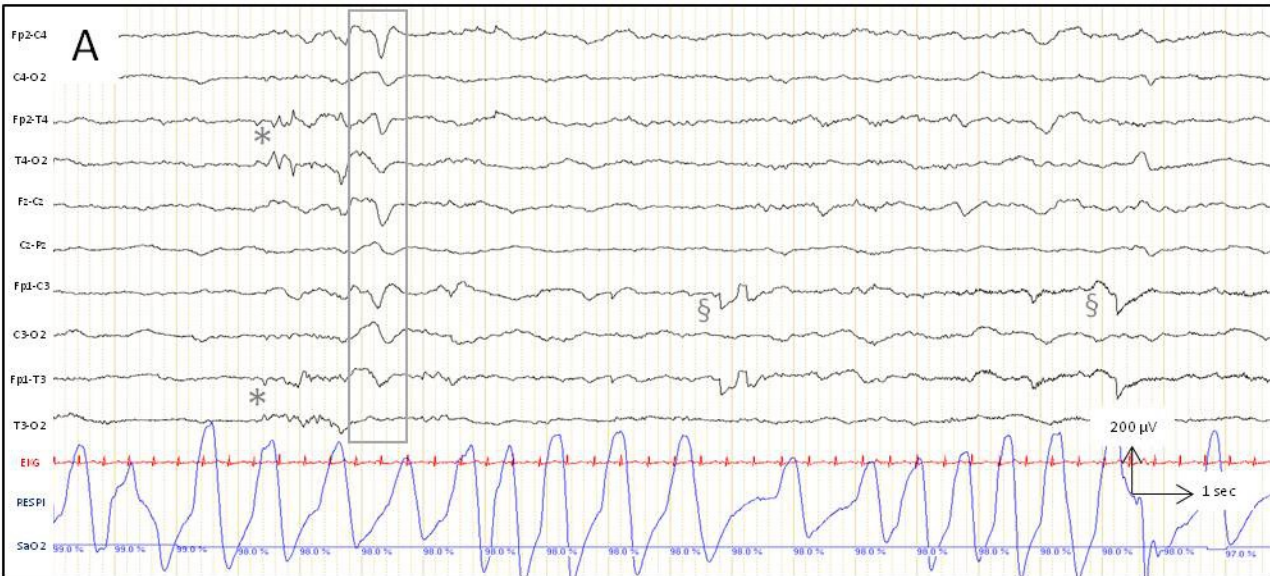




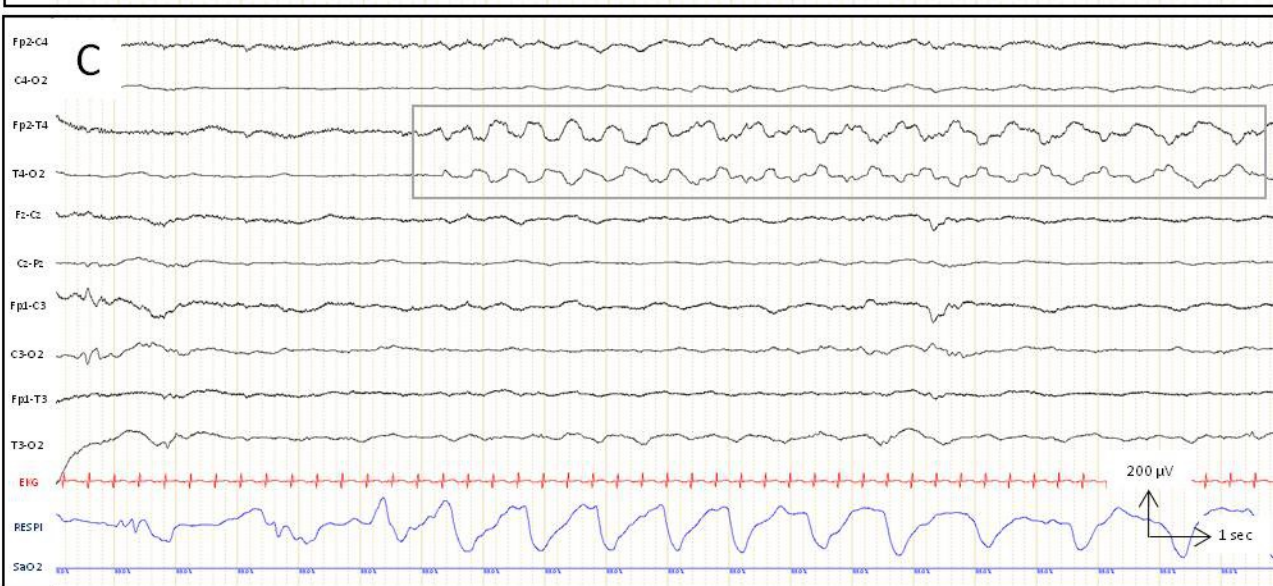
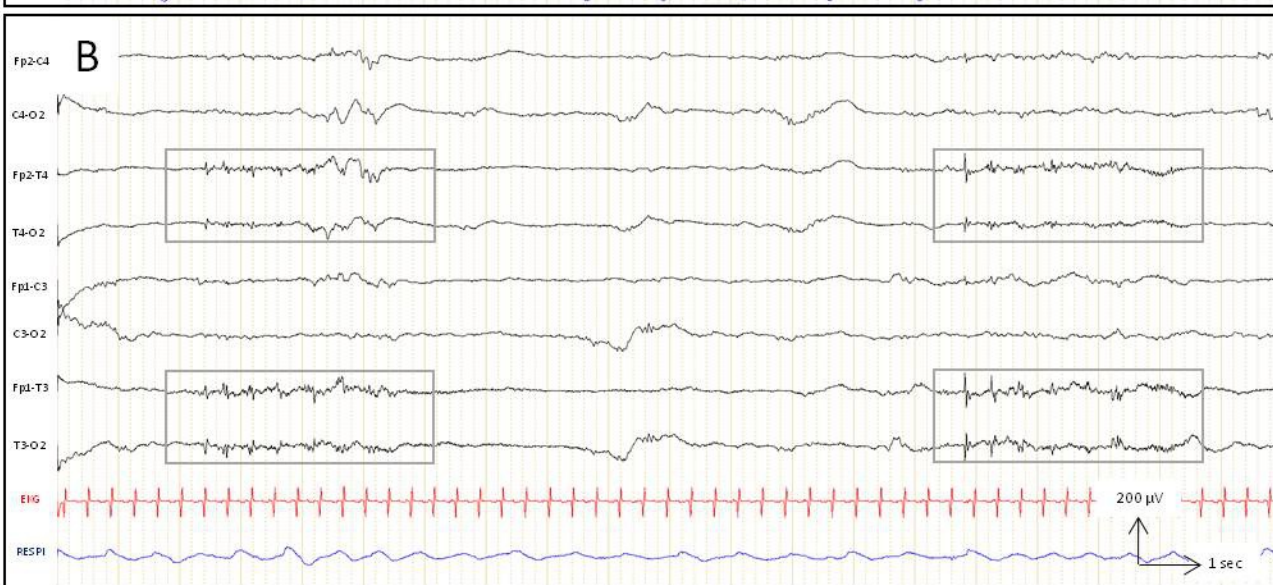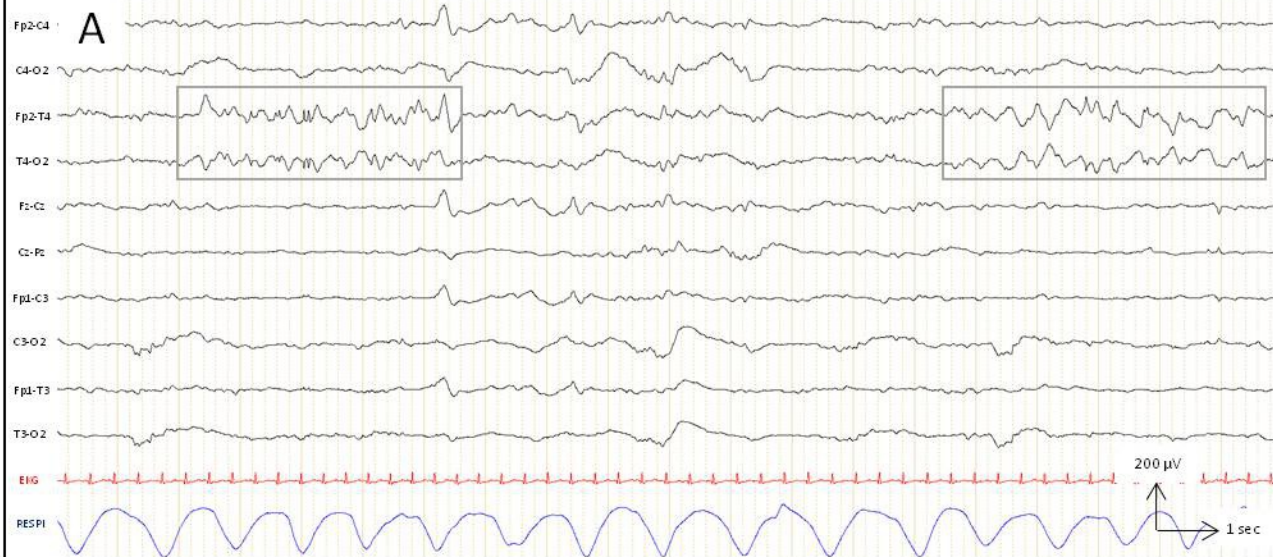




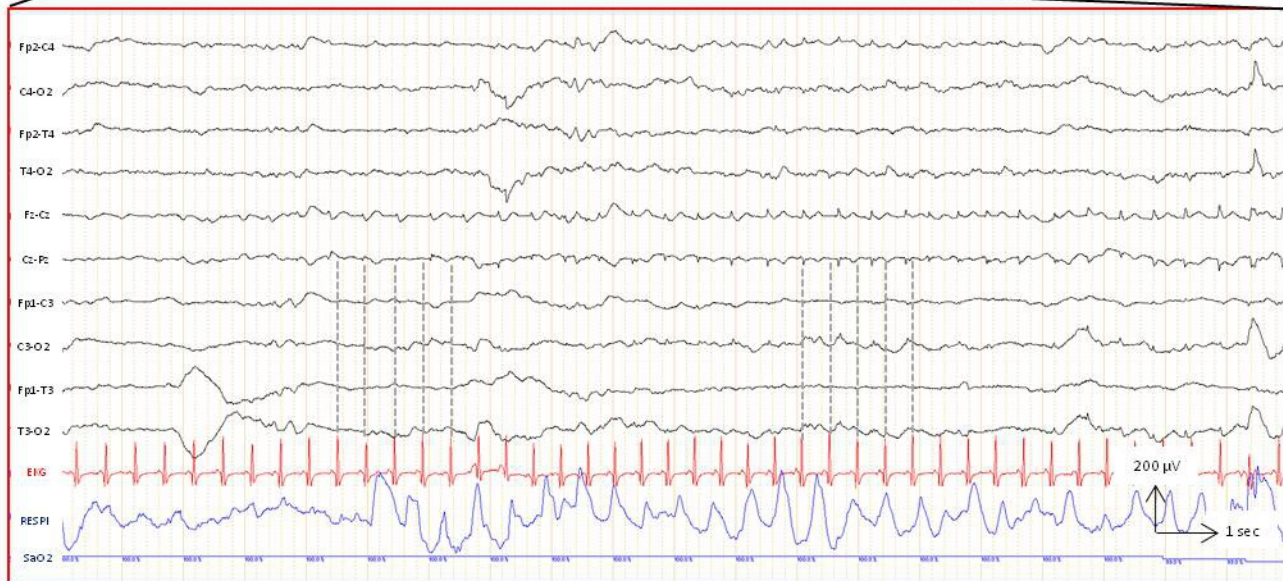
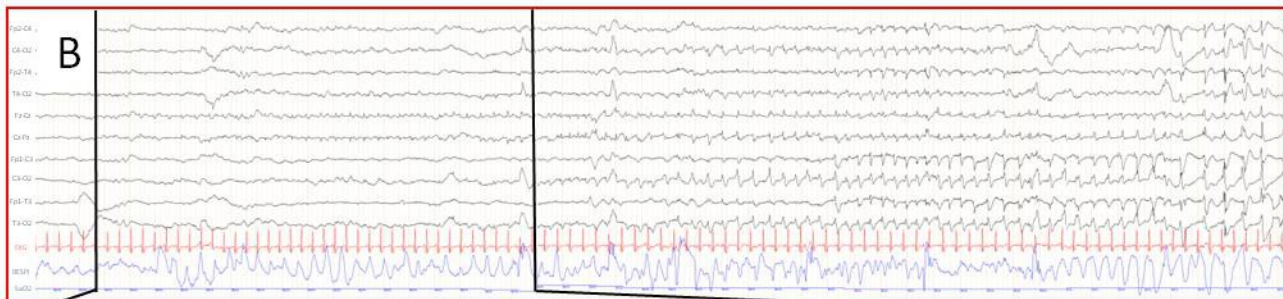
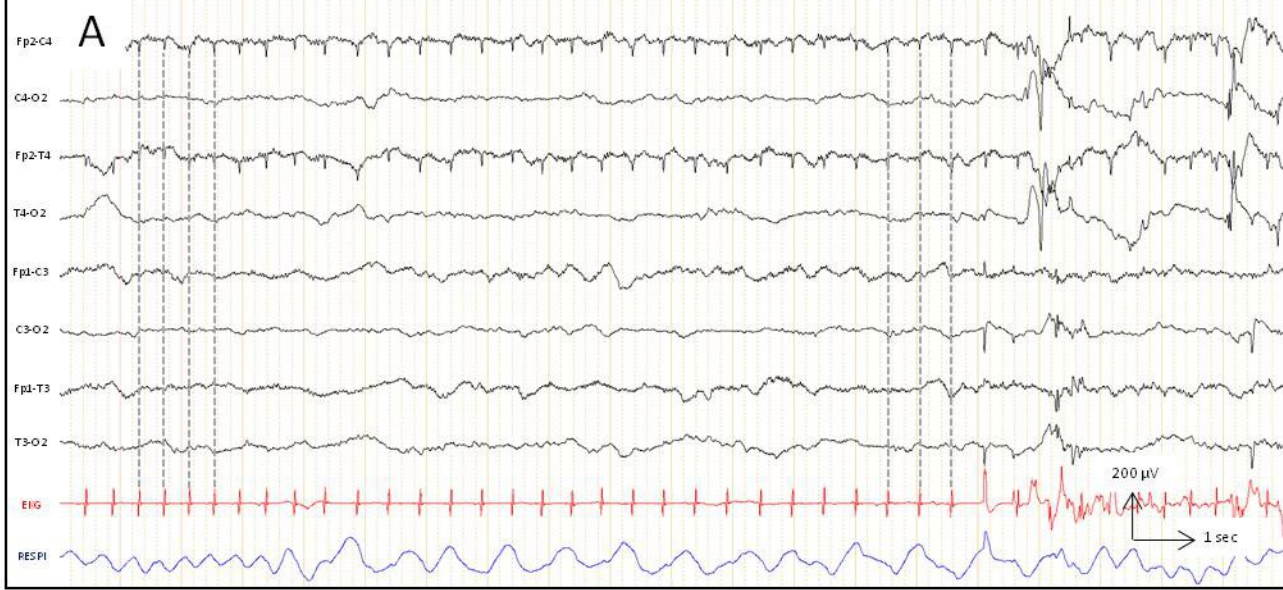




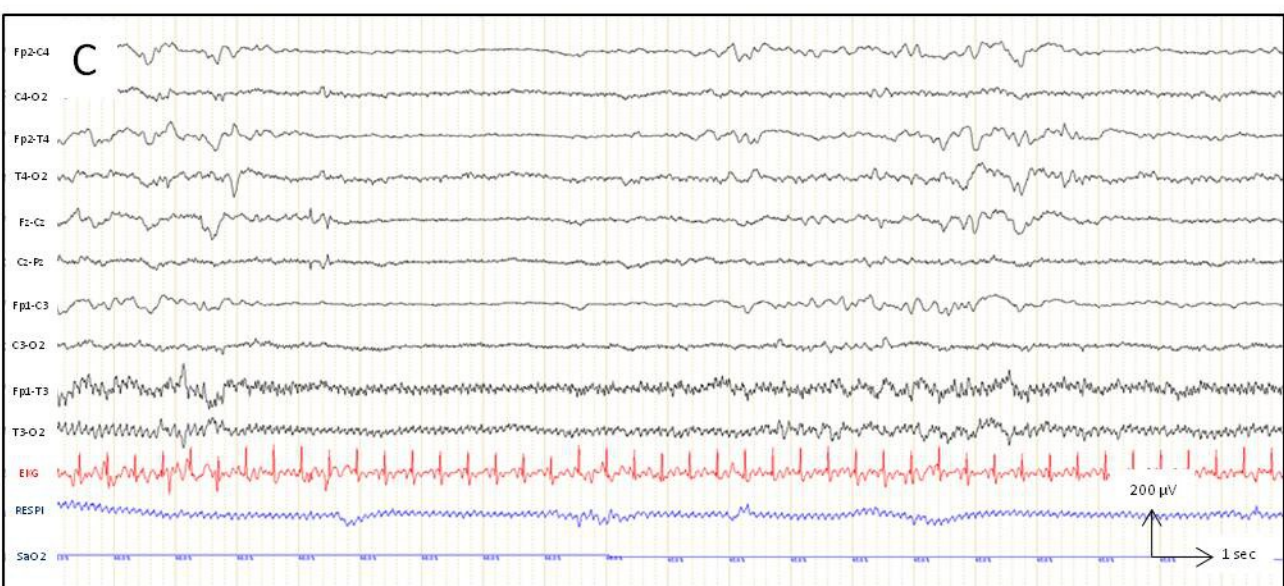
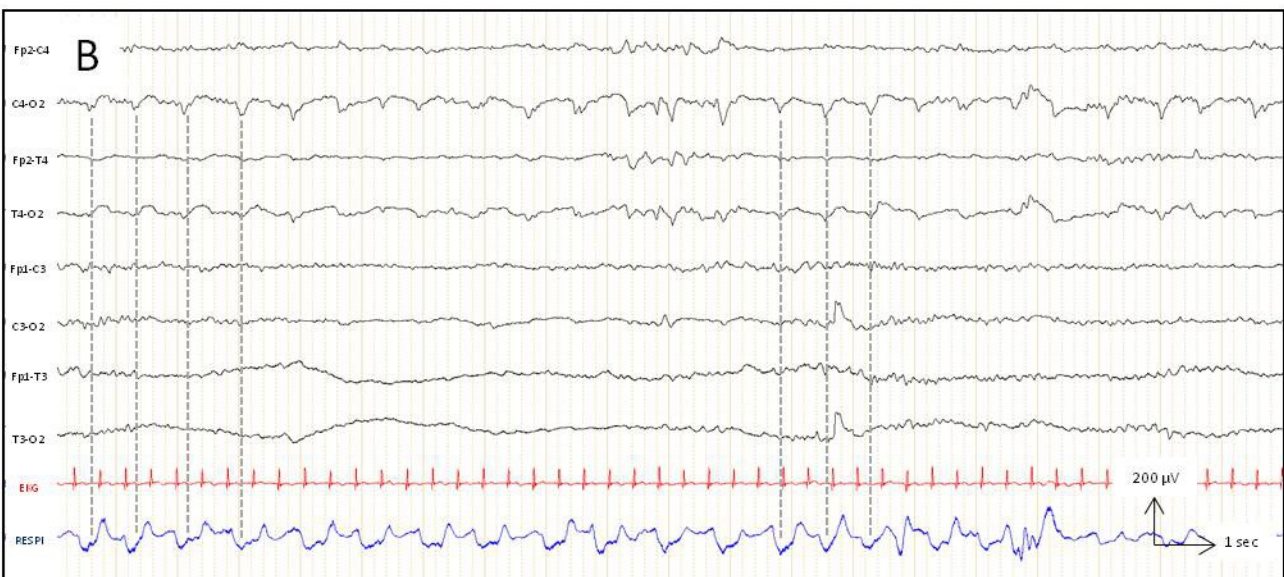
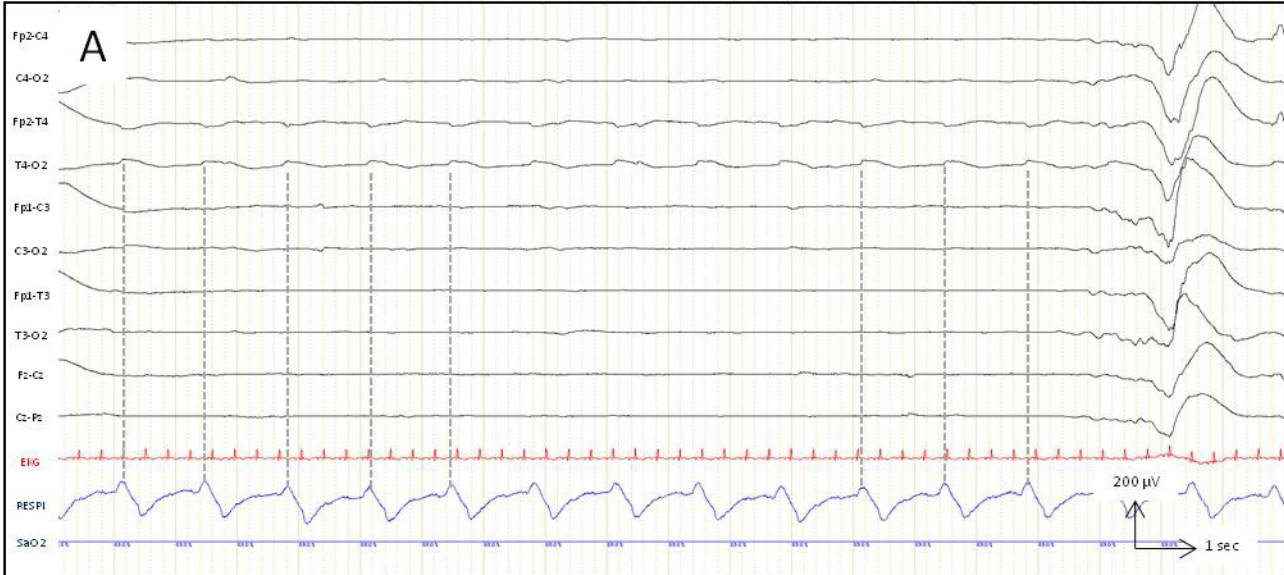


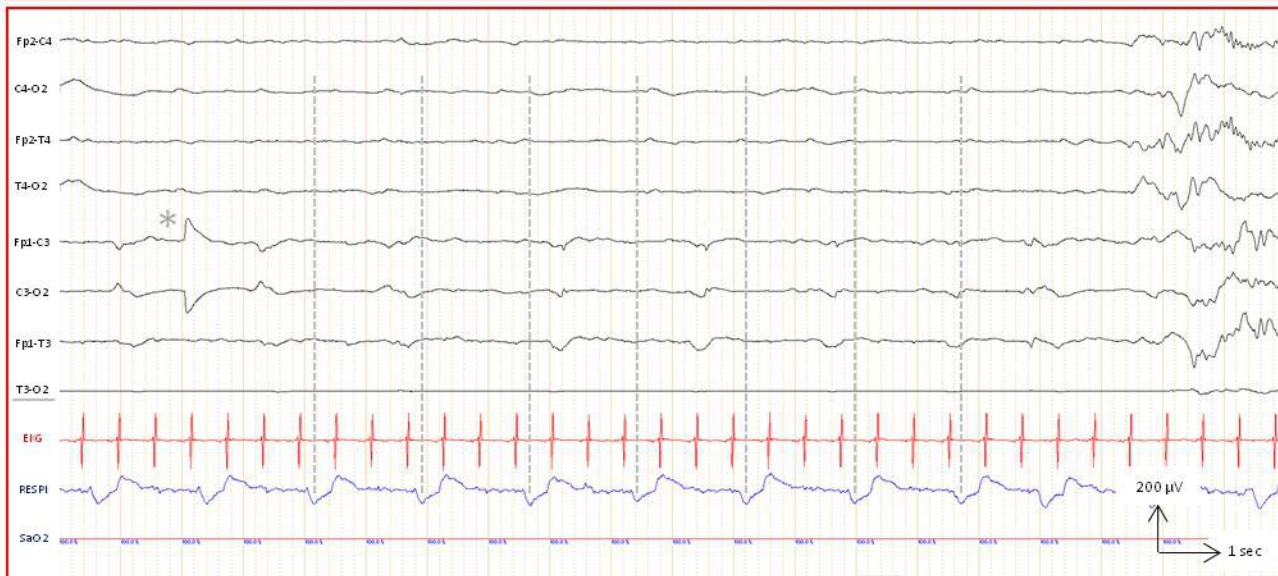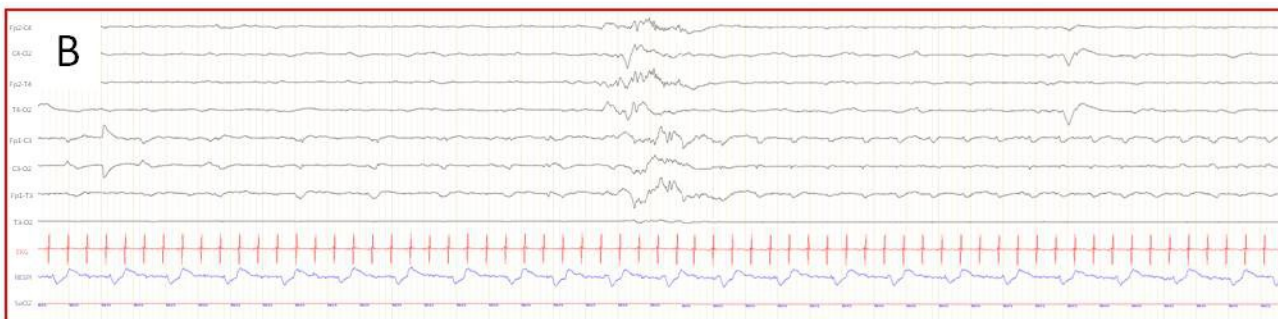


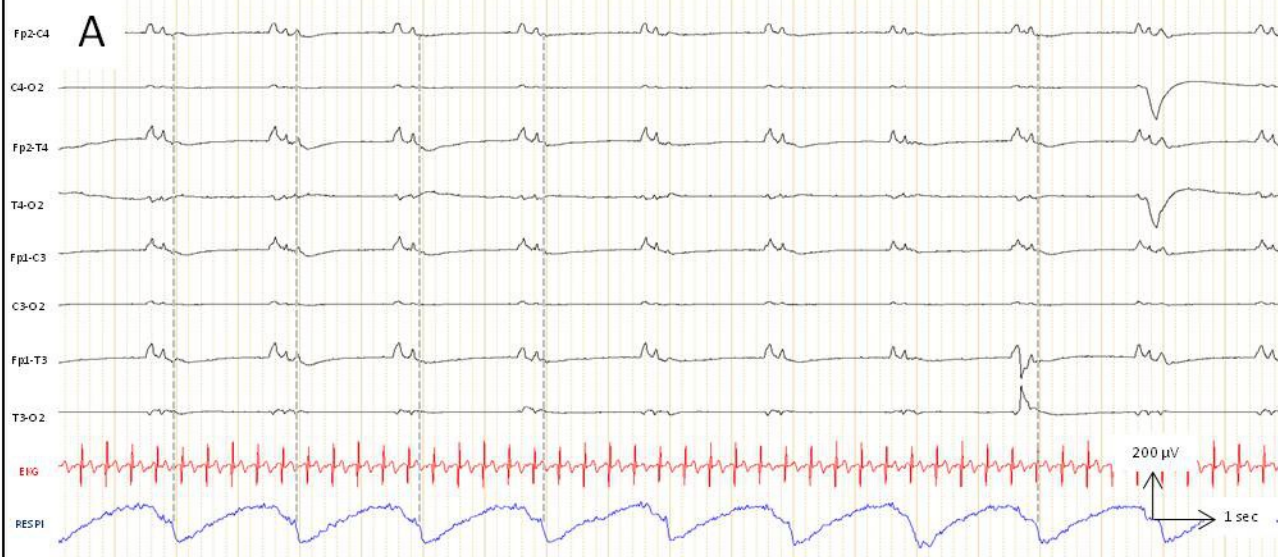



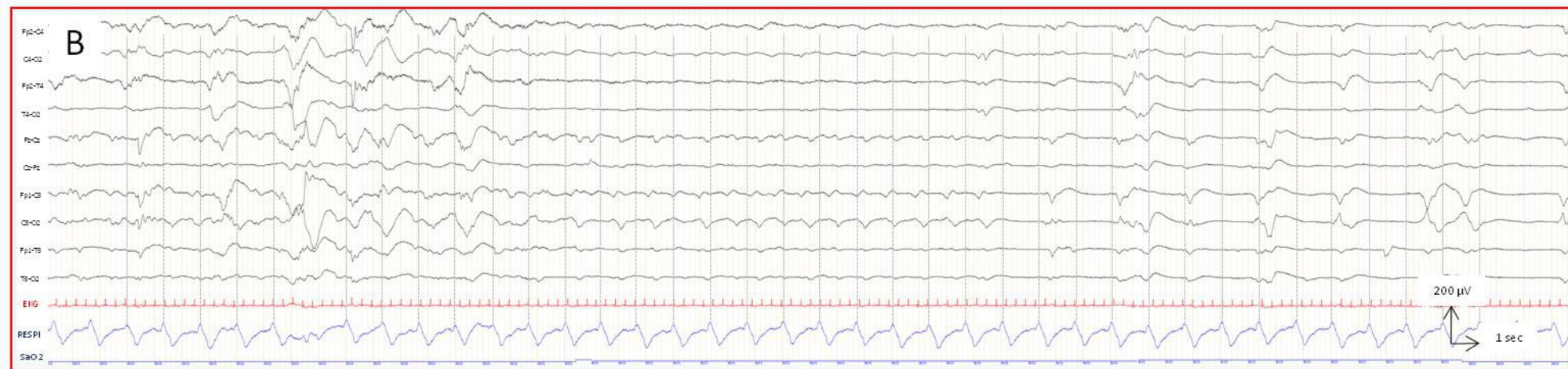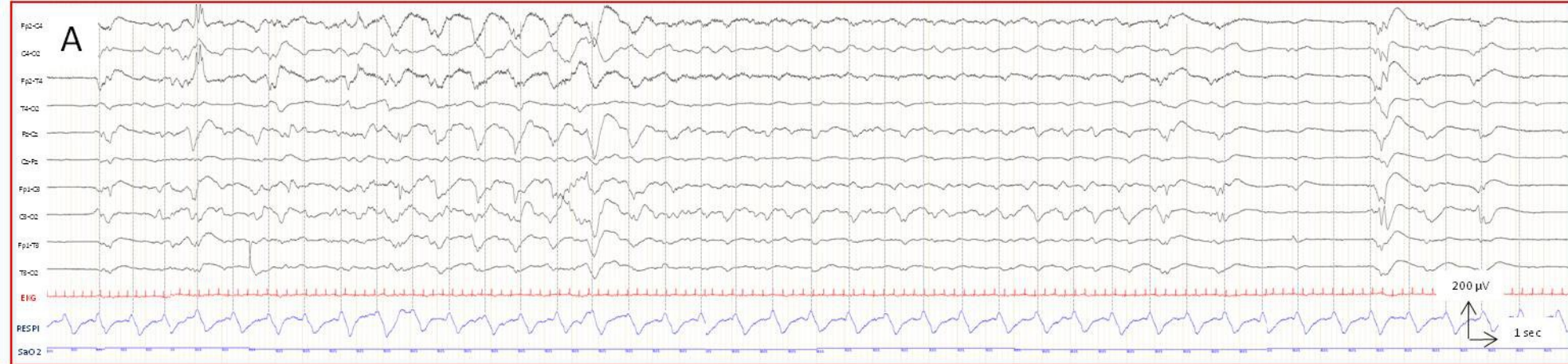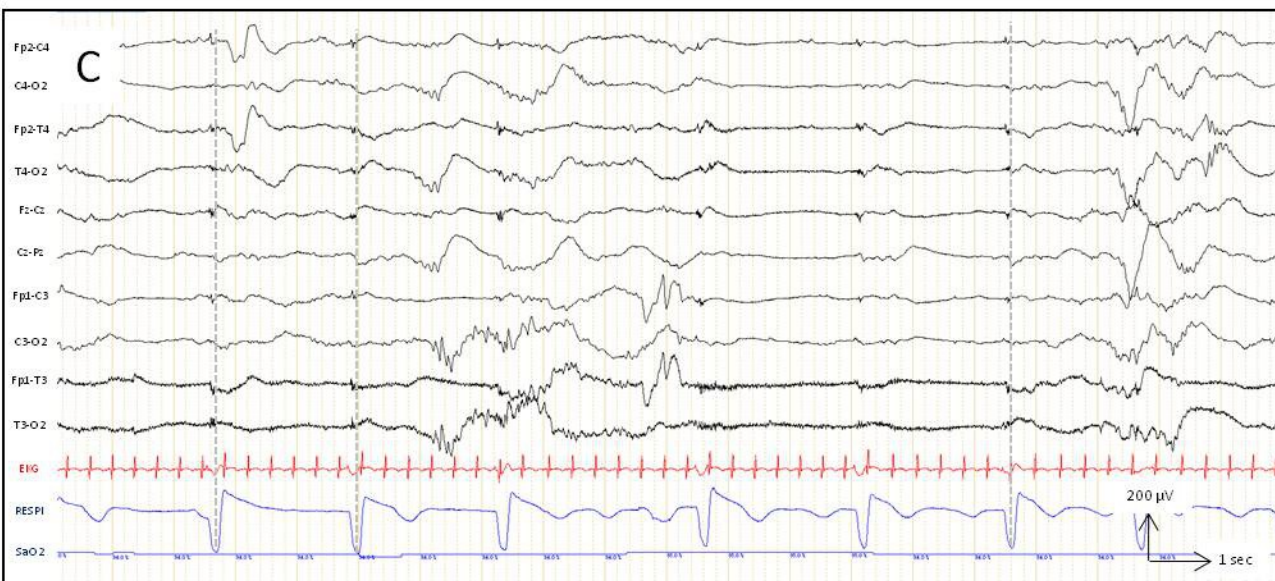
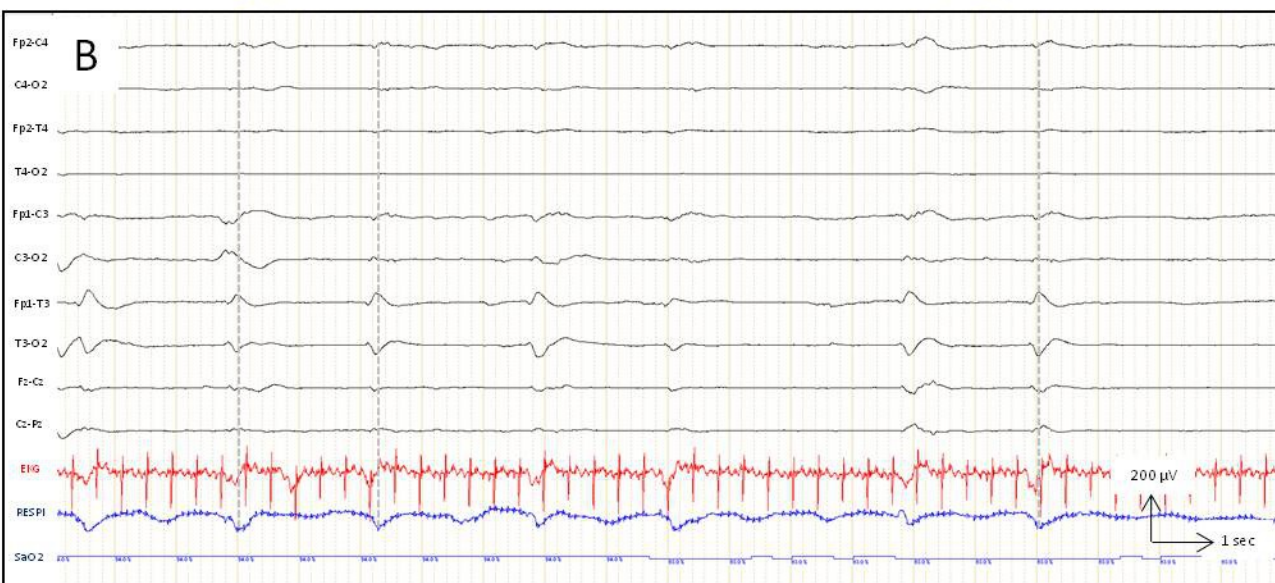
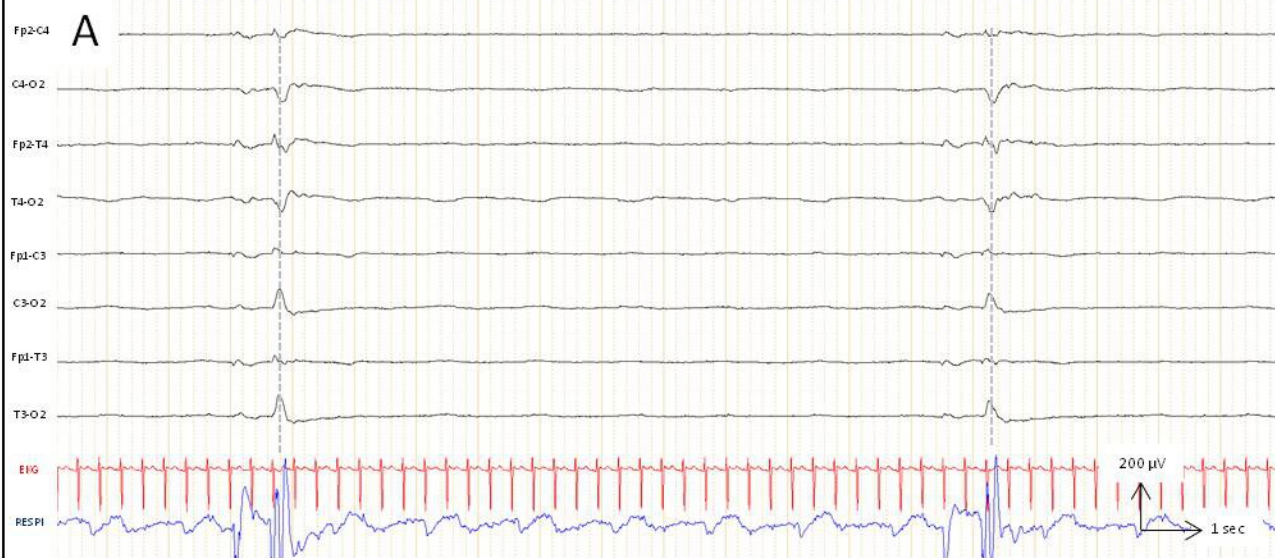




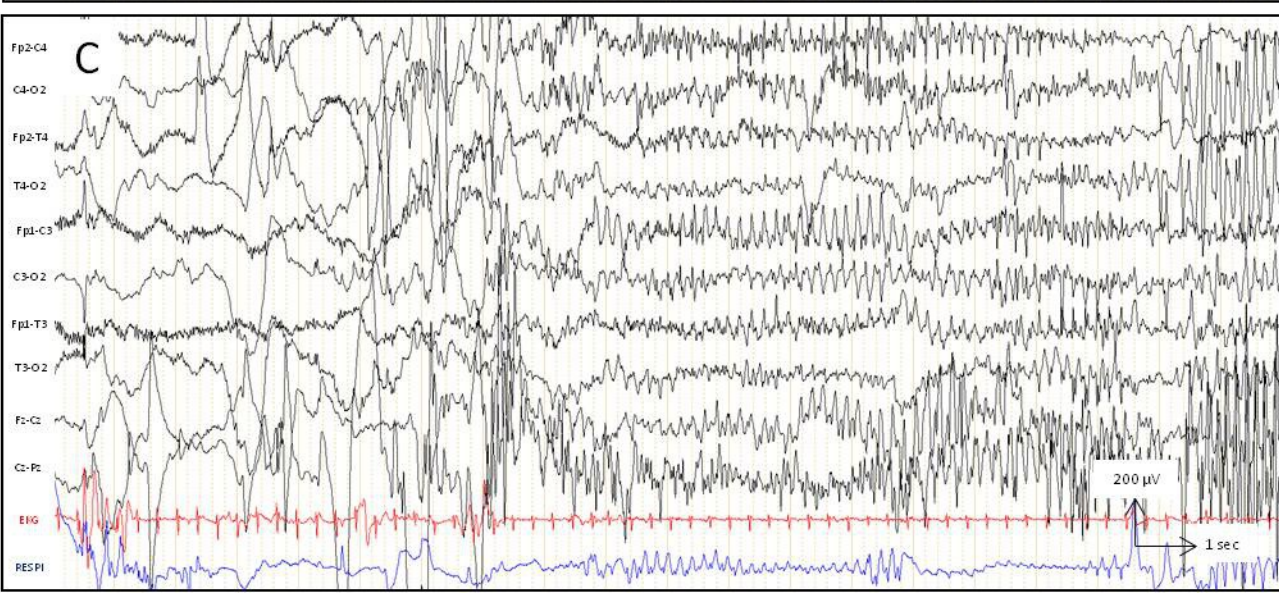
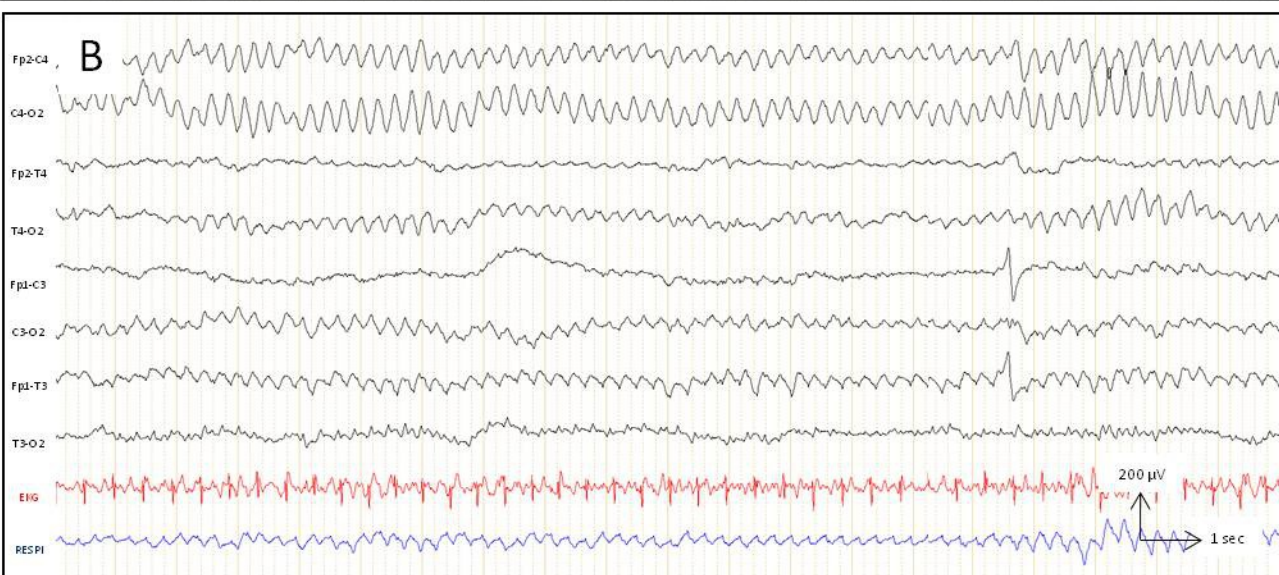
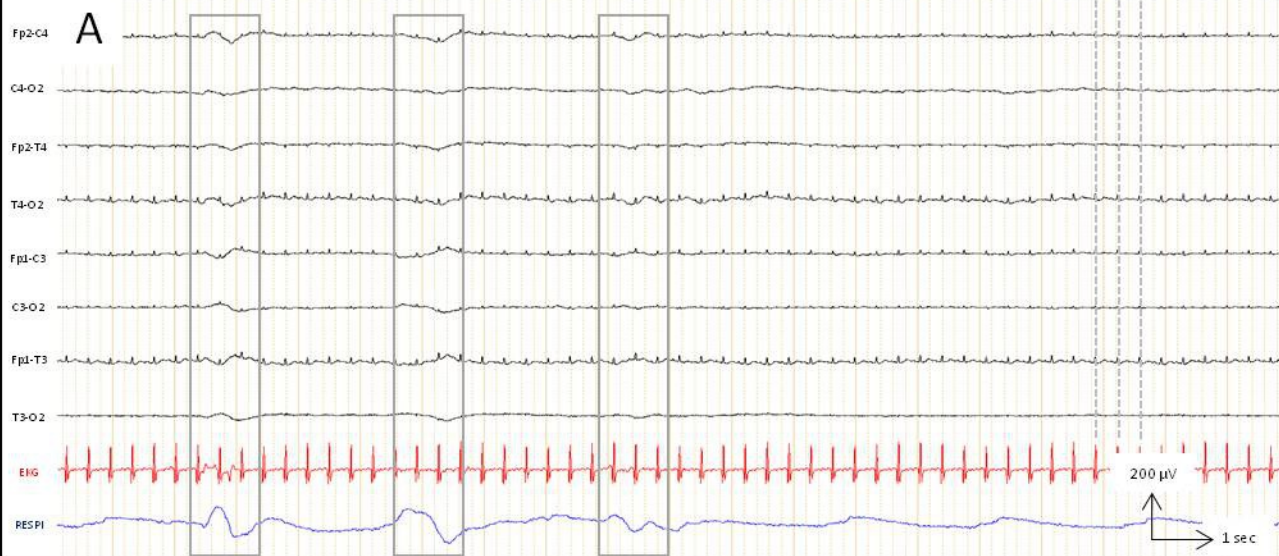












Parameters / signals	Sensors / electrodes	Position of the electrodes	Gain $\mu\text{V/mm}$	Time constant (s)	Filters	
					Low-pass (Hz)	High-pass (Hz)
EEG	Ag-AgCl cup Conducting adhesive Surgifix or flexible helmet	11 electrodes 10-20 system, adapted for neonates	10 Modular	0.3	0.5	30
ECG	Single-use ECG electrodes	2 electrodes Thorax (pre-cordial) or limbs	Modular	0.1	1.5	30
Ocular movements	Ag-Ag Cl cup electrodes Or single ECG electrodes	3 electrodes: 2 electrodes on the upper and lower external angle of each eye, 1 reference on the nasion)	Modular	0..3	0.5	30
EMG Chin muscle Others	EEG cup electrode ECG electrode	2 electrodes: 1 on the chin (active) and 1 on the mandible 2 cm distant (passive) Modular	Modular	0.1	1.5	30-70
Respiration	Thoracic strain gauge  Abdominal belt  Thermistors	On the thorax, below the nipple  2 cm above the belly button  At the entry of the nostril	Modular	1	0.15	15
Body movements	Piezo-crystal mechanograms	limbs	Modular	0.1	1.5	70
SaO <sub>2</sub>	Specific sensor	Hand or foot	Modular	-	-	-



1. Installation and switching on of the EEG acquisition station.
2. Enter patient information, choose the set-up, and start recording on "pause"; for hygienic reasons, one only returns to the computer after the equipment has been fully installed on the newborn.
3. Hand hygiene (hand washing with soap and/or hydro-alcoholic solution).
4. Put on the patient specific over-blouse.
5. Open a packet of sterile compresses and apply abrasive paste and conductive gel.
6. Connect the electrodes to the headbox according to their anatomical location.
7. Fill the cups with conductive gel and place the electrodes inside the incubator on a compress, separating the right side from the left side.
8. Gently thread the tubular net over the child's head and fold it over on itself on the child's forehead. Depending on the child's position, start by putting on the electrodes that are the most difficult to position, turning the child's head as little as possible.
9. Install all the electrodes on the head first (cups + OCG). Each electrode location should be prepared by gently rubbing with an abrasive paste. Areas with skin erosion are avoided; any change in electrode placement is reported. The 11 surface-active electrodes are placed according to the international 10/20 system: Fp1, Fp2, C3, C4, T3, T4, O1, O2, Fz, Cz and Pz.
10. The reference electrode is usually placed the middle front position.
11. The ground electrode can be placed on the head or limbs.
12. Pass all the threads through the top of the net and wrap them in a compress so that the threads cross each other as little as possible.
13. Lift the net towards the top of the skull and ensure that it will not slip during the examination.
14. Place the respiratory sensor, ECG, EMG.
15. Close the incubator doors.
16. Repeat hand hygiene with the hydro-alcoholic solution and return to the computer.
17. Check the impedances: they must be lower than 10 k $\Omega$ , especially the ground and reference electrodes.
18. Correct artifacts if necessary.
19. Frame the video.
20. Start recording.
21. Monitor the recording in progress: If the EEG technician needs to access the patient or the electrodes during the examination, any opening of the incubator will be preceded by hand disinfection with a hydro-alcoholic solution.
22. End of the examination: remove the cup electrodes, EMG, EEG, ECG, EOG, and respiratory sensor, as well as the net.
23. Soak the saline pads with saline and clean each position of the EEG electrodes and dry.
24. Notify the caregiver of departure.
25. Clean the mobile EEG unit with disinfectant wipes and the electrode set with a specific detergent solution.

- Anoxo-ischemia
  - Acute fetal distress
  - Severe cardio-respiratory failure
  - Hemodynamic disorders
  - Low blood pressure
  - Hypovolemia
  - Twin to twin transfusion syndrome
  - Perinatal stroke
- Traumatic conditions
  - Maternal trauma
  - Traumatic delivery
- Infection
  - Premature rupture of membranes
  - Chorioamnionitis
  - Proven materno-foetal infection
  - Severe late onset sepsis
  - Meningitis
- Inflammation and toxins:
  - Twin surviving (the other died in utero)
  - Necrotising enterocolitis
  - Necrotizing fascitis
- Abnormal pre- and postnatal neuroimaging
- Severe growth retardation
- Metabolic disorders, high bilirubin level

Gestational age	$\leq 28$ wGA	29-33 wGA		$> 33$ wGA with risk factors
		without risk factors	with risk factors	
Schedule of recording	day 2-3 day 7-8 31-32 wPMA 36 wPMA	1 <sup>st</sup> week	day 1-3 day 7-8 31-32 wPMA 36 wPMA	1 <sup>st</sup> week

- Spasms
- Myoclonus
- Focal clonic or tonic movements
- Stereotypic movements:
  - swimming
  - boxing
  - bicycling
  - chewing
- Excessive suction, oral stereotypes
- Atypical behavior
  - abnormal cry
  - unexpressive face
  - fixed open eyes
  - excessive tremor
  - behavior arrest
- Abnormalities of muscle tone
  - hypotonia
  - hypertonia
- Unprovoked neuro-vegetative dysfunction
  - excessive apnea
  - unexplained arterial hypertension
  - burst of tachycardia
  - life threatening events
  - severe bradycardia
  - pallor
  - flushing