HAL open science

Growth hormone replacement improved oocyte quality in a patient with hypopituitarism: A study of follicular fluid

Florence Scheffler, Rosalie Cabry, Marion Soyez, Henri Copin, Moncef Ben Khalifa, Aviva Devaux, Rachel Desailloud

To cite this version:

Florence Scheffler, Rosalie Cabry, Marion Soyez, Henri Copin, Moncef Ben Khalifa, et al.. Growth hormone replacement improved oocyte quality in a patient with hypopituitarism: A study of follicular fluid. Annales d'Endocrinologie = Annals of Endocrinology, 2021, 82 (6), pp.590–596. 10.1016/j.ando.2021.05.003 . hal-03688185

HAL Id: hal-03688185

https://u-picardie.hal.science/hal-03688185v1

Submitted on 5 Jan 2024

HAL is a multi-disciplinary open access archive for the deposit and dissemination of scientific research documents, whether they are published or not. The documents may come from teaching and research institutions in France or abroad, or from public or private research centers.

L'archive ouverte pluridisciplinaire **HAL**, est destinée au dépôt et à la diffusion de documents scientifiques de niveau recherche, publiés ou non, émanant des établissements d'enseignement et de recherche français ou étrangers, des laboratoires publics ou privés.

Distributed under a Creative Commons Attribution - NonCommercial 4.0 International License

Version of Record: https://www.sciencedirect.com/science/article/pii/S0003426621000779
Manuscript_063d6cfe6f59a9e4ac4c64925779e948

Growth hormone replacement improved oocyte quality in a patient with hypopituitarism: a **study of follicular fluid**

Amélioration de la qualité ovocytaire par substitution d'hormone de croissance chez une patiente avec hypopituitarisme : étude du liquide folliculaire

Authors: Florence Scheffler [a,b], Rosalie Cabry[a,b], Marion Soyez[c], Henri Copin[a], Moncef Ben Khalifa[a,b], Aviva Devaux[a,b], Rachel Desailloud[d,b]

Affiliations:

[a] Reproductive Medicine and Biology Department, Cytogenetics and CECOS of Picardy, Amiens University Hospital, Picardy, France

[b] Peritox UMR_I 01, CURS, Jules Verne University of Picardy, Amiens, France

[c] Endocrine and Bone Biology Department, Amiens University Hospital, Picardy, France

[d] Endocrinology, Diabetes, and Nutrition Department, Amiens University Hospital, Picardy, France

Corresponding author: Florence SCHEFFLER

Phone: +33 (0)6 81 37 33 29

Email: scheffler.florence@chu-amiens.fr

Address: Médecine et Biologie de la Reproduction, Cytogénétique et CECOS de Picardie,

Centre de biologie humaine

CHU Amiens Picardie, site sud

30 avenue de la Croix Jourdain

80000 Amiens, France

© 2021 published by Elsevier. This manuscript is made available under the CC BY NC user license
https://creativecommons.org/licenses/by-nc/4.0/

Authors:

Rosalie Cabry: email; cabry.rosalie@chu-amiens.fr

Address: Médecine et Biologie de la Reproduction, Cytogénétique et CECOS de Picardie,

Centre de biologie humaine

CHU Amiens Picardie, site sud

30 avenue de la Croix Jourdain

80000 Amiens, France

Marion Soyez: email; soyez.marion@chu-amiens.fr

Address: Biologie Endocrinienne et Osseuse,

Centre de biologie humaine

CHU Amiens Picardie, site sud

30 avenue de la Croix Jourdain

80000 Amiens, France

Henri Copin: email; copin.henri@chu-amiens.fr

Address: Médecine et Biologie de la reproduction, Cytogénétique et CECOS de Picardie,

Centre de biologie humaine

CHU Amiens Picardie, site sud

30 avenue de la Croix Jourdain

80000 Amiens, France

Moncef Ben Khalifa: email; benkhalifa.moncef@chu-amiens.fr

Address: Médecine et Biologie de la reproduction, Cytogénétique et CECOS de Picardie,

Centre de biologie humaine

CHU Amiens Picardie, site sud

30 avenue de la Croix Jourdain

80000 Amiens, France

Aviva Devaux: email; devaux.aviva@chu-amiens.fr

Address: Médecine et Biologie de la Reproduction, Cytogénétique et CECOS de Picardie,

Centre de biologie humaine

CHU Amiens Picardie, site sud

30 avenue de la croix jourdain

80000 Amiens, France

Rachel Desailloud: email; desailloud.rachel@chu-amiens.fr

Address: Endocrinologie, Diabète et Nutrition

Place Victor Pauchet

CHU Amiens Picardie, site Nord

80000 Amiens, France

ABSTRACT
BACKGROUND: Growth hormone (GH) is known to be involved in ovarian folliculogenesis and oocyte maturation. In patients with poor ovarian response without growth hormone deficiency (GHD), adjuvant GH treatment improves in-vitro fertilization (IVF) results. Improvement of oocyte quality in IVF by GH replacement was reported in only a few patients with GHD. We report on another case with study of follicular fluid.
METHODS: A 29-year-old patient with hypopituitarism was referred to our infertility center. She was undergoing hormonal replacement for hypogonadotropic hypogonadism and diabetes insipidus, and did not at first want GH replacement. Four IVF procedures were performed between 2011 and 2014. Growth hormone replacement (somatotropin 1.1mg/day) was initiated before the fourth IVF procedure and unmasked central hypothyroidism; levothyroxine (75 mg/day) was introduced. It took 10 months to reach the treatment objectives for insulin-like growth factor 1 (IGF1), free triiodothyronine (fT3) and free thyroxine (fT4). GH, IGF1 and thyroid hormones were measured in the blood and follicular fluid before and after GH and thyroid hormone replacement. Oocyte and embryo quality were also compared.
RESULTS: The first 3 IVF procedures were performed without GH replacement. 62% to 100% of mature oocytes presented one or more morphologic abnormalities: diffuse cytoplasmic granularity, large perivitelline space with fragments, fragmentation of the first polar body, ovoid shape, or difficult denudation. Embryo quality was moderate to poor (grade B to D), and no pregnancy was obtained after embryo transfer. After GH replacement, hormones levels increased in follicular fluid: GH [7.68 *vs.* 1.39 mIU/L], IGF1 [109 *vs.* <25 ng/mL], fT3 [3.7 *vs.* 2.5 pmol/L] and fT4 [1.45 *vs.* 0.84 ng/mL]. Concomitantly, there was dramatic improvement in oocyte quality (no abnormal morphologies) and embryo quality (grade A), allowing an embryo transfer with successful pregnancy.
CONCLUSIONS: This is the first report illustrating changes in hormonal levels in follicular fluid and the beneficial effect of GH replacement on oocyte and embryo quality during an IVF procedure in a patient with hypopituitarism. These results suggest that GH replacement is beneficial for oocyte quality in patients with GHD.

Résumé
CONTEXTE: L'hormone de croissance (GH) joue un rôle dans la folliculogénèse ovarienne et la maturation ovocytaire. Chez les patientes sans déficit en GH ayant une mauvaise réponse ovarienne, le traitement adjuvant par GH améliore les résultats en fécondation in vitro (FIV). Seules quelques évaluations de la qualité ovocytaire chez des candidates à la FIV avec déficit en GH ont été publiées. Nous en rapportons un nouveau cas avec étude du liquide folliculaire.
MÉTHODES: Une patiente de 29 ans hypopituitaire a été adressée dans notre centre d'assistance médicale à la procréation. Elle bénéficiait d'un traitement hormonal pour un hypogonadisme hypogonadotrope et un diabète insipide et ne souhaitait pas de traitement par GH. Quatre tentatives de FIV ont été réalisées entre 2011 et 2014. La substitution par GH (somatotropine 1,1 mg/jr) a été initiée avant la quatrième tentative. Une hypothyroïdie centrale a été démasquée par le traitement par GH: la substitution par lévothyroxine (75 mg/jour) a été introduite. Les taux cibles d'l'IGF1 (insulin-like growth factor 1), la T3L (triiodothyronine libre) et la T4L (thyroxine libre) ont été obtenu après 10 mois de substitution. Les taux de GH, d'IGF1 et d'hormones thyroïdiennes ont été mesurées dans le sang et le liquide

folliculaire avant et après substitution par GH et hormones thyroïdiennes. La qualité ovocytaire et embryonnaire a aussi été comparée.
RÉSULTATS: Les 3 premières tentatives FIV ont été réalisées sans traitement par GH. 62% à 100% des ovocytes matures présentaient une ou plusieurs anomalies morphologiques: granularité cytoplasmique diffuse, augmentation de l'espace périvitellin avec présence de fragments, fragmentation du premier globule polaire, forme ovoïde de l'ovocyte ou décoronisation difficile. La qualité des embryons était intermédiaire à médiocre (grade B à D) et aucune grossesse n'a été obtenue après les transferts d'embryons. Après le traitement par GH, nous avons noté une augmentation des concentrations hormonales dans le liquide folliculaire : GH (7,68 *vs.* 1,39 mUI/L), IGF1 (109 *vs.* <25 ng/mL), fT3 (3,7 *vs.* 2,5 pmol/L) and fT4 (1,45 *vs.* 0,84 ng/mL). Parallèlement, nous avons observé une amélioration majeure de la qualité des ovocytes (aucun ovocyte avec anomalie morphologique) et des embryons (grade A), permettant un transfert d'embryon avec obtention d'une grossesse évolutive.
CONCLUSIONS: Il s'agit du premier cas objectivant les modifications hormonales dans le liquide folliculaire et l'effet bénéfique sur la qualité ovocytaire et embryonnaire d'une substitution par GH lors d'une tentative de FIV chez une patiente hypopituitaire. Ces résultats suggèrent qu'une substitution par GH améliore la qualité ovocytaire chez les patientes déficitaire en GH.

Keywords: In-vitro fertilization (IVF), hypopituitarism, growth hormone deficiency (GHD), growth hormone (GH) replacement, oocyte quality
Mots clés: Fécondation in vitro (FIV), hypopituitarisme, déficit en hormone de croissance (GH), substitution par GH, qualité ovocytaire.

Introduction

Many factors are involved in in vitro fertilization (IVF) outcomes, and oocyte and embryo quality are critical issues. Pituitary hormones other than gonadotropin are known to be involved in folliculogenesis and oocyte maturation. Growth hormone (GH) and gonadotropic cycles are closely related throughout life, starting with the regulation of the onset of puberty. Studies have shown that GH and IGF1 (insulin-like growth factor) stimulate the hypothalamo-gonadotropic cycles at all levels. GH influences the release of gonadotropins. GH also has both direct and IGF1-mediated effects on the ovary, including estradiol production by granulosa cells and oocyte maturation [1,2]. Few studies report the beneficial

effect of GH replacement on ovarian stimulation in women with GH deficiency (GHD) [3–6]. Improvement of oocyte quality in IVF was reported only in one patient with isolated GHD in 2018 [7]. The present work is, to our knowledge, the first case illustrating that an increase in GH/IGF1 in follicular fluid (FF) under GH replacement is associated with normalization of abnormal oocytes and improvement of embryonic quality during an IVF procedure in a patient with hypopituitarism.

Materials and methods

We report the case of a 29-year-old woman referred to our infertility center for treatment of acquired infertility due to hypogonadotropic hypogonadism. The approval by an ethical committee was not required for a case-report but informed consent has been obtained for the publication of the case report and accompanying images. She developed hypopituitarism (hypogonadotropic hypogonadism, GHD, and diabetes insipidus) following radiotherapy and chemotherapy for a brain dysgerminoma diagnosed when she was 15 years old. At the time of the treatment, she had primary amenorrhea, and puberty was induced by estrogen replacement therapy. When referred to our center, she was being treated with desmopressin (Minirin®, Ferring, France), an estrogen/progesterone-based hormone replacement therapy (Provames®, Merus Labs Luxco, Luxembourg, and Utrogestan®, Besins, France), and vitamin D supplementation (Uvedose®, Crinex, France). She did not want GH replacement because she was worried about a possible relapse of her brain dysgerminoma.

When first evaluated for infertility treatment, hormonal assays showed hypogonadotropic hypogonadism: follicle stimulated hormone (FSH); 5.4 mIU/mL (N: 3.4-12),luteinizing hormone (LH); 3 mIU/mL (N: 3-18.6), estradiol (E2); 8 pg/mL (N: 25-100), anti-Mullerian hormone (AMH); 8.1 ng/mL (N: 2-6), inhibin-B; 23 pg/mL (N: 45-340). She had no hyperandrogenism: total testosterone; 0.59 ng/mL (N:0.1-0.6), testosterone binding

protein (TeBG); 96 nmol/L (N: 18-83), dehydroepiandrosterone sulfate (SDHEA); 2 064 ng/mL (N:333-3 333). Thyroid function was normal. A pelvic ultrasound revealed a normal uterus. The ovaries were multi-follicular, concordant with the AMH value. The hysteroscopy showed a normal uterine cavity. Her husband was 29 years old with a history of an inguinal hernia treated at 10 years old without cryptorchidism. He presented moderate oligoasthenoteratozoospermia (OATS): volume; 4.6 mL (N: 1.5-6), sperm concentration; 11.4x10.6/mL (N: 15-200), progressive motility: 30% (N>32%), normal forms; 3% (N>15%) without any abnormality in his exams (karyotype, testicular ultrasound, and hormonal testing). This idiopathic OATS led us to favor an IVF procedure.

Results

The four IVF procedures are shown in detail in Table 1. For all of these procedures, when at least three follicles had reached a diameter ≥17 mm, a dose of 250 µg of recombinant human chorionic gonadotropin-rhCG (Ovitrelle®, Merck, France) was administered and oocyte retrieval was performed 35 h after hCG administration. The four IVF procedures were performed by intra-cytoplasmic sperm injection (ICSI). The endometrial thickness was optimal before all embryo transfers (between 7.5 mm and 8.5 mm). The first IVF was performed with an antagonist protocol, as is usually done in cases of multifollicular ovaries, to prevent ovarian hyperstimulation syndrome. Nine mature oocytes of 12 collected presented an abnormal granular cytoplasm. Denuding was difficult for 4 oocytes. The embryonic quality (for a day 2 or 3 embryo) was assessed by a score (Istanbul consensus): a grade A embryo was the one with the best implantation potential and a grade D the most unfavorable [8]. For the blastocysts' evaluation, the Gardner classification was used: developmental score from 1–6 based on their degree of expansion of the blastocyst (6 defining the most mature); scores from A to C to assess the development of the inner cell

mass and scores from A to C for the trophectoderm (score A defining the most optimal quality) [9]. One of 8 embryos obtained was transferred at day 3 (Grade B). No pregnancy resulted. To improve oocyte quality, the second IVF was performed with a long agonist protocol. Twenty-three oocytes were collected, of which 18 were mature. Once again, 15 oocytes presented abnormalities: 9 of 18 mature oocytes had an abnormal granular cytoplasm, 11 had a fragmented first polar body (1PB), 3 were ovoid, 2 had a large perivitelline space with fragments, and 2 resisted denuding. Eight oocytes presented a single anomaly, 6 had double anomalies, and 2 had triple anomalies or more. Twelve embryos were obtained at day 3. None of them were transferred. They were put back into culture because of the poor embryonic quality. One embryo was transferred at day 5 and was of medium quality (B4ba) and 2 were frozen. No pregnancy resulted. For the transfer of the frozen embryos, we performed 2 cycles of GnRH agonist (Décapeptyl®, Ipsen Pharma, France) and estradiol/progestin (Provames® 6mg, Merus Labs Luxco, Luxembourg and, Utrogestan® 600mg, Besins, France). For the first cycle, a B5bb embryo was transferred and a B4cc was transferred for the second cycle. There was still no pregnancy. The third IVF was performed with a long agonist protocol for which she had had an optimal ovarian response. Since we suspected a negative role of GHD, hormone levels were determined in the blood and FF (Table 2). Once again, 4 of 8 mature oocytes had an abnormal granular cytoplasm, 2 had a fragmented 1PB, and 1 had a large perivitelline space with fragments. Oocytes are shown in Figure 1. Seven embryos were obtained at day 3. None were transferred but were put back into extended culture because of the poor embryo quality (5 grade C and 2 grade D). No blastocyst was obtained at ay 5.

Given that the literature had described ovulation induction and IVF success after GH replacement, we proposed, for the second time, introducing GH replacement before starting a new IVF. As commonly described, a central hypothyroidism was unmasked by the GH

replacement, so we introduced levothyroxine. Therapeutic objectives were to achieve free thyroxine (fT4) levels near the upper normal range and normal free triiodothyronine (fT3) levels, resulting in an IGF1 near the median value of the normal range. It took 10 months to reach the treatment objectives for IGF1, usual time to achieve treatment goals [10]; 262 ng/mL (N: 103-391, median 205), fT4; 16.1 g/mL (N: 9.3-17), fT3; 3.6 pg/mL (N: 2-4.43). The patient's treatment was 1.1 mg/day somatotropin (Norditropine® Simplex, Novo Nordisk, France) and levothyroxine 75 mcg/day (Lévothyrox®, Merck Serono, France).

The fourth IVF was then performed with a short agonist protocol. Five of 8 collected oocytes were mature. None of the oocytes presented anomalies as seen for the previous IVF procedures (Figure 1). Five embryos were obtained at day 3 and one was transferred (Grade A). Two other embryos were frozen at day 3 (Grade A and B).

Hormone levels were determined again in the blood and FF. Blood and FF assays of GH, IGF1, and thyroid hormones were performed the day of oocyte retrieval by immunoassay (Immulite 2000, Siemens Health Care Diagnostic, UK). IGF1 was not detectable in FF before GH replacement. We observed that GH/IGF1 concentrations were increased in blood and FF with GH replacement. fT4 and fT3 levels were increased in follicular fluid, in favor of a partial central hypothyroidism although blood levels were still normal. The absence of thyroid autoimmunity was confirmed. Data on hormone levels are described in Table 2.

Pregnancy was achieved. GH replacement was stopped once the pregnancy was diagnosed. At gestational week 37, she gave birth to a healthy girl weighing 2 500 g without obstetrical or neonatal complications.

Discussion

This case report illustrates the positive effect of GH replacement on IVF outcomes in a patient with acquired hypopituitarism. Initially, our patient did not want GH replacement. There is currently no consensus on the initiation of GH replacement in an adult population with hypopituitarism as there is for standard replacement therapy of glucocorticoids, thyroid hormones, or sex steroids. To date, no study has investigated the effect of GH replacement in patients with hypopituitarism who need IVF. However, GH replacement has previously been shown to improve ovulation induction in GHD and IVF success in poor responders [3,11]. After 3 IVF failures, our patient decided to undergo the advised GH replacement therapy. A central hypothyroidism was then unmasked; this hormonal interaction is well-known [12]. Levothyroxine was then introduced, and we took care to reach the recommended treatment objectives [13], as the fetal outcome is critical. Moreover, thyroid hormones are important in folliculogenesis [14].

Data on women with hypopituitarism are scarce. Effects of GH replacement on ovulation induction in GHD patients were reported in the 1980s [4]. Pregnancy and live birth rates after ovulation induction have been reported in 19 patients: 7 patients received GH replacement and no differences were observed. However, GHD status and treatment objectives were not specified [15]. Improvement in ovulation induction was reported later for 3 women with GHD [3,5,6]. Because IVF is rarely necessary in patients with GHD, only two case reports have demonstrated the impact of GH replacement on IVF results. The first described a positive effect on the endometrium in a failed IVF implantation in a woman with hypopituitarism (GH replacement improved the endometrial thickness resulting in a live birth, no data on oocyte quality were reported) [16]. The second study observed the improvement of oocyte quality during IVF in a patient with isolated GHD such as we observed in our patient. They found normalization of oocyte dysmorphism, including that of granular cytoplasm [7].

Having a priori knowledge of possible effects of GH, we measured GH, IGF1, and thyroid hormones in blood and follicular fluid during the 3rd and 4th IVF procedures, ie, before and after GH replacement. We observed that GH concentrations increased in follicular fluid, demonstrating the passive and/or active passage of blood into follicular fluid. IGF1 levels rose as well, demonstrating the passage and/or effects of GH on IGF1 local synthesis. GH adjuvant treatment in IVF is also associated with increased concentrations of GH and IGF1 in FF in patients without GHD [17]. Two prospective studies in patients without GHD have shown that a higher FF GH concentration is associated with better fertilization and pregnancy rates [18,19]. Abir et al. have shown that GH and GH-receptor (GH-R) are expressed in human ovarian stromal cells, oocytes, and granulosa cells early in folliculogenesis [20]. GH exerts both direct and IGF1-mediated effects on the ovary. GH is involved in the development of primordial to preovulatory human follicles by playing a role in the initiation of growth and survival. GH is also implicated in granulosa and theca cell differentiation, gonadotropin-dependent steroidogenesis, oocyte maturation, and expansion of the cumulus cells [21,22]. Ovarian cells express IGF-receptor I/II (IGFR) [23]. Systemic and/or local IGF1 stimulates proliferation and activity of granulosa cells and their response to gonadotropins. In addition, IGF1 is implicated in the regulation of follicular development and sex-steroid production [22]. IGF1 mRNA has been detected in human granulosa cells and in different animal models [22], so local IGF1 secretion could also be stimulated by GH replacement in GHD patients.

GH mechanisms improving ovulation are not well understood, but a synergistic effect has been described with gonadotropin. In ovarian stimulation in patients without GHD, GH adjuvant treatment has reduced the duration and dose of gonadotropin in ovulation induction and IVF [24,25]. Mean E2 levels were significantly increased on the day of hCG administration [25]. FF E2 concentrations were also raised after GH adjuvant treatment, and

correlated with FF GH concentration [17,18,21]. Regan et al. demonstrated that GH adjuvant treatment increased the gonadotropin and GH receptor density in granulosa cells, which can improve gonadotropin response [26].

The role of thyroid hormones has to be discussed since it has been shown that TSH and thyroid hormones are detected in human FF [27] and their receptors are detected in granulosa cells and oocytes [28]. Thyroid hormones play a role in folliculogenesis. fT3 improves granulosa cell proliferation [14] and inhibits granulosa cell apoptosis [29]. Thyroid hormones participate in steroidogenesis by increasing estradiol and progesterone secretion by granulosa cells [30]. Moreover, it has been demonstrated that untreated subclinical hypothyroidism is associated with adverse reproductive outcomes after IVF, such as increased miscarriage and low delivery rate [31]. Supplementation of subclinical hypothyroidism by levothyroxine (LT4) increases embryonic quality, pregnancy, and delivery rates and decreases miscarriage [32]. However, no study has evaluated the impact of hypothyroidism on oocyte quality. Thyroid hormone levels in our patient were not optimal during the first 3 IVF procedures. Since central hypothyroidism was unmasked by GH replacement, we believe that levothyroxine replacement should have been initiated before the upper normal range of fT4 was reached. However, fT4 was within the normal range, which is why we conclude that GH effects were predominant in the improvement of oocyte quality.

The ICSI technique through egg denudation is helpful in assessing oocyte quality prior to fertilization. With hormonal replacement, the oocyte quality of our patient dramatically improved. Oocyte abnormalities, such as an abnormal granular cytoplasm, were no longer present. Moreover, we observed an improvement in embryonic quality, allowing an embryo transfer resulting in a successful pregnancy. No prospective study has evaluated oocyte and embryo quality and/or the impact of GH replacement on IVF outcomes in

patients with hypopituitarism. For our patient, 62% and 100% of mature oocytes presented abnormal morphology: diffuse cytoplasmic granularity, large perivitelline space with fragments, ovoid shape, difficult denuding, and 1BP fragmentation, which is higher compared to typical patients. In the literature, 10 to 50% of oocytes present dysmorphism after IVF stimulation [33]. Overall, morphological variations in the oocyte may result from intrinsic factors such as age and genetic defects, or extrinsic factors such as stimulation protocols, culture conditions, and nutrition. For the third and fourth IVF attempts, we used agonist protocols with the same type and dose of gonadotropin as well as the same conditions of embryo culture. We can then assume that it is GH replacement that improved oocyte and embryo quality in terms of biological changes in follicular fluids and the positive outcome. Many studies have evaluated the impact of oocyte dysmorphism in IVF results, but it is still debatable due to study design and variability in the characterization criteria. It has been shown that oocytes with abnormal granular cytoplasm have lower fertility rates and poorer embryo quality [34]. Decreased survival and impaired in vitro development after cryopreservation of embryos deriving from oocytes with central granulation have been reported [35]. Cellular mechanisms leading to granular cytoplasm are not known; however, mitochondrial dysfunction and endoplasmic reticulum abnormalities are suspected [33,34].

In addition to GH replacement, GH adjuvant treatment has been proposed to improve IVF outcomes in-patients without GHD. Many studies have assessed the impact of GH adjuvant treatment on IVF success rates in poor responders. Four meta-analyses and a Cochrane review have evaluated the benefits of GH therapy during ovarian stimulation. It has been shown to significantly improve pregnancy and live birth rates by increasing the number of oocytes collected, but no effects were described on oocyte and embryo quality [36–40]. In normo-ovulatory patients, the effect of GH adjuvant treatment is still being debated. A Cochrane review and prospective studies did not observe a significant difference

in the number of oocytes collected or pregnancy and live birth rates [38,41,42], whereas one recent randomized controlled trail (RCT) and retrospective studies have demonstrated beneficial effects on live birth rate [26,43]. In patients with multiple IVF failures, two prospective controlled studies and one retrospective study found that GH therapy significantly improved the number of oocytes collected and the pregnancy and live birth rates [44–46]. Considering our results and those found in the literature, we assume that the GH/IGF1 system plays a role in repairing oocyte abnormalities.

The role of oocyte modification on a successful IVF outcome and pregnancy could be challenged by the GH endometrial effect. Few studies have evaluated the impact of GH adjuvant treatment on endometrial function. One RCT and one prospective controlled study in-patients without GHD evaluated frozen–thawed embryo transfer with hormone-replacement therapy for endometrial preparation. They observed that endometrial thickness as well as pregnancy and live birth rates were significantly higher with GH adjuvant treatment. GH could also improve clinical outcomes after IVF by increasing endometrial blood perfusion and expression of cytokines related to endometrial receptivity [47,48]. In our patient, endometrial thickness and appearance were normal before all embryo transfers. Thus, we can assume that this mechanism was not implicated.

GH replacement was discontinued at the time of pregnancy diagnosis. Our patient gave birth at 37 gestational weeks without obstetrical or neonatal complications. While isolated cases of GH deficiency do not seem to have more obstetrical complications than normal patients [49], pregnancy in patients with GH deficiency and hypopituitarism, particularly in cases of childhood-onset deficiencies, seem to have a higher obstetric risk. Retrospective studies have observed a higher risk of miscarriage, transverse lie, caesarian section, birth weight under the 10th centile, and very poor obstetrical outcomes for twin pregnancies [15,50,51]. In patients with hypopituitarism, Thus, IVF double embryo transfers

must not be performed so that twin pregnancies can be avoided. The debate over whether or not to continue GH treatment during pregnancy is not over. A large retrospective study compared the obstetrical outcomes in 3 groups of 173 women with hypopituitarism. The groups consisted of patients without GH treatment, with GH replacement until the end of the second trimester, and with GH treatment throughout the entire pregnancy. The live birth rate, the gestational week at delivery, the birth weight, and the obstetric outcomes were the same in the 3 groups [51]. During pregnancy, placental GH secretion increases throughout pregnancy, with a peak at 36 gestational weeks. Placental GH has a stronger affinity for GH receptors than pituitary GH, so it replaces maternal GH which becomes undetectable in the serum after 24 weeks, so placental GH controls maternal IGF1 levels [52]. Placental GH control of fetal growth and intra-uterine growth retardation has been observed in patients with low placental GH levels [53]. Since a similar rise in placental GH and IGF-1 is present in women with GHD, this seems sufficient for a normal pregnancy and healthy fetus [54]. The Endocrine Society recommends discontinuing GH replacement during pregnancy because of the lack of evidence for an additional benefit [51,55].

Conclusions

In patients with hypopituitarism wishing a pregnancy, GH replacement may be part of the preparation for optimal folliculogenesis. In clinical practice, endocrinologists and gynecologists should work together in the management of appropriate hormonal replacement during ovulation induction and/or IVF in these patients. Research on oocyte quality needs to be conducted. Animal models could be useful for explaining GH and thyroid hormone effects on oocyte quality, growth, and maturation in culture.

REFERENCES

[1] Chandrashekar V, Zaczek D, Bartke A. The consequences of altered somatotropic system on reproduction. Biol Reprod 2004;71:17–27. doi.org/10.1095/biolreprod.103.027060.

[2] Karamouti M, Kollia P, Kallitsaris A, Vamvakopoulos N, Kollios G, Messinis IE. Growth hormone, insulin-like growth factor I, and leptin interaction in human cultured lutein granulosa cells steroidogenesis. Fertil Steril 2008;90:1444–50. doi.org/10.1016/j.fertnstert.2007.08.076.

[3] Daniel A, Ezzat S, Greenblatt E. Adjuvant growth hormone for ovulation induction with gonadotropins in the treatment of a woman with hypopituitarism. Case Rep Endocrinol 2012;2012:356429. doi.org/10.1155/2012/356429.

[4] Blumenfeld Z, Lunenfeld B. The potentiating effect of growth hormone on follicle stimulation with human menopausal gonadotropin in a panhypopituitary patient. Fertil Steril 1989;52:328–31. doi.org/10.1016/s0015-0282(16)60864-6.

[5] Salle A, Klein M, Pascal-Vigneron V, Dousset B, Leclere J, Weryha G. Successful pregnancy and birth after sequential cotreatment with growth hormone and gonadotropins in a woman with panhypopituitarism: a new treatment protocol. Fertil Steril 2000;74:1248–50.

[6] Park JK, Murphy AA, Bordeaux BL, Dominguez CE, Session DR. Ovulation induction in a poor responder with panhypopituitarism: a case report and review of the literature. Gynecol Endocrinol 2007;23:82–6. doi.org/10.1080/09513590601137533.

[7] Albu D, Albu A. Is growth hormone administration essential for in vitro fertilization treatment of female patients with growth hormone deficiency? Syst Biol Reprod Med 2019;65:71–4. doi.org/10.1080/19396368.2018.1492044.

[8] Alpha Scientists in Reproductive Medicine and ESHRE Special Interest Group of Embryology. The Istanbul consensus workshop on embryo assessment: proceedings of an expert meeting. Hum Reprod 2011;26:1270–83. doi.org/10.1093/humrep/der037.

[9] Gardner DK, Schoolcraft WB. Culture and transfer of human blastocysts. Curr Opin Obstet Gynecol 1999;11:307–11. doi.org/10.1097/00001703-199906000-00013.

[10] Borson-Chazot F, Chabre O, Salenave S, Klein M, Brac de la Perriere A, Reznik Y, et al. Adherence to growth hormone therapy guidelines in a real-world French cohort of adult patients with growth hormone deficiency. Ann Endocrinol 2021;82:59–68. doi.org/10.1016/j.ando.2020.11.007.

[11] Bergh C, Hillensjö T, Wikland M, Nilsson L, Borg G, Hamberger L. Adjuvant growth hormone treatment during in vitro fertilization: a randomized, placebo-controlled study. Fertil Steril 1994;62:113–20.

[12] Agha A, Walker D, Perry L, Drake WM, Chew SL, Jenkins PJ, et al. Unmasking of central hypothyroidism following growth hormone replacement in adult hypopituitary patients. Clin Endocrinol (Oxf) 2007;66:72–7. doi.org/10.1111/j.1365-2265.2006.02688.x.

[13] Alexander EK, Pearce EN, Brent GA, Brown RS, Chen H, Dosiou C, et al. 2017 Guidelines of the American Thyroid Association for the Diagnosis and Management of Thyroid Disease During Pregnancy and the Postpartum. Thyroid 2017;27:315–89. doi.org/10.1089/thy.2016.0457.

[14] Goldman S, Dirnfeld M, Abramovici H, Kraiem Z. Triiodothyronine and follicle-stimulating hormone, alone and additively together, stimulate production of the tissue inhibitor of metalloproteinases-1 in cultured human luteinized granulosa cells. J Clin Endocrinol Metab 1997;82:1869–73.
[15] Hall R, Manski-Nankervis J, Goni N, Davies MC, Conway GS. Fertility outcomes in women with hypopituitarism. Clin Endocrinol (Oxf) 2006;65:71–4. doi.org/10.1111/j.1365-2265.2006.02550.x.
[16] Drakopoulos P, Pluchino N, Bischof P, Cantero P, Meyer P, Chardonnens D. Effect of Growth Hormone on Endometrial Thickness and Fertility Outcome in the Treatment of Women with Panhypopituitarism: A Case Report. J Reprod Med 2016;61:78–82.
[17] Hughes SM, Huang ZH, Matson PL, Buck P, Lieberman BA, Morris ID. Clinical and endocrinological changes in women following ovulation induction using buserelin acetate/human menopausal gonadotrophin augmented with biosynthetic human growth hormone. Hum Reprod 1992;7:770–5. doi.org/10.1093/oxfordjournals.humrep.a137735.
[18] Mendoza C, Ruiz-Requena E, Ortega E, Cremades N, Martinez F, Bernabeu R, et al. Follicular fluid markers of oocyte developmental potential. Hum Reprod 2002;17:1017–22.
[19] Mendoza C, Cremades N, Ruiz-Requena E, Martinez F, Ortega E, Bernabeu S, et al. Relationship between fertilization results after intracytoplasmic sperm injection, and intrafollicular steroid, pituitary hormone and cytokine concentrations. Hum Reprod 1999;14:628–35.
[20] Abir R, Garor R, Felz C, Nitke S, Krissi H, Fisch B. Growth hormone and its receptor in human ovaries from fetuses and adults. Fertil Steril 2008;90:1333–9. doi.org/10.1016/j.fertnstert.2007.08.011.
[21] Bergh C, Carlström K, Selleskog U, Hillensjö T. Effect of growth hormone on follicular fluid androgen levels in patients treated with gonadotropins before in vitro fertilization. Eur J Endocrinol 1996;134:190–6.
[22] Silva JRV, Figueiredo JR, van den Hurk R. Involvement of growth hormone (GH) and insulin-like growth factor (IGF) system in ovarian folliculogenesis. Theriogenology 2009;71:1193–208. doi.org/10.1016/j.theriogenology.2008.12.015.
[23] Qu J, Godin PA, Nisolle M, Donnez J. Expression of receptors for insulin-like growth factor-I and transforming growth factor-beta in human follicles. Mol Hum Reprod 2000;6:137–45.
[24] Homburg R, Eshel A, Abdalla HI, Jacobs HS. Growth hormone facilitates ovulation induction by gonadotrophins. Clin Endocrinol (Oxf) 1988;29:113–7. doi.org/10.1111/j.1365-2265.1988.tb00252.x.
[25] Dakhly DMR, Bassiouny YA, Bayoumi YA, Hassan MA, Gouda HM, Hassan AA. The addition of growth hormone adjuvant therapy to the long down regulation protocol in poor responders undergoing in vitro fertilization: Randomized control trial. Eur J Obstet Gynecol Reprod Biol 2018;228:161–5. doi.org/10.1016/j.ejogrb.2018.06.035.
[26] Regan SLP, Knight PG, Yovich JL, Arfuso F, Dharmarajan A. Growth hormone during in vitro fertilization in older women modulates the density of receptors in granulosa cells, with improved pregnancy outcomes. Fertil Steril 2018;110:1298–310. doi.org/10.1016/j.fertnstert.2018.08.018.

[27] Wakim AN, Polizotto SL, Buffo MJ, Marrero MA, Burholt DR. Thyroid hormones in human follicular fluid and thyroid hormone receptors in human granulosa cells. Fertil Steril 1993;59:1187–90.
[28] Aghajanova L, Lindeberg M, Carlsson IB, Stavreus-Evers A, Zhang P, Scott JE, et al. Receptors for thyroid-stimulating hormone and thyroid hormones in human ovarian tissue. Reprod Biomed Online 2009;18:337–47.
[29] Verga Falzacappa C, Mangialardo C, Patriarca V, Bucci B, Amendola D, Raffa S, et al. Thyroid hormones induce cell proliferation and survival in ovarian granulosa cells COV434. J Cell Physiol 2009;221:242–53. doi.org/10.1002/jcp.21849.
[30] Wakim AN, Polizotto SL, Burholt DR. Augmentation by thyroxine of human granulosa cell gonadotrophin-induced steroidogenesis. Hum Reprod 1995;10:2845–8.
[31] Scoccia B, Demir H, Kang Y, Fierro MA, Winston NJ. In vitro fertilization pregnancy rates in levothyroxine-treated women with hypothyroidism compared to women without thyroid dysfunction disorders. Thyroid 2012;22:631–6. doi.org/10.1089/thy.2011.0343.
[32] Kim C-H, Ahn J-W, Kang SP, Kim S-H, Chae H-D, Kang B-M. Effect of levothyroxine treatment on in vitro fertilization and pregnancy outcome in infertile women with subclinical hypothyroidism undergoing in vitro fertilization/intracytoplasmic sperm injection. Fertil Steril 2011;95:1650–4. doi.org/10.1016/j.fertnstert.2010.12.004.
[33] Sousa M, Cunha M, Silva J, Oliveira E, Pinho MJ, Almeida C, et al. Ultrastructural and cytogenetic analyses of mature human oocyte dysmorphisms with respect to clinical outcomes. J Assist Reprod Genet 2016;33:1041–57. doi.org/10.1007/s10815-016-0739-8.
[34] Rienzi L, Vajta G, Ubaldi F. Predictive value of oocyte morphology in human IVF: a systematic review of the literature. Hum Reprod Update 2011;17:34–45. doi.org/10.1093/humupd/dmq029.
[35] Balaban B, Ata B, Isiklar A, Yakin K, Urman B. Severe cytoplasmic abnormalities of the oocyte decrease cryosurvival and subsequent embryonic development of cryopreserved embryos. Hum Reprod 2008;23:1778–85. doi.org/10.1093/humrep/den127.
[36] Hart RJ. Use of Growth Hormone in the IVF Treatment of Women With Poor Ovarian Reserve. Front Endocrinol 2019;10. doi.org/10.3389/fendo.2019.00500.
[37] Li X-L, Wang L, Lv F, Huang X-M, Wang L-P, Pan Y, et al. The influence of different growth hormone addition protocols to poor ovarian responders on clinical outcomes in controlled ovary stimulation cycles: A systematic review and meta-analysis. Medicine (Baltimore) 2017;96:e6443. doi.org/10.1097/MD.0000000000006443.
[38] Harper K, Proctor M, Hughes E. Growth hormone for in vitro fertilization. Cochrane Database Syst Rev 2003:CD000099. doi.org/10.1002/14651858.CD000099.
[39] Yu X, Ruan J, He L-P, Hu W, Xu Q, Tang J, et al. Efficacy of growth hormone supplementation with gonadotrophins in vitro fertilization for poor ovarian responders: an updated meta-analysis. Int J Clin Exp Med 2015;8:4954–67.
[40] Hart RJ, Rombauts L, Norman RJ. Growth hormone in IVF cycles: any hope? Curr Opin Obstet Gynecol 2017;29:119–25. doi.org/10.1097/GCO.0000000000000360.
[41] Shaker AG, Fleming R, Jamieson ME, Yates RW, Coutts JR. Absence of effect of adjuvant growth hormone therapy on follicular responses to exogenous gonadotropins in women: normal and poor responders. Fertil Steril 1992;58:919–23. doi.org/10.1016/s0015-0282(16)55435-1.

[42] Younis JS, Simon A, Koren R, Dorembus D, Schenker JG, Laufer N. The effect of growth hormone supplementation on in vitro fertilization outcome: a prospective randomized placebo-controlled double-blind study. Fertil Steril 1992;58:575–80. doi.org/10.1016/s0015-0282(16)55266-2.
[43] Chu K, Pang W, Sun N, Zhang Q, Li W. Outcomes of poor responders following growth hormone co-treatment with IVF/ICSI mild stimulation protocol: a retrospective cohort study. Arch Gynecol Obstet 2018;297:1317–21. doi.org/10.1007/s00404-018-4725-5.
[44] Hazout A, Junca A, De Mouzon J, Cohen-Bacrie P. Effect of growth hormone on oocyte competence in patients with multiple IVF failures. Reprod Biomed Online 2009;18:664–70. doi.org/10.1016/S1472-6483(10)60011-9.
[45] Chen Y, Liu F, Nong Y, Ruan J, Guo Q, Luo M, et al. Clinical efficacy and mechanism of growth hormone action in patients experiencing repeat implantation failure. Can J Physiol Pharmacol 2018;96:929–32. doi.org/10.1139/cjpp-2017-0786.
[46] Shirlow R, Healey M, Volovsky M, MacLachlan V, Vollenhoven B. The Effects of Adjuvant Therapies on Embryo Transfer Success. J Reprod Infertil 2017;18:368–78.
[47] Cui N, Li A-M, Luo Z-Y, Zhao Z-M, Xu Y-M, Zhang J, et al. Effects of growth hormone on pregnancy rates of patients with thin endometrium. J Endocrinol Invest 2019;42:27–35. doi.org/10.1007/s40618-018-0877-1.
[48] Xue-Mei W, Hong J, Wen-Xiang Z, Yang L. The effects of growth hormone on clinical outcomes after frozen-thawed embryo transfer. Int J Gynaecol Obstet 2016;133:347–50. doi.org/10.1016/j.ijgo.2015.10.020.
[49] Sakai S, Wakasugi T, Yagi K, Ohnishi A, Ito N, Takeda Y, et al. Successful pregnancy and delivery in a patient with adult GH deficiency: role of GH replacement therapy. Endocr J 2011;58:65–8.
[50] Overton CE, Davis CJ, West C, Davies MC, Conway GS. High risk pregnancies in hypopituitary women. Hum Reprod 2002;17:1464–7. doi.org/10.1093/humrep/17.6.1464.
[51] Vila G, Akerblad A-C, Mattsson AF, Riedl M, Webb SM, Hána V, et al. Pregnancy outcomes in women with growth hormone deficiency. Fertil Steril 2015;104:1210-1217.e1. doi.org/10.1016/j.fertnstert.2015.07.1132.
[52] Lønberg U, Damm P, Andersson A-M, Main KM, Chellakooty M, Lauenborg J, et al. Increase in maternal placental growth hormone during pregnancy and disappearance during parturition in normal and growth hormone-deficient pregnancies. Am J Obstet Gynecol 2003;188:247–51. doi.org/10.1067/mob.2003.82.
[53] Vila G, Luger A. Growth hormone deficiency and pregnancy: any role for substitution? Minerva Endocrinol 2018;43:451–7. doi.org/10.23736/S0391-1977.18.02834-1.
[54] Verhaeghe J, Bougoussa M, Van Herck E, de Zegher F, Hennen G, Igout A. Placental growth hormone and IGF-I in a pregnant woman with Pit-1 deficiency. Clin Endocrinol (Oxf) 2000;53:645–7.
[55] Fleseriu M, Hashim IA, Karavitaki N, Melmed S, Murad MH, Salvatori R, et al. Hormonal Replacement in Hypopituitarism in Adults: An Endocrine Society Clinical Practice Guideline. J Clin Endocrinol Metab 2016;101:3888–921. doi.org/10.1210/jc.2016-2118.

TABLES

Table 1**: In vitro fecundation (IVF) characteristics**

Ovitrelle®: choriogonadotropin alpha
Menopur® 225 IU Menotropin, FSH and LH activity
Cetrotide®: cetrorelix
Decapeptyl®: triptoreline

[a]Istanbul consensus, [b]Gardner classification

	1st IVF 12/2011	**2nd IVF 06/2012**	**3rd IVF 04/2013**	**4th IVF 07/2014**
Ovarian Stimulation Protocol	Antagonist: Cetrotide® Menopur® 225 IU	Long agonist: Decapeptyl® Menopur® 112.5 IU	Long agonist: Decapeptyl® Menopur® 100 IU	Short agonist: Decapeptyl® Menopur®100IU
Ovulation trigger	Ovitrelle®	Ovitrelle®	Ovitrelle®	Ovitrelle®
Total oocytes (n)	12	23	12	8
Mature oocytes (n/%)	9 (75%)	18 (78%)	8 (66%)	5 (62.5%)
Abnormal oocytes (n/%)	9 (100%)	15 (83%)	5 (62%)	0
- **With 1 anomaly**	5 (55%)	8 (44%)	2 (25%)	
- **With 2 anomalies**	4 (45%)	6 (33%)	2 (25%)	
- **With 3 anomalies**	0	2 (11%)	1 (12.5)	
Type of anomalies				
- ***Granular oocytes***	9	9	4	
- ***Wide perivitelline space***	0	2	0	
- ***Ovoid shape***	0	3	1	
- ***Difficult denudation***	4	2	0	
- ***Fragmented first polar body***	0	11	2	
Fertilization rate (%)	88	66.6	87.5	100
Total embryos, Day 3 (n)	8	12	7	5
Grade [a] ***A/B/C/D***	0/1/3/5	0/2/5/5	0/0/5/2	2/3/0/0
Extended culture	No	Yes	Yes	Yes
Blastocysts (n)		3	0	2
Frozen embryo (n)	0	2	0	2
Transferred embryos			0	
- ***Day 3***	1 (Grade B)			1 (Grade A)
- ***Day 5***[b]		1 (B4ba)		
Transfer of frozen embryos (day 5)	0	1 (B5bb) 1 (B4cc)	0	0
Pregnancy	No	No		Yes

Table 2: Hormonal and antithyroid antibody levels in blood and follicular fluids (FF)

	Before IVF procedure	**During the 3rd IVF Before GH replacement 2013**	**During the 4th IVF with GH and L-thyroxine replacement 2014**

Fluid	Blood	Blood	FF	Blood	FF
Collection time		**13:00 h**	**09:00 h**	**13:00 h**	**09:00 h**
GH (<15 mIU/L)		1.39	1.39	2.95	7.68
IGF1 (108-247; median 193 ng/mL)	<25	<25	<25	153	109
TSH (0.4-4 mIU/L)	1.59	2.71	1.6	0.16	0.12
fT4 (0.75-1.45 ng/dL)	0.87	0.78	0.84	1.28	1.45
fT3 (3.4-6,1 pmol/L)	4.42	3.1	2.5	3.8	3.7
anti-TPO Ab (<60)		53.8	<30	<28	<30
anti-Tg Ab (<30)		<30	<30	<30	<30

Abbreviations: Ab: antibody, IVF: in vitro fecundation, GH: Growth hormone, IGF1: Insulin-like growth factor, TSH: thyroid stimulated hormone, fT3: Free triiodothyronine, fT4: Free thyroxine, TPO : thyroperoxidase, TG: thyroglobulin

FIGURES
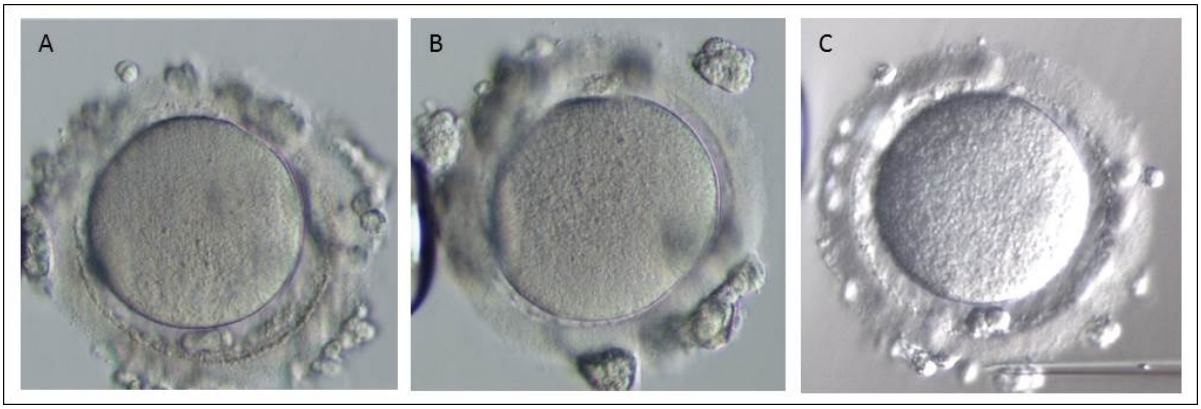
Figure 1: Meta II oocyte quality before (A and B) and after GH treatment (C): (A) Diffuse cytoplasmic granularity, large perivitelline space with fragments, and fragmented first polar body. (B) Diffuse cytoplasmic granularity and fragmented first polar body. (C) Normal oocyte.