



## Caractéristiques morphologiques de la papille optique chez le prématuré. Influence de l'âge gestationnel et du poids de naissance

R. Bouzerar, O. Madar, Pierre Tourneux, C. Couteaux, B. Jany, Véronique Promelle

### ► To cite this version:

R. Bouzerar, O. Madar, Pierre Tourneux, C. Couteaux, B. Jany, et al.. Caractéristiques morphologiques de la papille optique chez le prématuré. Influence de l'âge gestationnel et du poids de naissance. Journal Français d'Ophtalmologie, 2021, 44 (10), pp.1584-1588. 10.1016/j.jfo.2021.03.009 . hal-03688453

**HAL Id: hal-03688453**

**<https://u-picardie.hal.science/hal-03688453>**

Submitted on 5 Jan 2024

**HAL** is a multi-disciplinary open access archive for the deposit and dissemination of scientific research documents, whether they are published or not. The documents may come from teaching and research institutions in France or abroad, or from public or private research centers.

L'archive ouverte pluridisciplinaire **HAL**, est destinée au dépôt et à la diffusion de documents scientifiques de niveau recherche, publiés ou non, émanant des établissements d'enseignement et de recherche français ou étrangers, des laboratoires publics ou privés.



Distributed under a Creative Commons Attribution - NonCommercial 4.0 International License

Optic disc morphology in preterm children. Influence of gestational age and birth weight.

Caractéristiques morphologiques de la papille optique chez le prématuré.  
Influence de l'âge gestationnel et du poids de naissance.

## Abstract

**Purpose:** The characteristics of the optic disc and the development of the optic nerve can affect visual function in children. The purpose of our study was to assess optic disc morphology in preterm infants and to determine whether it is influenced by gestational age, birth weight and the presence of a retinopathy of prematurity.

**Methods:** In a retrospective study, RetCam fundus images of 109 premature newborns admitted to our tertiary-level neonatal intensive care unit were reviewed. We evaluated the cup to disc ratio (C/D), optic disc diameter, cup diameter, shape of the optic disc, adherence to the ISNT rule, and presence of a peripapillary atrophy.

**Results:** Of 218 photos, we found the following results: mean  $\pm$ SD gestational age  $28.5 \pm 2.7$  weeks, mean  $\pm$ SD birth weight  $1122 \pm 394$  g, mean C/D 0.32. There was no significant correlation between C/D and gestational age or birth weight. Vertical disc diameter was greater than horizontal disc diameter, with a mean ratio (horizontal / vertical) of 4/5, lending an oval shape to the optic disc. Nineteen infants had retinopathy of prematurity in both eyes; ninety-three percent had peripapillary atrophy.

**Conclusion:** In our study, optic disc morphology in premature newborns was not influenced by gestational age, birth weight or presence of premature retinopathy.

**Keywords:** optic disc, prematurity, cup to disc ratio, gestational age, birth weight

## Résumé

**But :** Les caractéristiques de la papille et le développement du nerf optique peuvent modifier la fonction visuelle chez les enfants. L'objectif de notre étude était d'étudier la morphologie de la papille optique chez les nouveau-nés prématurés et de déterminer si elle est influencée par l'âge gestationnel, le poids de naissance et la présence d'une rétinopathie du prématuré.

**Méthodes :** Dans une étude rétrospective, des clichés RetCam du fond d'œil de 109 prématurés hospitalisés dans notre unité néonatale de soins intensifs de niveau 3 ont été analysés. Nous avons évalué le rapport cup-disc (C/D), le diamètre et la forme de la papille optique, le diamètre de l'excavation, le respect de la règle ISNT et la présence d'une atrophie péripapillaire.

**Résultats :** Sur 218 clichés, nous avons trouvé les résultats suivant : âge gestationnel moyen  $28,5 \pm 2,7$  semaines; poids de naissance moyen  $1122 \pm 393,9$ g. Le C/D moyen était 0,32. Il n'y avait pas de corrélation significative entre le C/D et l'âge gestationnel ou le poids de naissance ( $p > 0,05$ ). Le diamètre vertical du disque était supérieur au diamètre horizontal avec un ratio moyen (horizontal/vertical) de 4/5 donnant une forme ovale. Dix-neufs enfants avaient une rétinopathie du prématuré, 93% présentait une atrophie péripapillaire.

**Conclusion :** Dans notre étude, la morphologie de la papille optique des nouveau-nés prématurés n'était pas modifiée par l'âge gestationnel, le poids de naissance ou la présence d'une rétinopathie du prématuré.

**Mots-clés :** Papille optique, prématurité, rapport cup-disc, âge gestationnel, poids de naissance

## Introduction

Prematurity is responsible for high childhood morbidity, including visual impairment.

The latter is mostly caused by retinopathy of prematurity, but optic disc anomalies, refractive errors and strabismus are additional risk factors of amblyopia.

Only few studies reported on the optic disc morphology in premature infants. The correlation between optic disc morphology and birth weight or gestational age is unclear. Some authors found no correlation between the optic disc C/D and birth weight or gestational age <sup>1</sup>, disc size or disc area <sup>2,3</sup>. In opposition, other researchers suggested that a low birth weight could influence the shape of the optic disc <sup>4</sup>, with a lower birth weight or gestational age being associated to a larger cup to disc ratio (C/D)<sup>5</sup> and either larger area of the optic disc <sup>3</sup> or smaller optic disc diameter <sup>6</sup>.

Therefore, this study aimed to describe the optic disc morphology in premature infants and how the C/D and the disc diameter are correlated to birth weight, gestational age and the presence of a retinopathy of prematurity.

## Methods

This retrospective, non-interventional study was conducted in accordance with tenets of the Declaration of Helsinki and was approved by the Amiens Hospital institutional ethical review board.

Consecutive patients undergoing digital retinophotography for screening for retinopathy of prematurity in our tertiary-level neonatal intensive care unit were retrospectively included. The screening for retinopathy of prematurity was decided according to the national guidelines. Thus, 109 premature infants born before 31 post menstrual weeks with a birth weight of 1250 g or less, or a birth weight of 2000 g or less and intensive oxygen support, sepsis, or vasoactive medication support, were included. In addition, some patients that did not meet the criteria were examined if the neonatologist had concerns in regards to a low birth weight, prolonged sepsis or intensive oxygen support. The fundus examination was performed at the corrected age of 31 weeks ( $\pm 2$  weeks) or at 4 weeks of post-natal age, whichever occurred earlier. Eyes with no clear visible fundus or bad quality of digital fundus images were excluded from this study.

Pupil dilation was obtained with phenylephrine 2.5% and tropicamide 0.5% instilled in both eyes by the nursery nurse 1 hour before screening, while cardiac rate and oxygen saturation were continuously monitored. Prior to examination, oxybuprocain eyedrops were instilled to anesthetize the cornea and to enable the placement of an eyelid speculum. Digital images of both fundi were obtained using a digital fundus camera (RetCam Clarity medical Systems Inc, Pleasanton, CA, USA) with the wide angle 130° head. The protocol included pictures from the posterior pole, then the superior, nasal, inferior and temporal periphery. The examination was performed by an ophthalmologist who made sure the images needed for ROP screening were

obtained. Only the clearest image of the posterior pole for each eye was afterwards selected in our study by an investigator (C.C) to measure the optic disc. All selected images were analyzed with the software Image J. The optic disc diameter and the cup diameter were measured by carefully delineating the outline with a cursor. The measures were performed by a single investigator (C.C) trained to the use of the software and masked to the patient's gestational age and birth weight. Distances between the points were displayed in number of pixels. The vertical optic disc diameter was defined as the distance between the upper and the lower poles of the disc. Similarly, the horizontal disc diameter was the distance measured between the most temporal and the most nasal point of the disc. Normalized diameters were calculated as follow:  $\text{Normalized diameter} = \text{diameter} / (\text{mean of diameter in the study population})$  and were used for statistical analysis. The vertical and horizontal cup to disc ratio (C/D) were calculated as follow, respectively:  $\text{cup vertical diameter} / \text{disc vertical diameter}$ , and  $\text{cup horizontal diameter} / \text{disc horizontal diameter}$ .

Additionally, the respect of the ISNT rule of the disc, stating that the rim should be wider in the inferior than superior, than nasal, than temporal side of the disc, and the presence of a peripapillary atrophy were evaluated by the same investigator on a "yes/no" basis. The presence of a retinopathy of prematurity was noted.

The correlation between disc vertical and horizontal normalized diameters, and C/D, with birth weight, gestational age was evaluated using a Pearson correlation test. Finally, the included patients were distributed in subgroups according to gestational age (less than 27 weeks, 27 to 31 weeks, 32 to 34 weeks, and 35 weeks or more), birth weight (less than 800g, 800 to 1199g, 1200 to 1499g, 1500 to 1999, and 2000g or more) and presence of a retinopathy of prematurity. The normalized disc vertical diameter and the C/D were compared between subgroups using a Mann Whitney

test. The degree of asymmetry in the disc diameter and in the C/D in each eye of a patient was assessed using a Wilcoxon paired analysis, in the whole population. A p-value of  $<0.05$  was considered statistically significant.



## Results

We assessed 218 images of the left and right eyes of 109 infants (57 male and 52 female). Mean  $\pm$  Standard deviation (SD) [range] gestational age was  $28.5 \pm 2.7$  weeks [24-37 weeks] and mean birth weight was  $1122 \pm 392.9$  g [500 – 2700]. Nineteen of 109 infants had retinopathy of prematurity. Among them, 11 had to be treated by laser or intravitreal injection of bevacizumab.

In 28 eyes of 19 patients, C/D couldn't be evaluated due to inability of accurately measure the cup diameter. The patients whom C/D could not be evaluated didn't have a significantly different birth weight ( $p=0.07$ ) or gestational age ( $p=0.73$ ) from the other included patients. The mean  $\pm$  SD horizontal C/D was  $0.32 \pm 0.06$  and the mean  $\pm$ SD vertical C/D was  $0.32 \pm 0.07$ .

There was no significant correlation between the C/D and the birth weight ( $p=-0.0535$ ,  $p=0.48$  and  $p=-0.0525$ ,  $p=0.49$  for vertical and horizontal C/D, respectively) or between the C/D and the gestational age ( $p=0.0881$ ,  $p=0.24$  and  $p=0.0278$ ,  $p=0.71$  for vertical and horizontal C/D, respectively) (Figure 1). The horizontal and vertical C/D values in the subgroups according to gestational age and birth weight are detailed in Table 1. There was no difference either in the C/D between the patients who developed a retinopathy of prematurity and those who didn't. When compared to each other, we found no significant difference in the horizontal or vertical C/D between the right and left eyes ( $p=0.12$  and  $p=0.11$  respectively).

The vertical disc diameter was superior to the horizontal disc diameter with a mean (horizontal / vertical) ratio of 4/5. The normalized vertical disc diameter showed no significant correlation with the gestational age ( $p=-0.0587$ ,  $p=0.44$ ) or with the birth weight ( $p=-0.0735$ ,  $p=0.33$ ). Similarly, the horizontal disc diameter was not correlated with gestational age or birth weight ( $p=-0.0057$ ,  $p=0.94$  and  $p=-0.0518$ ,  $p=0.49$

respectively). The eyes with retinopathy of prematurity had a smaller disc vertical diameter than the eyes without retinopathy ( $p=0.02$ ) although there was no significant difference between the vertical disc diameter between the babies of less than 27 weeks of gestational age and the babies of more than 32 weeks (including groups 32 to 34 and  $>34$  weeks,  $p=0.11$ ) or more than 35 weeks ( $p=0.26$ ) and no difference between the patients with a birth weight of less than 800g and more than 2000g ( $p=0.30$ ). When compared to each other, we found no significant difference in the horizontal or vertical disc diameter between the right and left eyes ( $p=0.11$  and  $p=0.29$  respectively).

We found that 93.8% of all eyes respected the ISNT rule. In patients with a gestational age of less than 27 weeks the ISNT rule was respected in 91.8% of the eyes, 94.2% of eyes if 27 to 31 weeks, 95.2% if 32 to 34 weeks and 100% if 35 weeks or more. The birth weight and the presence of a retinopathy of prematurity did not seem to have any influence on the respect of ISNT rule. A peripapillary atrophy was found in 93.26% of eyes. This atrophic ring was absent in 4 eyes of 2 patients born before 27 weeks (birth weight of 650g and 1040g) and in 8 eyes of 4 patients born between 27 and 31 weeks (birth weight of 800, 1175, 1180 and 1320g), none of them having retinopathy of prematurity.

## Discussion

In this population-based study of premature infants who needed screening for ROP, we assessed the morphology of the optic disc. To date, only few studies have been conducted on the optic disc size in premature infants due to the difficulty of examination and the relatively new development of good quality fundus camera such as RetCam. Our study population included only premature babies who needed a screening for ROP, either according to the national guidelines, or because of the pediatrician's concern in regards to intrauterine growth retardation, prolonged sepsis or intensive oxygen support. Accordingly, this study did not allow comparison with healthy, full term subjects.

We found a mean C/D of 0.3 in our population of premature patients, regardless of gestational age, birth weight or presence of a retinopathy of prematurity. In their study, Hackl et al<sup>4</sup> found similar mean C/D values of 0.3. Fledelius et al<sup>6</sup>, with the ophthalmoscopy technique through a Richardson's lens, found that children with a birth weight of less than 2000g or between 1501 and 2000g had most frequently a C/D of 0.2 to 0.3, while full term infants C/D most frequently was 0.1 or less. Among all premature infants studied, Park et al<sup>1</sup>, found that the optic C/D ratio was less than 0.15 in 71.6% and 0.5 or more in 3.1% without correlation with birth weight and gestational age. Although our results suggest a higher C/D, we also found no significant difference in optic disc CD ratio between birth weight subgroups.

Conversely, Tong et al<sup>7</sup>, using a portable handheld spectral-domain optical coherence tomography (SD-OCT), found a C/D in preterm infants larger than in term infants (0.68 vs 0.53) ( $p < 0.001$ ) and Samarawickrama et al<sup>5</sup> reported that lower birth weight, as a marker of poorer intrauterine growth and intrauterine growth retardation, was significantly related to larger cup/disc ratio. Each kilogram increase was

associated with a 0.0136 reduction in mean cup/disc ratio ( $p=0.002$ ). These studies used different methods to assess the C/D. To the best of our knowledge, the comparability of those techniques has not been formally assessed.

In our patients, the disc had a bigger vertical than horizontal diameter and a mean ratio of 4/5. Similarly, Hackl et al<sup>4</sup> found a vertical oval form in 110 of 111 optic disc with a VD/HD = 1.28, corresponding to a Horizontal / Vertical ratio of 0.78. Moreover, he reported that the lower the birth weight, the more vertical oval was the optic disc and likewise for gestational age, as reported also by Kuruvilla et al<sup>8</sup>. Thus, our findings seem to confirm the previously described<sup>2,8,9,10</sup> oval shape of the optic disc in preterm and full term infants.

Previous studies suggested that low birth weight<sup>3,11</sup> and gestational age<sup>11</sup> could be associated with larger area of the optic disc. In opposition, Wickstrand et al<sup>3</sup>, Park et al<sup>1</sup> and Kandasamy and al<sup>2</sup>, showed that optic disc size or disc area was not influenced by birth weight or gestational age. Tong et al<sup>7</sup> found no significant difference of optic disc diameter between preterm and term infants, while Samarawickrama et al<sup>5</sup> reported that a lower birth weight was associated with smaller optic disc diameters ( $p=0.04$ ). We found a bigger vertical diameter of the disc in eyes with ROP. This didn't seem to be a group effect of birth weight or gestational age. Wickstrand et al<sup>3</sup> reported that optic disc variables did not differ significantly between children with and without severe ROP. Tong et al<sup>7</sup> found that ROP stage 3 or treatment had a shallower cup than those without ( $p=0.049$ ), even though cup depth did not differ significantly between preterm and term infants ( $p=0.544$ ). Park et al<sup>1</sup> did not find difference in any optic disc parameters between premature infants with and without plus disease or pre plus disease.

In our study, the proportion of eyes that respected the ISNT rule of the disc tended to increase in subgroups with a higher gestational age but were similar between subgroups according to birth weight and presence of a ROP. A considerably high proportion of children (93%) had a peripapillary atrophic ring. This feature, that can also be seen in optic nerve hypoplasia, made some authors to suggest that the double ring appearance may be a normal stage of disc development<sup>4,9</sup>. They hypothesized that after birth, the optic disc enlarges by another 50% to reach adult proportions, and that the growth of the disc lessens or abolishes the double-ring sign. Similarly, Fledelius et al<sup>10</sup> described an elliptic contour of the optic disc, with the long axis vertically, in the first two months of life of the premature babies. In their study<sup>10</sup>, many patients also showed a double contour of the disc margins which most of the time changed to a round or only slightly oval shape, and with a single border line in the cases followed for 1 to 2 years. The excavation and peripapillary crescent area did not seem to increase significantly with age<sup>11</sup>. Unfortunately, very few data exist about the optic disc morphology changes during the first months of life.

As premature patients are at high risk of comorbidities, many other factors could influence the optic disc development. Specifically, severe intraventricular hemorrhage<sup>12</sup>, periventricular white matter damage<sup>7,12</sup>, post-hemorrhagic hydrocephalus<sup>7</sup>, a long duration of assisted ventilation and a high number of blood transfusions<sup>11</sup> were suspected to influence the disc area, cupping or C/D ratio. The impact of the optic disc development on future visual function of ex-premature babies is unknown. In a study including children born prematurely examined with SD-OCT at the age of 4 to 10 years, Fieß et al found that children with a low birth weight or gestational age were more likely to have RNFL thinning, which was associated with low visual function<sup>13</sup>. Further investigations about the correlation between optic disc

morphology and comorbidity of prematurity such as intraventricular hemorrhages, respiratory failure or necrotizing enterocolitis could yield a better understanding of how prematurity affects the development of the optic nerve.

In conclusion, our study suggests that the cup-to-disc appearance in premature children has no correlation with birth weight, gestational age and presence of retinopathy of prematurity. Further research is needed to determine how the disc changes during the first months of life, the difference between premature and full term infants, and how it affects the visual development in inter-relation with other complications of severe and extreme prematurity.

## Acknowledgments

The authors wish to thank Professor Solange Milazzo for her support throughout this study.

## References

1. Park JW, Park SW, Heo H. RetCam image analysis of the optic disc in premature infants. *Eye*. 2013; 27(10): 1137.
2. Kandasamy Y, Smith R, Wright IMR, et al. Optic disc measurements in full term infants. *British Journal of Ophthalmology*. 2012; 96(5): 662-664.
3. Wikstrand MH, Hård AL, Niklasson A, et al. Birth weight deviation and early postnatal growth are related to optic nerve morphology at school age in children born preterm. *Pediatric research*. 2010; 67(3): 325.
4. Hackl S, Zeman F, Helbig H, et al. Optic disc morphology in premature infants. *British Journal of Ophthalmology*. 2013; 97(3): 314-317.
5. Samarawickrama C, Huynh SC, Liew G, et al. Birth weight and optic nerve head parameters. *Ophthalmology*. 2009; 116(6): 1112-1118.
6. Fledelius H. OPTIC DISC CUPPING AND PREMATURE Large Cups as a Possible Low Birth Weight Sequel. *Acta ophthalmologica*. 1978; 56(4): 563-573.
7. Tong AY, El-Dairi M, Maldonado RS, et al. Evaluation of optic nerve development in preterm and term infants using handheld spectral-domain optical coherence tomography. *Ophthalmology*. 2014; 121(9): 1818-1826.
8. Kuruvilla SE, Simkin S, Welch S, Dai S. Comparison of Optic Disk Features in Preterm and Term Infants. *J AAPOS*. 2018;22(5):376-380.e2. doi: 10.1016/j.jaapos.2018.04.008.
9. De Silva DJ, Cocker KD, Lau G, et al. Optic disk size and optic disk-to-fovea distance in preterm and full-term infants. *Investigative ophthalmology & visual science*. 2006; 47(11): 4683-4686.
10. Fledelius HC. Ocular features other than retinopathy of prematurity in the pre-term infant. *Acta ophthalmologica*. 1990; 68(2): 214-217.



- 11.** Hellström A, Hård AL, Chen Y, et al. Ocular fundus morphology in preterm children. Influence of gestational age, birth size, perinatal morbidity, and postnatal growth. *Investigative ophthalmology & visual science*. 1997; 38(6): 1184-1192.
- 12.** McLoone E, O'keefe M, Donoghue, V, et al. RetCam image analysis of optic disc morphology in premature infants and its relation to ischaemic brain injury. *British Journal of Ophthalmology*. 2006; 90(4): 465-471.
- 13.** Fieß A, Christian L, Janz J, et al. Functional analysis and associated factors of the peripapillary retinal nerve fibre layer in former preterm and full-term infants. *British Journal of Ophthalmology* 2017 Oct;101(10):1405-1411.

Table 1: Horizontal and vertical cup to disc ratio (C/D) in subgroups of patients regarding gestational age and birth weight.

Figure 1 : C/D ratio. Open circles represent individual data and full circles represent Mean  $\pm$  SD for each gestational age category (WG: weeks of gestation)

## Disclosure of interest

The authors declare that they have no conflicts of interest concerning this article.

## Déclaration des conflits d'intérêt

Les auteurs déclarent n'avoir aucun lien en relation avec cet article

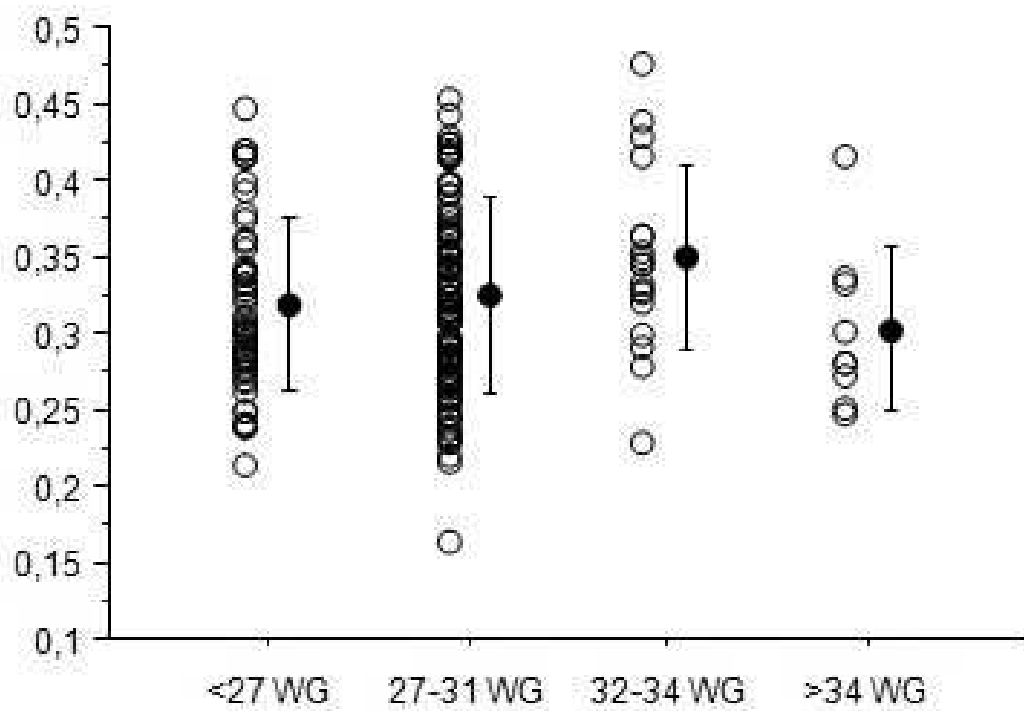


Figure 1 : C/D ratio. Open circles represent individual data and full circles represent Mean  $\pm$  SD for each gestational age category (WG: weeks of gestation)

|                         |                | Horizontal C/D        | Vertical C/D    |
|-------------------------|----------------|-----------------------|-----------------|
|                         |                | Mean $\pm$ SD         | Mean $\pm$ SD   |
|                         |                | [range]               | [range]         |
| <b>Gestational age</b>  | < 27 weeks     | 0.31 $\pm$ 0.05 [0.21 | 0.30 $\pm$ 0.07 |
|                         | (n=49 eyes)    | - 0.45]               | [0.18 - 0.50]   |
|                         | 27 to 31 weeks | 0.32 $\pm$ 0.06       | 0.32 $\pm$ 0.07 |
|                         | (n=104)        | [0.16 - 0.58]         | [0.19 - 0.53]   |
|                         | 32 to 34 weeks | 0.35 $\pm$ 0.06       | 0.36 $\pm$ 0.06 |
|                         | (n=20)         | [0.23 - 0.48]         | [0.28 - 0.52]   |
|                         | >34 weeks      | 0.27 $\pm$ 0.02       | 0.27 $\pm$ 0.06 |
|                         | (n=6)          | [0.25 - 0.30]         | [0.20 - 0.38]   |
| <b>Birth weight (g)</b> | <800           | 0.31 $\pm$ 0.05 [0.24 | 0.31 $\pm$ 0.08 |
|                         | (n=33 eyes)    | - 0.45]               | [0.20 - 0.50]   |
|                         | 800 - 1099     | 0.37 $\pm$ 0.07 [0.16 | 0.33 $\pm$ 0.07 |
|                         | (n=81)         | - 0.58]               | [0.18 - 0.53]   |
|                         | 1200 - 1499    | 0.33 $\pm$ 0.06 [0.23 | 0.30 $\pm$ 0.06 |
|                         | (n=38)         | - 0.48]               | [0.20 - 0.48]   |
|                         | 1500 - 1999    | 0.32 $\pm$ 0.05 [0.22 | 0.34 $\pm$ 0.06 |
|                         | (n=20)         | - 0.38]               | [0.22 - 0.52]   |
|                         | $\geq$ 2000    | 0.27 $\pm$ 0.02       | 0.27 $\pm$ 0.06 |
|                         | (n=6)          | [0.25 - 0.30]         | [0.20 - 0.38]   |

Table 1: Horizontal and vertical cup to disc ratio (C/D) in subgroups of patients regarding gestational age and birth weight.