



HAL
open science

Surgical treatment outcomes of solitary fibrous tumors in the head and neck: A retrospective study

Marti-Flich Lucas, Matthias Schlund, S. Dapke, Constantinus Politis,
Sébastien Aubert, Thomas Wojcik, Florent Barry, François Mouawad, Claire
Majoufre, Bernard Leyman, et al.

► **To cite this version:**

Marti-Flich Lucas, Matthias Schlund, S. Dapke, Constantinus Politis, Sébastien Aubert, et al..
Surgical treatment outcomes of solitary fibrous tumors in the head and neck: A retrospective
study. *Journal of Cranio-Maxillofacial Surgery*, 2023, *Journal of Cranio-Maxillofacial Surgery*,
10.1016/j.jcms.2023.05.013 . hal-04106706

HAL Id: hal-04106706

<https://u-picardie.hal.science/hal-04106706v1>

Submitted on 29 Apr 2024

HAL is a multi-disciplinary open access archive for the deposit and dissemination of scientific research documents, whether they are published or not. The documents may come from teaching and research institutions in France or abroad, or from public or private research centers.

L'archive ouverte pluridisciplinaire **HAL**, est destinée au dépôt et à la diffusion de documents scientifiques de niveau recherche, publiés ou non, émanant des établissements d'enseignement et de recherche français ou étrangers, des laboratoires publics ou privés.

Surgical treatment outcomes of solitary fibrous tumors in the head and neck: A retrospective study

Lucas Marti-Flich¹, Matthias Schlund², S.Dapke³, Constantinus Politis⁴, Sébastien Aubert⁵, Thomas Wojcik⁶, Florent Barry¹, François Mouawad⁷, Claire Majoufre⁸, Bernard Leyman⁹, Sylvie Testelin³, Romain Nicot⁶

¹ Univ. Angers, CHU Angers, Department of Oral and Maxillofacial Surgery, 49000 Angers

² Univ. Bordeaux, CHU Bordeaux, Inserm, Department of Oral and Maxillofacial Surgery, U 1026 – Bioengineering of Tissues, F-33000 Bordeaux, France

³ Maxillo-Facial Surgery Department, Amiens-Picardie University Hospital, 80000 Amiens, France

⁴ Department OMFS, Department Imaging and Pathology, Faculty of Medicine, Leuven University Hospitals, Leuven, Belgium

⁵ Department of Pathology, Lille University Hospital, Lille, France; Inserm, CNRS, UMR9020, U1277 - CANTHER - Cancer Heterogeneity, Plasticity and Resistance to Therapies, University of Lille, Lille University Hospital, F-59000 Lille, France

⁶ Univ. Lille, CHU Lille, Inserm, Department of Oral and Maxillofacial Surgery, U 1008 - Controlled Drug Delivery Systems and Biomaterials, F-59000 Lille

⁷ ENT and Head and Neck Department, Lille 59037 Cedex, France; University Lille, CNRS, Inserm, CHU Lille, UMR9020-U1277 - CANTHER - Cancer Heterogeneity Plasticity and Resistance to Therapies, Lille F-59000, France

⁸ Univ. Bordeaux, CHU Bordeaux, Department of Oral and Maxillofacial Surgery, F-33000 Bordeaux, France

⁹ Department of Oral and Maxillofacial Surgery, University Hospitals Leuven, Herestraat 49, Leuven, Belgium

Corresponding Author:

Dr. Marti-Flich Lucas
4 rue Larrey 49933 Angers Cedex 9
0241353276
Lucas.Martiflich@chu-angers.fr

Abstract:

The aim of this study was to better characterize head and neck solitary fibrous tumors (SFTs) and evaluate surgical treatment. This retrospective study included all patients who presented with head and neck SFTs between 2003 and 2021 in four university hospitals. Clinical, radiological, histological information and data of the treatments performed were collected. The risk of locoregional and distant metastases was calculated and for orbital SFTs a specific classification was used. Overall, 34 patients were included. The majority of the SFTs were found in oral cavity (n = 10), followed by the neck region (n = 8). The mean time to recurrence was 67.4 months. All patients underwent primary surgical resection. Recurrence was observed in five patients with a low risk of locoregional recurrence and distant metastasis.

The treatment of choice is complete resection, indeed, recurrence seems highly correlated with positive surgical margins. Safety margin should be increased when removing the lesion and long-term follow-up should be performed.

1. Introduction

Solitary fibrous tumors (SFT), including hemangiopericytoma (HPC) or HPC-like lesions, are rare spindle-cell neoplasms that can occur in any region of the body (Gengler, Guillou, 2006). These tumors are of mesenchymal origin and usually well defined. They were first described by Klemperer and Rabin in 1931 as pleural tumors (Klemperer, Coleman, 1992). The first case of a head and neck SFT was reported in 1991 (Witkin, Rosai, 1991). SFTs of the head and neck represent 25% of extra-thoracic SFTs, with only 587 cases of these tumors listed in the literature in a recent review (Stanisce et al., 2019). Clinically, SFTs usually present as slow-growing masses in middle-aged adults, without sex predilection; they may cause painful symptoms due to compression of adjacent structures (Stanisce et al., 2019). On imaging, these tumors display features of a heterogeneous hypervascular lesion associated with a well-circumscribed neoplastic process (Liu et al, 2014). The clinical behaviour of SFT is difficult to predict although most SFT pursue a benign clinical course; however, metastasis has been observed. These tumors have metastatic potential in 5 to 15% of the cases (Demicco et al., 2017). Biopsy with histological and immunohistochemical (CD34 and STAT6) examinations is necessary to confirm the diagnosis of SFTs (de Morais et al., 2020). Classically, SFTs are composed of variable pleomorphic spindle cells admixed with collagen and arranged haphazardly (“patternless”) or in short fascicles, while tumors within the previously separated HPC spectrum are composed of ovoid, monomorphic cells with thin-walled anastomosing vessels (Demicco et al.,2012). The primary treatment for SFTs is complete surgical excision, and long-term follow-up is necessary to monitor for possible local recurrence (Jiang et al., 2019). Knowledge about SFTs, particularly those in the head and neck, is limited because of the small number of cases reported in the literature. Head and neck SFTs may require complex surgical removal and could be associated with high morbidity, especially in the orbit where vision or the eyeball itself may be lost or in the oral cavity where complex surgical reconstruction using a free flap may be necessary. The aim of this study was to better characterize head and neck SFTs clinically, radiologically, and histologically and evaluate surgical treatment.

2. Material and Methods

Included patients and data collection

This retrospective study included all patients treated for head and neck SFTs between 2003 and 2021 in four different university hospitals.

The following data were collected:

- Clinical: age, sex, family history, smoking habits, tumor localization, clinical symptoms
- Radiological: radiological appearance, contrast injection enhancement, density and intensity level, tumor size, local extension to bone, vascular or nerve tissue. Only computed tomography (CT) and magnetic resonance imaging (MRI) data were considered.
- Treatment: treatment performed, surgical margins, reoperation in case of positive margins, adjunctive therapy (radiotherapy, chemotherapy, or embolization)

The risk of locoregional and distant metastases was calculated according to the classification established by Demicco et al. (Demicco et al., 2017) based on the following parameters: age, tumor size (cm), mitotic count (mitotic figures/10 high-power fields [hpfs]), and tumor necrosis. Due to the different localization of the tumor, the predictive model of local recurrence and distant metastasis described by Thompson et al. (Thompson et al., 2021) was also performed for orbital SFTs. The settings included age (cut-off: 45 years), tumor size (cut-off 3 cm), mitotic count (/10 hpfs cellularity, cellular and nuclear pleomorphism, and tumor necrosis.

- Outcome: recurrence, disease-free survival, last known disease, overall survival

All procedures performed in the study were in accordance with the ethical standards of the Declaration of Helsinki 2013. According to French and Belgian law, no institutional review board evaluation was required due to the retrospective nature of the study.

Histological review

The pathologic parameters collected included the original diagnostic term, tumor dimensions, overall histologic pattern, presence of atypia, vascular involvement, nervous invasion, bone invasion, necrosis, and hemorrhage. Mitotic count was performed in cellular areas. The overall histologic pattern was defined as “classic SFT” if the lesion showed a predominant pattern of low-to-moderate cellularity of spindle cells. If the predominant histologic pattern was densely cellular, proliferative lesions were defined as a “cellular SFTs.” Furthermore, statuses of the following immunohistochemical markers were determined: CD34, bcl2, CD99, smooth muscle actin, epithelial membrane antigen, S-100, and STAT-6.

3. Results

Overall, 34 patients (14 males and 20 females) were included: 20, 9, 3, 2 patients from the Lille, Amiens, Leuven and Bordeaux hospitals. The mean age at diagnosis was 52 years (range: 20 to 83 years). The majority of the SFTs were found in oral cavity (n = 10), followed by the neck region (n = 8), orbit (n = 7), sinonasal tract (n = 4), parotid gland (n = 2), submandibular gland (n = 1), scalp skin (n = 1), and temporal fossa (n = 1). The average clinical duration of tumor evolution was 23 months (minimum: 1 month; maximum: 129 months). The main patient complaint was swelling (n=28), followed by pain (n=14). Pain was more often present in cases of SFTs in the orbit (n=5), oral cavity (n=3), and nasal cavity and cervical region (n=2). More specifically, the patients who presented with SFTs localized in the nasal cavity all had a nasal obstruction (4/4). Patients with orbital SFTs frequently presented with exophthalmos (4/7) and diplopia (4/7). Three patients presented with decreased visual acuity; pain was also a major symptom (5/7).

CT was performed in every case, and it revealed a well-limited tissular lesion with contrast enhancement after iodine injection in 15 cases (Figure1).

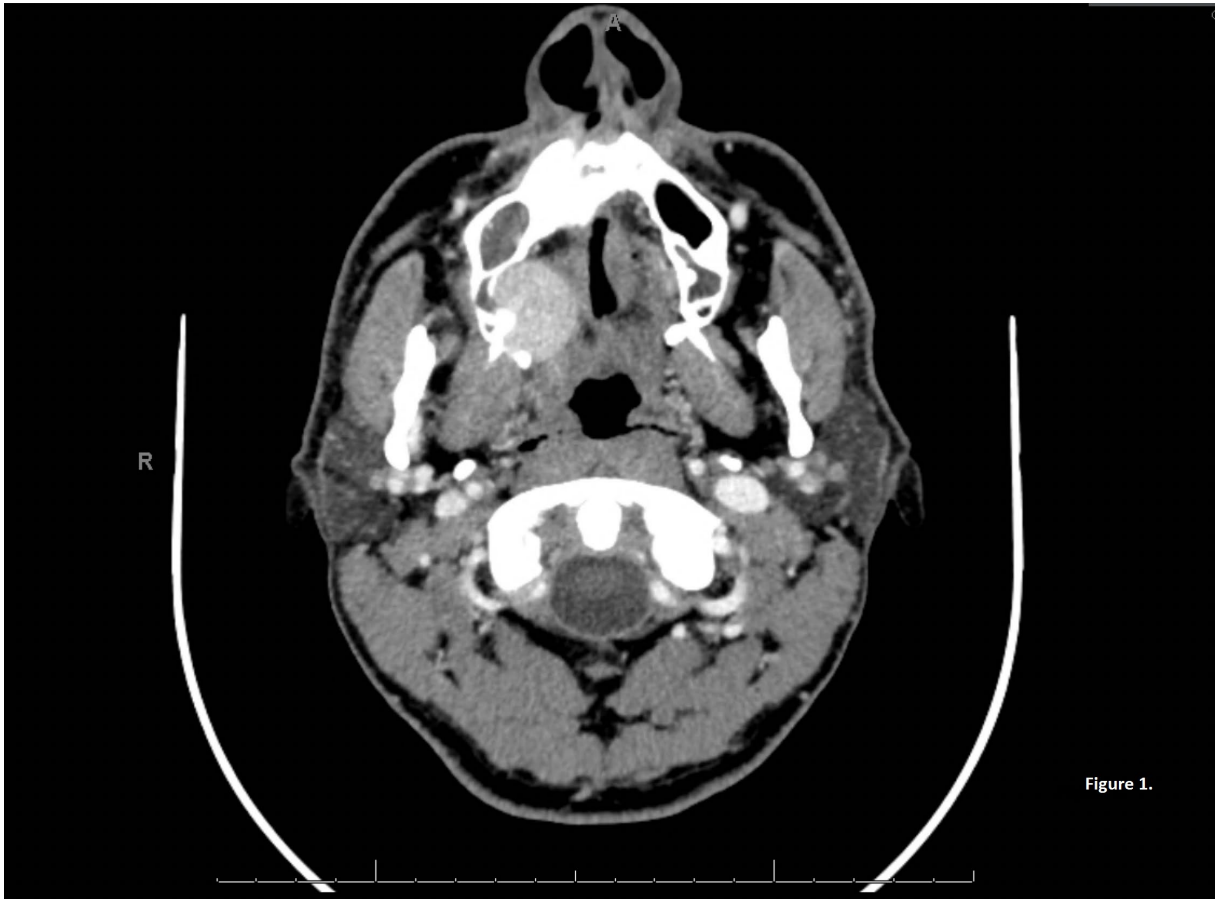

Figure 1. CT image, axial view, showing a well-limited tissular lesion with contrast enhancement after iodine injection corresponding to a sinonasal SFT.

Four patients presented with local extension to the bone, and one patient with cervical localization of an SFT presented with nerve extension. MRI was performed in 15 cases only. Tumors were isointense in nine cases and hypointense in five cases on T1-weighted images and were hyperintense in 11 cases versus hypointense in three cases on T2-weighted images. In every case, contrast enhancement after gadolinium injection was found. An example of the MRI aspect of SFT is shown in figure 2(A, B, C, D).

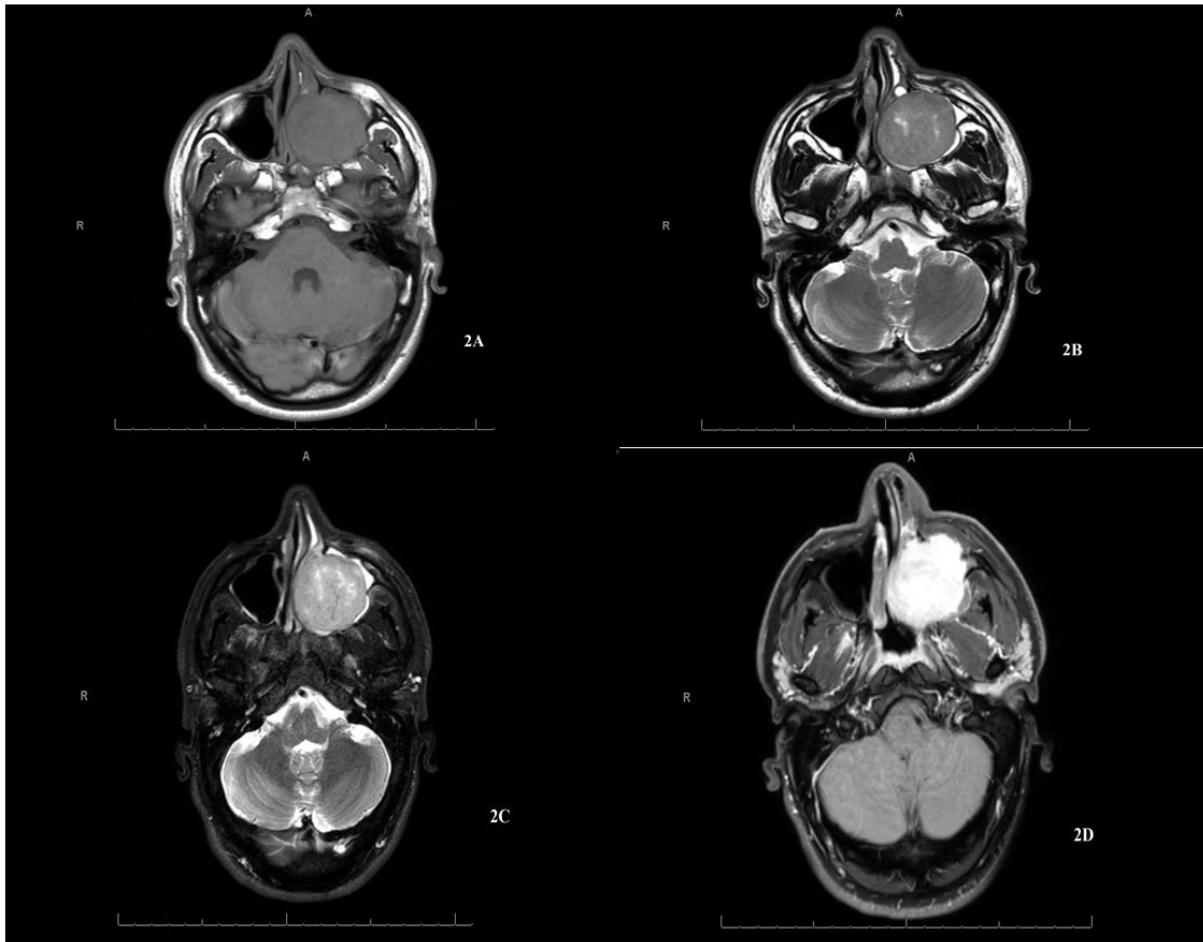


Figure 2. MR image, axial view, showing a sinonasal SFT in T1 sequence (**2A**) ; in T2 sequence (**2B**) ; short T1 inversion recovery (STIR) sequence (**2C**) ; T1 sequence after gadolinium injection (**2D**)

The size of the lesions ranged from 1.2 cm to 9 cm, with the average size being 4 cm. Among the different SFTs, the lesions that were strictly larger than 3.5 cm were more voluminous in the cervical region. The largest lesion was found in the submandibular gland and the smallest in the orbital region. Histologically, the cellular form of SFTs (n = 20) was more represented compared to the classical form (n = 14). Atypia, corresponding to increased nuclear pleomorphism and/or coarseness of chromatin, was present in 17 patients, while epithelioid cytomorphology was not reported. Tumor cell necrosis was found in two lesions, while mitotic counts ranged from 0 to 14 mitotic figures /10 hpfs with a median of 3. High hpfs localization was gathered to search a correlation between high hpfs and recurrence of SFT (according to Demicco et al., >4). There was no predilection of localization of high hpfs and recurrence; the results are shown in Table 1.

Table 1. Description of the population. Risk stratification is performed according to Demicco et al. Hpf stands for high power field, N/A stands for non-available

Patient	Gender	Age (years)	Location	Morphology	Atypia	Mitotic count (/10hpf)	Necrosis	Surgical margins	Recurrence Status	Follow-up (Months)	Risk stratification (Demicco <i>et al.</i>)
1	Male	47	Sinonasal	Classic	+	2	-	R0	Disease-free	30	Low
2	Female	34	Oral cavity	Classic	+	0	-	R0	Disease-free	24	Low
3	Female	20	Parotid	Classic	+	10	-	R0	Disease-free	36	Low
4	Female	83	Sinonasal	Cellular	+	1	-	R1	Disease-free	84	Low
5	Female	54	Oral cavity	Cellular	+	7	-	R1	Disease-free	72	Low
6	Male	38	Oral cavity	Cellular	-	2	+	R1	Disease-free	2	Low
7	Male	59	Sinonasal	Cellular	+	3	-	R1	Disease-free	18	Low
8	Male	62	Orbit 1	Cellular	+	1	-	R1	Disease-free	24	Low

9	Female	34	Sinonasal	Classic	+	2	-	R1	Disease-free	48	Low
10	Male	46	Oral cavity	Cellular	-	1	-	R1	Disease-free	1	Low
11	Female	60	Neck	Classic	+	2	-	R1	Disease-free	4	Low
12	Male	35	Orbit 2	Cellular	+	14	+	R1	Lost to follow-up	3	Intermediate
13	Female	73	Parotid	Cellular	+	3	-	R1	Recurrence	24	Low
14	Female	44	Oral cavity	Cellular	+	1	-	R1	N/A	N/A	Low
15	Female	60	Oral cavity	Classic	-	0	-	R0	Disease-free	7	Low
16	Female	29	Orbit 3	Cellular	-	1	-	R1	Recurrence	192	N/A
17	Male	37	Orbit 4	Cellular	-	4	-	R1	Recurrence	72	Low
18	Female	41	Orbit 5	Cellular	+	5	-	R2	Recurrence	60	N/A
19	Female	41	Orbit 6	Classic	-	1	-	R1	Disease-free	36	Low
20	Female	82	Neck	Cellular	+	7	+	R0	Disease-free	18	Intermediate
21	Female	68	Neck	Classic	-	-	-	R0	Disease-free	12	Low

22	Female	34	Orbit 7	Cellular	-	-	-	R1	Lost to follow-up	13	Low
23	Male	57	Neck	Cellular	+	-	-	R0	Lost to follow-up	6	N/A
24	Female	44	Scalp	Classic	-	1	-	R1	N/A	N/A	Low
25	Male	83	Neck	Cellular	+	-	-	R0	Disease-free	2	N/A
26	Male	38	Temporal fossa	Classic	-	-	-	R0	Lost to follow-up	3	N/A
27	Male	57	Submandibular gland	Classic	-	-	-	R0	Disease-free	1	N/A
28	Male	73	Neck	Classic	-	1	-	R0	N/A	N/A	Low
29	Male	43	Neck	Cellular	+	1	-	R0	Disease-free	12	Low
30	Female	44	Neck	Classic	-	0	-	R0	N/A	N/A	Low
31	Female	51	Oral cavity	Classic	-	0	-	R0	Disease-free	1	Low
32	Female	22	Oral cavity	Cellular	-	-	-	R0	Disease-free	1	Low
33	Male	52	Oral cavity	Cellular	-	-	-	R0	Disease-free	76	Low

34	Female	36	Oral Cavity	Cellular	-	-	-	R0	Disease-free	24	Low
----	--------	----	-------------	----------	---	---	---	----	--------------	----	-----

The results of immunohistochemical staining are summarized in Table 2.

Case	CD34	STAT6	Bcl2	CD99	S-100	EMA	SMA
1	+	+	N/A	+	+	N/A	N/A
2	+	N/A	+	+	-	N/A	-
3	+	N/A	N/A	N/A	-	N/A	-
4	+	N/A	+	N/A	-	-	-
5	+	N/A	-	N/A	N/A	-	N/A
6	+	N/A	N/A	+	-	-	N/A
7	+	+	+	+	+	-	N/A
8	+	N/A	N/A	-	-	-	-
9	+	+	+	N/A	-	-	+
10	-	+	N/A	N/A	-	-	-
11	+	+	N/A	N/A	N/A	N/A	N/A
12	N/A	+	N/A	+	-	N/A	-
13	+	-	+	+	-	-	-
14	+	+	N/A	N/A	-	-	-
15	+	+	N/A	N/A	-	N/A	N/A
16	+	N/A	+	+	N/A	N/A	N/A
17	+	N/A	+	+	NA	NA	-
18	-	N/A	+	+	N/A	N/A	N/A
19	+	N/A	+	+	N/A	N/A	N/A
20	+	+	N/A	+	-	-	-
21	+	+	N/A	N/A	-	N/A	-
22	+	N/A	N/A	N/A	+	N/A	N/A
23	+	N/A	N/A	N/A	-	-	-
24	+	N/A	N/A	N/A	N/A	N/A	N/A
25	+	N/A	N/A	N/A	-	-	-

26	+	N/A	N/A	N/A	-	N/A	N/A
27	+	N/A	N/A	N/A	-	N/A	-
28	+	+	N/A	N/A	-	-	N/A
29	+	+	N/A	N/A	N/A	N/A	N/A
30	+	+	N/A	N/A	-	N/A	-
31	+	+	N/A	N/A	N/A	N/A	N/A
32	N/A	+	N/A	N/A	N/A	N/A	+
33	+	N/A	+	N/A	-	-	+
34	N/A	+	N/A	N/A	N/A	N/A	N/A

Table 2. Description of the immunohistochemical profile of each SFT. N/A stands for non-available

STAT6 staining was performed in only 16 cases, with 100% positivity.

All patients underwent primary surgical resection with safety margins. Seventeen patients showed microscopically positive margins after surgery. Therefore, nine patients underwent revision surgery. For cases involving the orbital, only surgical excision was performed. None of the cases involved exenteration. Three patients underwent adjuvant radiotherapy, of which two had positive margins and one underwent an R0 surgical excision. None of the patients underwent chemotherapy or embolization before or after the surgical treatment.

Follow-up data for disease recurrence were available for 30 patients. Follow-up assessments for these patients had not been completed in their records. Patient follow-up periods ranged from 1 month to 192 months (mean: 24 months). Two patients had a 1-month follow-up period because their inclusion that was performed at the end of 2021. Four cases showed local recurrence, although none of the patients showed distant metastasis. The median time to recurrence was 4 years. Most recurrences were observed in the orbital lesions (3/4), of which two cases involved R1 margins and one involved an R2 margin. One case showed recurrence in the parotid gland. All recurrences were treated by a second surgical excision with safety margins. The mean time to recurrence was 67.4 months.

The risk of locoregional and distant metastases for patients who showed recurrence in the follow-up period was calculated, and four patients presented with low risk according to the classification system proposed by Demicco et al. (Demicco et al., 2017) Risk stratification was performed for all patients in the study and could not obtain correct risk results for six patients due to a lack of data. Twenty-six patients presented with a low risk and two with intermediate risk. Interestingly, the two patients who presented with intermediate risk did not show recurrence whereas four patients were classified as showing low risk had shown a recurrence.

For the orbital cases (n = 7), the risk stratification established by Thompson et al. (Thompson et al., 2021) was calculated. The results are summarized in Table 3.

Table 3. Description of the orbital SFTs. Risk assessment is performed according to Thompson *et al.*

Hpf stands for high power field, N/A stands for non-available

Patient	Age – (years)	Tumor size (cm)	Mitotic count (/10 HPF)	Cellularity	Cellular/nuclear pleomorphism	Tumor necrosis	Risk for recurrence
Orbit 1	62	4.5	1	low	high	Absent	intermediate
Orbit 2	35	6	14	high	high	Present	High
Orbit 3	29	N/A	1	high	low	Absent	-
Orbit 4	37	1.2	4	high	low	Absent	low
Orbit 5	41	N/A	5	high	high	Absent	-
Orbit 6	41	2.5	1	low	low	Absent	Very low
Orbit 7	34	1.2	N/A	high	low	N/A	-

Due to missing data on lesion size and mitotic count, the risk could not calculate for three cases. Two patients showed an intermediate and high risk of recurrence. However, none of them showed any recurrence in follow-up assessments. Two other patients showed a low risk of recurrence and one of them showed local recurrence. Among the 17 disease-free cases, the median follow-up time was 25 months (range: 2 to 84). None of the patients died during the follow-up.

4. Discussion

SFTs, which are already rare tumors, are seldom reported in the head and neck area, with 587 SFTs described in the literature (Stanisce et al, 2019). Large cohorts of patients with NFTs are scarce. This cohort had a mean age of 58 years, corroborating the previous findings (Kallen et al., 2020; Smith et al. 2017). However, the cohort showed a female predominance, with an F:M ratio of 1.5, while no gender predominance is usually described in these patients. Smith et al. also found a slight female predominance (F:M ratio of 1.2), but that might be attributable to a sampling bias. . The main location in this study was in oral cavity (n = 10), followed by the neck region (n = 8), orbit (n = 7), sinonasal tract (n = 4). Head and neck SFT location is a subject of debate, and the categorization suffers from the absence of a clear definition for head and neck tumors. Indeed, Smith et al. showed a predominance of sinonasal (30%) and orbital (30%) tumors, while Stanisce et al. showed a predominance of oral cavity tumors (31%) over sinonasal (16%) and neck (12%) tumors. However, Stanisce et al. excluded orbital lesions, which have been previously described as rare in the study by Cox et al. (6%). The selection bias certainly depends on the scope of head and neck pathologies treated by maxillofacial surgeons, otorhinolaryngologists, or ophthalmologists. Studies performed by pathologists are limited by the same bias depending on the surgeons they work with. Furthermore, a publication bias may be linked with the rarity of SFT with a high number of case reports or small series (Smith et al., 2017). Thus, it may be concluded that facial cavities, such as the orbit, sinonasal, and oral cavities, are locations of choice for SFTs.

The imaging findings of SFT in the head and neck region are non-specific. Despite a large series of patients, CT or MR imaging cannot by themselves be more than evocative of SFT diagnosis. Indeed, imaging findings are quite heterogeneous (Liu et al., 2014). CT remains the mainstay for the evaluation of SFT. MR imaging is useful for the delineation of tumor, and the evaluation of local invasion into adjacent organs such as nerve (Keraliya et al., 2016). Its interest is therefore major in areas such as the orbit or the oral cavity.

There were no specific markers for SFT in this study, with the markers used in each center showing a high degree of heterogeneity. CD34 was widely used, and strong positivity of the CD34 marker was

found in most cases. Indeed, more than 90% of SFTs are known to be immunoreactive to CD34 (Yoshida et al. 2014). Cluster of differentiation group 34 (CD34) is a single-pass type I transmembrane glycoprotein whose main functions are as a cell-to-cell adhesion factor. As an adhesion factor, CD34 is expressed during the lymphohematopoietic stem/progenitor stage of development and may eventually mediate stem cell attachment to bone marrow, extra-cellular matrix, or stromal cells (Sidney et al., 2014). Two patients were CD34-negative, and both showed local recurrence or a high risk of metastasis. Surgical margins were positive for these patients. CD34-negative SFTs appear more frequently in the head and neck region. However, they show more aggressive behaviors. The histological findings of CD34-negative SFTs, including hypercellularity, round cell/epithelioid/anaplastic cytology, and nuclear pleomorphism, in addition to mitotic activity and tumor necrosis (Dermawan et al., 2021), were not found in this cohort of patients.

The discovery of the intrachromosomal rearrangement on chromosome 12q13 has led to the demonstration of nuclear expression of STAT6 protein in SFTs, which is currently considered as the most specific marker for the diagnosis of the neoplasm (Doyle et al., 2014). This finding was corroborated in this study for cases that benefited from immunostaining for the NAB2-STAT6 genetic modification (Iorio et al., 2019). However, while NAB2-STAT6 specificity is high, it is still not comprehensive (Wakely et al., 2021). Initial studies of NAB2-STAT6 fusion types had suggested that the specific exons present in the chimeric fusion gene might influence SFT behavior (Demicco et al., 2012; Barthelmess et al., 2014). Recent studies have associated the loss of STAT6 immunoreactivity with dedifferentiation in SFT when NAB2-STAT6 fusion was detected (Schneider et al., 2017; Chmielecki et al., 2013; Kakkar et al., 2020; Robinson et al., 2013). Several markers were studied during the data gathering. However, each physician and each center had a different panel of markers that resulted in heterogeneity of the results and precluded the determination of other markers to identify SFT.

The gold standard treatment for SFT is surgical resection (de Morais et al., 2020; Demicco et al., 2012; Sun et al., 2021). The use of radiotherapy as a primary or adjuvant therapy has not been shown to improve survival (Bishop et al., 2018; Xue et al., 2014) but could be useful in some particular cases. SFT follow-up is important since these lesions, which are mostly considered benign, may recur or

metastasize. Several scales have been published to assess the risk of recurrence based on various parameters. According to the criteria reported by Demicco et al., predictive factors of metastasis, such as age, tumor size, necrosis (<10% or >10%), and mitotic count (0, 1–3, or $\geq 4/10$ hpfs) were found in this series (Demicco et al., 2017). We used the risk stratification of SFTs for the development of metastasis described in the WHO classification of 2020 (based on the *Demicco* stratification risk) (Kallen et al., 2020), and all patients showing local recurrence in this study were at low risk of metastasis. We used *Demicco* risk stratification to evaluate the local recurrence potential of the SFT. This classification may not be appropriate in orbital SFT where excision is difficult and increases the risk of invasion or low margins. Solitary fibrous tumors of the orbit do not have the same metastatic potential as SFTs in other anatomical regions according to Thompson et al. (Thompson et al. 2021) In fact, orbital SFT were the localization where surgical margins had the highest risk of being invaded during surgery.

One patient with a low risk of metastasis according to Demicco et al. (Demicco et al., 2017) and Thompson et al. (Thompson et al., 2021) showed local recurrence. Most often, patients who underwent incomplete excision required revision surgery. However, the recurrence risk of SFT was higher if the initial tumor resection showed an invaded margin. We propose that surgical factors could be involved in stratifying the risk of local recurrence because the histological markers of aggressive clinical behavior chosen by Stanisce, such as nuclear atypia, mitotic count, and necrosis, were not systematically associated with recurrence in this cohort. In fact, in their study, they expressed reservations about the correlation between these histological features and the risk of metastasis (Stanisce et al., 2019). The data also validate these reservations since none of the patients included with these characteristics showed aggressive tumor potential. On the basis of the observations in this study, we suggest that invasion of the resection margin at the time of tumor resection should be considered as a criterion for the risk of recurrence. Although several risk stratification proposals for SFTs based on clinical and pathology findings are available, not all of them are suitable for these tumors since each system employs different criteria, with mitotic index being the only common criterion.

The primary limitation of this study was its retrospective design, which increased the risk of data loss. Indeed, once the tumor has been removed and the immediate postoperative follow-up was over, the patient was asymptomatic and did not require adjuvant treatment. Thus, follow-up assessments may be interrupted due to a lack of patient compliance. However, monitoring disease progression in patients is important, and long-term follow-up assessments are necessary to understand the disease behavior (Sun et al., 2021). Moreover, as mentioned previously, data for margin status and size were not always available.

5. Conclusion

Solitary fibrous tumors are benign lesions with an aspecific clinical and imaging presentation. Immunostaining is necessary for diagnosis. Immunohistochemical and molecular analysis of sampled tissues may facilitate relatively easy identification of most dedifferentiated SFTs. Complete surgical removal is the treatment of choice since recurrence seems highly correlated with positive margins. Safety margin should be increased when removing the lesion and long-term follow-up is advised as recurrence may occur several years following initial care.

Conflicts of Interest

The authors declare that they have no conflict of interest.

References

- Barthelmeß S, Geddert H, Boltze C, Moskalev EA, Bieg M, Sirbu H, et al. Solitary Fibrous Tumors/Hemangiopericytomas with Different Variants of the NAB2-STAT6 Gene Fusion Are Characterized by Specific Histomorphology and Distinct Clinicopathological Features. *Am J Pathol*. 2014;184(4):1209-18.
- Bishop AJ, Zagars GK, Demicco EG, Wang W-L, Feig BW, Guadagnolo BA. Soft Tissue Solitary Fibrous Tumor: Combined Surgery and Radiation Therapy Results in Excellent Local Control. *Am J Clin Oncol*. 2018;41(1):81-5.
- Chmielecki J, Crago AM, Rosenberg M, O'Connor R, Walker SR, Ambrogio L, et al. Whole-exome sequencing identifies a recurrent NAB2-STAT6 fusion in solitary fibrous tumors. *Nat Genet*. 2013;45(2):131-2.
- de Moraes EF, Martins HDD, Rodrigues KS, de França GM, da Silveira ÉJD, Freitas R de A. Clinicopathologic Analysis of Oral and Maxillofacial Solitary Fibrous Tumor. *Am J Clin Pathol* 2020.
- Demicco EG, Wagner MJ, Maki RG, Gupta V, Iofin I, Lazar AJ, et al. Risk assessment in solitary fibrous tumors: validation and refinement of a risk stratification model. *Mod Pathol*. 2017;30(10):1433-42.
- Demicco EG, Park MS, Araujo DM, Fox PS, Bassett RL, Pollock RE, et al. Solitary fibrous tumor: a clinicopathological study of 110 cases and proposed risk assessment model. *Mod Pathol*. 2012;25(9):1298-306.
- Dermawan JK, Rubin BP, Kilpatrick SE, Gjorgova G, Gjeorgjievski S, Fritchie KJ, Goldblum JR, et al. CD34-negative Solitary Fibrous Tumor: A Clinicopathologic Study of 25 Cases and Comparison With Their CD34-positive Counterparts. *Am J Surg Pathol*. 2021;45(12):1616-25.
- Doyle LA, Vivero M, Fletcher CD, Mertens F, Hornick JL. Nuclear expression of STAT6 distinguishes solitary fibrous tumor from histologic mimics. *Mod Pathol*. 2014;27(3):390-5.
- Gengler C, Guillou L. Solitary fibrous tumour and haemangiopericytoma: evolution of a concept. *Histopathology* 2006;48(1):63-74.
- Iorio B, Ronchi A, Montella M, Cozzolino I, De Luca R, Rusciano M, et al. Malignant extrapleural solitary fibrous tumor arising in the sublingual gland: A case report and review of literature. *Oral Oncol*. 2019;90:141-4.
- Jiang L, Hu C, Chen L, Chen L. Diagnosis of solitary fibrous tumor in the submandibular gland: Case report and literature review. *J Clin Ultrasound*. 2019;47(8):486-9.
- Kakkar A, Sakthivel P, Rajeshwari M, Kairo A, Sharma MC. Recurrent Sinonasal CD34-Negative Malignant Solitary Fibrous Tumor Diagnosed on STAT6 Immunohistochemistry and NAB2-STAT6 Fusion. *Head Neck Pathol*. 2020;14(1):250-6.

Kallen ME, Hornick JL. The 2020 WHO Classification: What's New in Soft Tissue Tumor Pathology? *Am J Surg Pathol*. 2020;45(1):e1-23.

Keraliya AR, Tirumani SH, Shinagare AB, Zaheer A, Ramaiya NH. Solitary Fibrous Tumors. *Radiol Clin North Am*. 2016;54(3):565-79.

Klemperer P, Coleman BR. Primary neoplasms of the pleura. A report of five cases. *Am J Ind Med* 1992;22(1):1-31.

Liu Y, Li K, Shi H, Tao X. Solitary fibrous tumours in the extracranial head and neck region: correlation of CT and MR features with pathologic findings. *Radiol Med (Torino)*. 2014;119(12):910-9.

Robinson DR, Wu Y-M, Kalyana-Sundaram S, Cao X, Lonigro RJ, Sung Y-S, et al. Identification of recurrent NAB2-STAT6 gene fusions in solitary fibrous tumor by integrative sequencing. *Nat Genet*. 2013;45(2):180-5.

Schneider N, Hallin M, Thway K. STAT6 Loss in Dedifferentiated Solitary Fibrous Tumor. *Int J Surg Pathol*. 2017;25(1):58-60.

Sidney LE, Branch MJ, Dunphy SE, Dua HS, Hopkinson A. Concise Review: Evidence for CD34 as a Common Marker for Diverse Progenitors. *Stem Cells* . 2014;32(6):1380-9.

Smith SC, Gooding WE, Elkins M, Patel RM, Harms PW, McDaniel AS, et al. Solitary Fibrous Tumors of the Head and Neck. *Am J Surg Pathol*. 2017;41(12):15.

Stanisce L, Ahmad N, Levin K, Deckard N, Enriquez M, Brody J, et al. Solitary Fibrous Tumors in the Head and Neck: Comprehensive Review and Analysis. *Head Neck Pathol* <https://doi.org/10.1007/s12105-019-01058-6>

Sun Q, Choi Y-D, Kim Y. Cellular solitary fibrous tumor in the mental area: a case report and literature review. *J Int Med Res*. 2021;49(3):030006052110005.

Thompson LDR, Liou SS, Feldman KA. Orbit Solitary Fibrous Tumor: A Proposed Risk Prediction Model Based on a Case Series and Comprehensive Literature Review. *Head Neck Pathol*. 2021;15(1):138-52.

Wakely PE, Rekhi B. Cytopathology of solitary fibrous tumor: a series of 34 cases. *J Am Soc Cytopathol*. 2021;10(4):382-90.

Witkin GB, Rosai J: Solitary fibrous tumor of the upper respiratory tract. A report of six cases. *Am J Surg Pathol* 15:842, 1991

Xue Y, Chai G, Xiao F, Wang N, Mu Y, Wang Y, et al. Post-operative Radiotherapy for the Treatment of Malignant Solitary Fibrous Tumor of the Nasal and Paranasal Area. *Jpn J Clin Oncol*. 2014;44(10):926-31.

Yoshida A, Tsuta K, Ohno M, Yoshida M, Narita Y, Kawai A, et al. STAT6 Immunohistochemistry Is Helpful in the Diagnosis of Solitary Fibrous Tumors. *Am J Surg Pathol*. 2014;38(4):552-9.

Figure & Table Legends

Figure 1. CT image, axial view, showing a well-limited tissular lesion with contrast enhancement after iodine injection corresponding to a sinonasal SFT.

Figure 2. MR image, axial view, showing a sinonasal SFT in T1 sequence (**2A**) ; in T2 sequence (**2B**) ; short T1 inversion recovery (STIR) sequence (**2C**) ; T1 sequence after gadolinium injection (**2D**)

Table 1. Description of the population. Risk stratification is performed according to Demicco et al. Hpf stands for high power field, N/A stands for non-available

Table 2. Description of the immunohistochemical profile of each SFT. N/A stands for non-available

Table 3. Description of the orbital SFTs. Risk assessment is performed according to Thompson *et al.* Hpf stands for high power field, N/A stands for non-available