



**HAL**  
open science

## Case series of intestinal microsporidiosis in non-HIV patients caused by *Encephalitozoon hellem*

Céline Nourrisson, Samia Hamane, Julie Bonhomme, Marie-Fleur Durieux, Jean-Baptiste Foulquier, Sophie Lesthelle, Maxime Moniot, Marie-Elisabeth Bougnoux, Philippe Poirier

► **To cite this version:**

Céline Nourrisson, Samia Hamane, Julie Bonhomme, Marie-Fleur Durieux, Jean-Baptiste Foulquier, et al.. Case series of intestinal microsporidiosis in non-HIV patients caused by *Encephalitozoon hellem*. *Emerging microbes & infections*, 2023, 12 (2), pp.2258997. 10.1080/22221751.2023.2258997. hal-04239830

**HAL Id: hal-04239830**

<https://u-picardie.hal.science/hal-04239830v1>

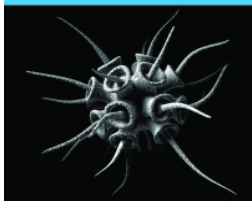Submitted on 30 May 2024

**HAL** is a multi-disciplinary open access archive for the deposit and dissemination of scientific research documents, whether they are published or not. The documents may come from teaching and research institutions in France or abroad, or from public or private research centers.

L'archive ouverte pluridisciplinaire **HAL**, est destinée au dépôt et à la diffusion de documents scientifiques de niveau recherche, publiés ou non, émanant des établissements d'enseignement et de recherche français ou étrangers, des laboratoires publics ou privés.



Distributed under a Creative Commons Attribution - NonCommercial 4.0 International License



## Case series of intestinal microsporidiosis in non-HIV patients caused by *Encephalitozoon hellem*

Céline Nourrisson, Samia Hamane, Julie Bonhomme, Marie-Fleur Durieux, Jean-Baptiste Foulquier, Sophie Lesthelle, Maxime Moniot, Marie-Elisabeth Bougnoux & Philippe Poirier

To cite this article: Céline Nourrisson, Samia Hamane, Julie Bonhomme, Marie-Fleur Durieux, Jean-Baptiste Foulquier, Sophie Lesthelle, Maxime Moniot, Marie-Elisabeth Bougnoux & Philippe Poirier (2023) Case series of intestinal microsporidiosis in non-HIV patients caused by *Encephalitozoon hellem*, Emerging Microbes & Infections, 12:2, 2258997, DOI: [10.1080/22221751.2023.2258997](https://doi.org/10.1080/22221751.2023.2258997)

To link to this article: <https://doi.org/10.1080/22221751.2023.2258997>



© 2023 The Author(s). Published by Informa UK Limited, trading as Taylor & Francis Group, on behalf of Shanghai Shangyixun Cultural Communication Co., Ltd



Published online: 14 Sep 2023.



Submit your article to this journal [↗](#)



Article views: 878



View related articles [↗](#)



View Crossmark data [↗](#)



Citing articles: 1 View citing articles [↗](#)

## Case series of intestinal microsporidiosis in non-HIV patients caused by *Encephalitozoon hellem*

Céline Nourrisson<sup>a,b,c</sup>, Samia Hamane<sup>d</sup>, Julie Bonhomme<sup>e</sup>, Marie-Fleur Durieux<sup>f</sup>, Jean-Baptiste Foulquier<sup>g</sup>, Sophie Lesthelle<sup>h</sup>, Maxime Moniot<sup>a,b</sup>, French microsporidiosis network<sup>i</sup>, Marie-Elisabeth Bougnoux<sup>j</sup> and Philippe Poirier<sup>a,b,c</sup>

<sup>a</sup>Service de Parasitologie-Mycologie, 3IHP, CHU Clermont-Ferrand, Clermont-Ferrand, France; <sup>b</sup>National Reference Center for Cryptosporidiosis, Microsporidia and Other Digestive Protozoa, Clermont-Ferrand, France; <sup>c</sup>Microbes, Intestin, Inflammation et Susceptibilité de l'Hôte (M2ISH), UMR Inserm/Université Clermont Auvergne U1071, USC INRA 2018, Clermont-Ferrand, France; <sup>d</sup>Service de Parasitologie Mycologie, CHU AP-HP Saint-Louis, Paris, France; <sup>e</sup>Service de Parasitologie Mycologie, CHU Caen, ToxEMAC-ABTE, Université de Normandie Unicaen, Caen, France; <sup>f</sup>Service de Parasitologie Mycologie, CHU Limoges, Limoges, France; <sup>g</sup>Cerballiance Finistère, Brest, France; <sup>h</sup>Cerballiance Aquitaine Nord, Le Haillan, France; <sup>i</sup>French Microsporidiosis Network: CH Le Havre (LABBE Franck), CHU Amiens (LE GOVIC Johann, TOTET Anne, DAMIANI Céline), CHU Angers (DE GENTILE Ludovic, LEMOINE Jean-Philippe), CHU Besançon (BELLANGER Anne Pauline), CHU Bichat (HOUBE Sandrine, ARGY Nicolas), CHU Bordeaux (ACCOCEBERRY Isabelle, DELHAES Laurence, GABRIEL Frédéric, MILLET Pascal), CHU Brest (LE GAL Solène, NEVEZ Gilles), CHU Caen (CAPITAINE Agathe), CH Cayenne (DEMAR Magalie), CHU Cochin (YERA Hélène, ROUGES Célia), CHU Créteil (ANGEBAULT Cécile, BOTTEREL Françoise, FOULET Françoise), CHU Dijon (BASMACHIYAN Louise, DALLE Frédéric, VALOT Stéphane), CH Fort-de-France (DESBOIS-NOGARD Nicole), CHU Grenoble (ROBERT Marie Gladys), CHU Lille (DELEPLANCQUE Anne-Sophie, LEROY Jordan), CHU Limoges (AJZENBERG Daniel), CHU Lyon (CHAPEY-PICQ Emmanuelle, DUPONT Damien, MENOTTI Jean, RABODONIRINA Meja), CHU Marseille (LOLLIVIER Coralie), CHU Montpellier (VARLET Marie), CHU Nancy (DEBOURGOGNE Anne, MACHOUART Marie), CHU Nantes (LAVERGNE Rose-Anne, MORIO Florent), CHU Necker (SITTERLE Emilie), CHU Nice (DELAUNAY Pascal, POMARES Christelle, SIMON Loïc), CHU Nîmes (SASSO Milène), CHU Paris HEGP (DANNAOUI Eric), CHU Pitié-Salpêtrière (KAPEL Nathalie, TANTAOUI Ilhame, THELLIER Marc), CHU Pointe-à-Pitre (NICOLAS Muriel), CHU Poitiers (PERRAUD Estelle), CHU Reims (CHEMLA Cathy, VILLENA Isabelle), CHU Rennes (AUTIER Brice), CHU Rouen (COSTA Damien, FAVENNEC Loïc), CHU Saint Antoine (BELKACEM BELKADI Ghania, MORENO-SABATER Alicia), CHU Saint-Etienne (FLORI Pierre), CHU Strasbourg (BRUNET Julie), CHU Toulouse (BERRY Antoine, IRIART Xavier), CHU Tours (CHESNAY Adélaïde, DESOUBEAUX Guillaume), Lab. Bioceane (ARTUR Fabienne), Lab. CERBA (VERDURME Laura), Lab. Cerballiance Finistère (PRIGENT Gwenole), Lab. GLBM (CHATELAIN Rémi), Lab. Labouest (AUBIN Guillaume); <sup>j</sup>Unité de Parasitologie Mycologie, AP-HP hôpital Necker-Enfants malades, Université Paris Cité, Paris, France

### ABSTRACT

Intestinal microsporidiosis is most often caused by *Enterocytozoon bieneusi*, and to a lesser extent by species of the genus *Encephalitozoon*. Until now, *Encephalitozoon hellem* was not clearly known to induce disease restricted to the intestine, or rarely in HIV subjects or in tropical countries. We report here 11 cases of delineated intestinal microsporidiosis due to *E. hellem* diagnosed in France in non-HIV patients. Briefly, all patients were immunocompromised. They all suffered from diarrhoea, associated in nearly 50% of cases with weight loss. Concerning treatment, 5/11 patients had a discontinuation or a decrease of their immunosuppressive therapy, and 4/11 received albendazole. All patients recovered. Five different genotypes were identified based on the rRNA ITS sequence.

**ARTICLE HISTORY** Received 16 July 2023; Accepted 11 September 2023

**KEYWORDS** *Encephalitozoon hellem*; microsporidiosis; diarrhea; intestinal disease; internal transcribed spacer

### Introduction



Microsporidia are obligate intracellular eukaryotes infecting a wide range of animals, including humans [1]. Human intestinal microsporidiosis mainly involves *Enterocytozoon bieneusi*, and less frequently microsporidia belonging to the *Encephalitozoon* genus. Among the latter, *E. intestinalis* is considered to be the most frequently responsible for intestinal infection, whereas *E. hellem* and *E. cucinuli* infections have been reported in extra-intestinal infections [1].

Here, we report 11 cases of delineated intestinal microsporidiosis caused by *E. hellem* collected as part of the French National Reference Center (NRC) for microsporidiosis since 2018.

### Materials and methods

#### Ethics

This study was carried out under the supervision of the NRC for “Cryptosporidiosis, Microsporidia and other digestive protozoa” and benefited from

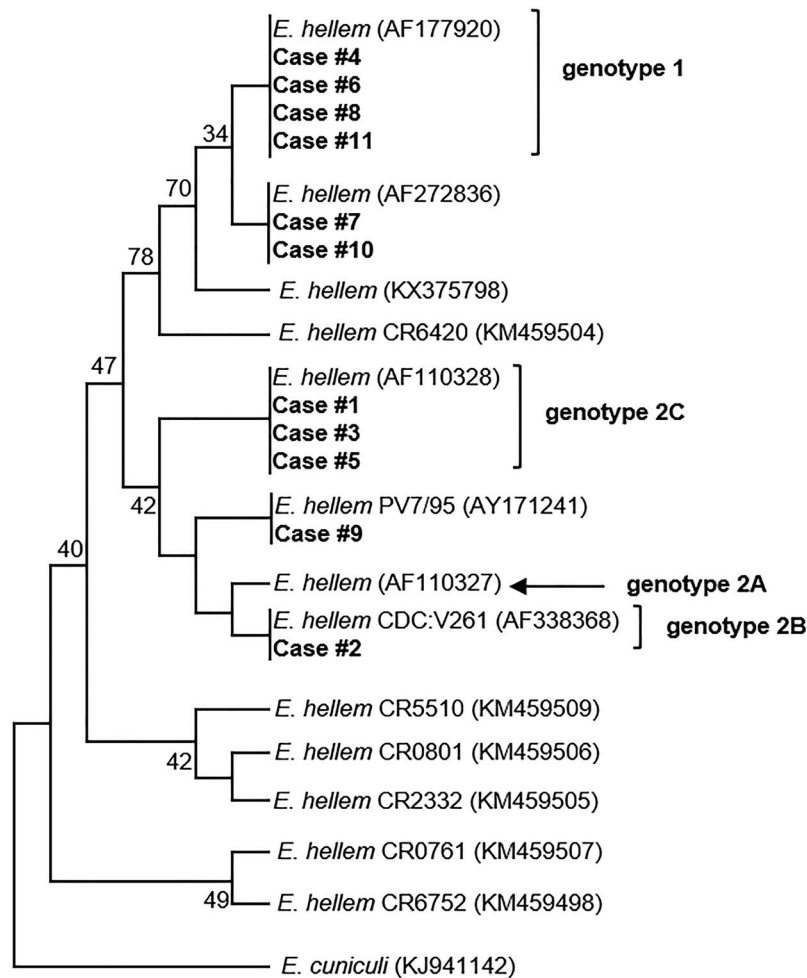
**CONTACT** Philippe Poirier  ppoirier@chu-clermontferrand.fr  Service de Parasitologie-Mycologie, CHU Gabriel Montpied, 58 rue Montalembert, Clermont-Ferrand 63000, France

© 2023 The Author(s). Published by Informa UK Limited, trading as Taylor & Francis Group, on behalf of Shanghai Shangyixun Cultural Communication Co., Ltd. This is an Open Access article distributed under the terms of the Creative Commons Attribution-NonCommercial License (<http://creativecommons.org/licenses/by-nc/4.0/>), which permits unrestricted non-commercial use, distribution, and reproduction in any medium, provided the original work is properly cited. The terms on which this article has been published allow the posting of the Accepted Manuscript in a repository by the author(s) or with their consent.

**Table 1.** Characteristics of the 11 patients of this report who presented delineated intestinal infection caused by *Encephalitozoon hellem*.

Case #	Year of diagnosis	Sex, Age (yrs)	History	IS treatment	Symptoms	Symptoms duration at diagnosis	Diagnostic confirmation by NRC*: Ct value / nb spores per field	Other pathogens	Cares and treatment	Outcome at 3 months
#1	2018	F, 74	Kidney transplant	MMF	Diarrhea, abdominal pain, dehydration, weight loss, vomiting, nausea, fever	6 days	25 / 4	None	Hospitalization Discontinuation of IS treatment	Recovery
#2	2019	M, 47	Kidney transplant	MMF	Diarrhea, vomiting	5 days	26 / 4	None	Hospitalization Albendazole Decrease of IS treatment	Recovery
#3	2019	F, 62	Kidney transplant	MMF	Diarrhea, weight loss	1 month	34 / <1	None	Hospitalization Decrease of IS treatment	Recovery
#4	2019	M, 52	Primary immune deficiency	Corticosteroid	Diarrhea, nausea	1 month	34 / <1	<i>Clostridioides difficile</i>	Hospitalization	Recovery
#5	2020	M, 78	Kidney transplant	Ciclosporine	Diarrhea, weight loss, nausea	1 week	25 / 2	None	Hospitalization Albendazole Decrease of IS treatment	Recovery
#6	2021	M, 52	Liver transplant	n.a.	Diarrhea	n.a.	32 / 1	n.a.	n.a.	n.a.
#7	2021	M, 19	Leukemia (ALL B relapse)	Corticosteroid Methotrexate Chemo-therapy (VANDA)	Diarrhea	1 week	20 / 10	None	Hospitalization	Recovery
#8	2021	M, 35	Kidney transplant	Corticosteroid Tacrolimus MMF	Diarrhea, weight loss	1 month	34 / <1	<i>Cryptosporidium</i>	Hospitalization Albendazole Rifaximine	Recovery
#9	2022	M, 33	Kidney transplant	Tacrolimus MMF	Diarrhea	3 weeks	22 / 1	None	Decrease of IS treatment	Recovery
#10	2022	M, 58	Heart transplant	Tacrolimus MMF	Diarrhea	1 week	22 / 5	None	Albendazole	Recovery
#11	2022	F, 76	Kidney transplant	Tacrolimus MMF	Diarrhea, fever, weight loss, respiratory symptoms	2 weeks	25 / 1	Influenza A and SARS-CoV2 infections	Hospitalization	Recovery

Notes: ALL: acute lymphoblastic leukemia; F: female; HSCT: hematopoietic stem cell transplantation; IS: immunosuppressive; M: male; MMF: mycophenolate mofetil; n.a.: not available; nb: number; NRC: National Reference Center for microsporidiosis; VANDA regimen: etoposide, asparaginase, mitoxantrone, dexamethasone; yrs: years; \*: cycle threshold (Ct) value for qPCR and number (nb) of spores per field of a fecal smear with magnification  $\times 1000$  for Uvitex-2B.



**Figure 1.** Phylogenetic analysis of ITS sequences of *Encephalitozoon hellem* isolates from the present study and reference sequences (outgroup: *Encephalitozoon cuniculi*). The evolutionary history was inferred by using the Maximum Likelihood method based on the Hasegawa-Kishino-Yano model with a discrete Gamma distribution (10,000 replicates). Best model determination and phylogenetic analyses were performed using MEGA 7 software [4].

agreements with the French Data Protection Agency (CNIL) and certification by the ethics committee for the use of the NRC database.

### Cases identification and diagnosis confirmation

Forty-five French medical laboratories collaborate to the NRC for “Cryptosporidiosis, Microsporidia and other digestive protozoa,” including 35 university hospitals, 3 hospitals and 7 private medical laboratories. Microsporidiosis cases diagnosed in each of these centres are reported to the NRC, and the clinical and epidemiological data are compiled. The 11 cases included in the study were diagnosed by real-time PCR in 7 of these French centers (in-house or commercial PCR depending on the center). Stools were then sent to the NRC where microscopic examination was performed on stools (Uvitex-2B fluorescent dye), and diagnosis was confirmed by sequencing a part of the internal transcribed spacer (ITS) rDNA region, as previously described [2]. All sequences were deposited in GenBank (accession numbers: OQ750536 to OQ750546).

### Results

The main characteristics of the 11 cases are reported in Table 1. The majority of cases were diagnosed in adult males ( $n = 8/11$ ). All cases occurred in immunocompromised patients, mainly solid organ transplant (SOT) patients ( $n = 9/11$ ). The two non-SOT cases were diagnosed respectively in a patient suffering from a primary immune deficiency and a patient with acute lymphoblastic leukemia. All cases presented with diarrhea sometimes associated with general digestive symptoms and weight lost. The symptoms of the majority of patients ( $n = 10/11$ ) were limited to digestive tract. Only one patient (case #11) reported respiratory symptoms but he was simultaneously infected with influenza A and SARS-CoV2 viruses. Digestive symptoms lasted an average of 2 weeks [5 days to 4 weeks] before diagnosis. The majority of patients were hospitalized for further care ( $n = 8/10$ ; 1 missing data). For SOT patients, treatment consisted of dose reduction or discontinuation of immunosuppressive therapy ( $n = 5/10$ ), and/or administration of albendazole ( $n = 4/10$ ). Three patients recovered without any

**Table 2.** Literature review of cases where *E. hellem* was detected in stool.

Article type	Year (if known)	Context	Symptoms	Diagnostic tools	Country	Nb of positive patients for <i>E. hellem</i> [nb of positive patients for microsporidia]	Refs.
Cohort study	1998	Diarrhea on return from different tropical areas	Diarrhea	Uvitex 2B staining and PCR	Singapore for the 2 <i>E. hellem</i>	2/148 (co-infected with <i>E. bienewi</i> ) [9/148]	[10]
Cohort study	n.a.	HIV/AIDS	Chronic diarrhea	Oligonucleotide microarray	USA	2/20 (co-infected with <i>E. cuniculi</i> or <i>E. intestinalis</i> ) [12/20]	[12]
Cohort study	between 1992 and 2003	HIV/AIDS	Diarrhea	FISH	USA	2/110	[11]
Cohort study	n.a.	Breast cancer patients, 6 rounds of treatment	Gastritis	Modified trichrome stain and nested PCR for positive specimen	Malaysia	1/311 (co-infected with <i>E. intestinalis</i> ) [68/311]	[9]
Cohort study	n.a.	HIV/AIDS or myeloma	n.a.	Modified trichrome stain and PCR	Tunisia	1/86 [9/86]	[13]
Cohort study	between 2006 and 2009	HIV/AIDS (most of patients had not received cART)	Chronic or acute diarrhea	Histochemical staining or PCR and sequencing	Russia	1/159 [30/159]	[7]
Case report	2006	CD4+ T-cell prolymphocytic leukemia, 12 courses of alemtuzumab and pentostatin	Burning urination, diarrhea, fever, general weakness, anorexia, weight loss	Uvitex 2B and Weber's modified trichrome stains: spores in urine and stools; then SSU rRNA sequencing	France	/	[6]
Cohort study	n.a.	Immunocompromised patients (AIDS, Hodgkin lymphoma, hemodialysis for the 4 <i>E. hellem</i> cases)	n.a.	Modified trichrome stain and multiplex/nested PCR + sequencing	Iran	4/310 [88/310]	[14]
Cohort study	n.a.	Leukemic children on chemotherapy	n.a.	Modified trichrome stain and PCR + sequencing	Egypt	3/100 [29/100]	[8]

Notes: Articles are listed by year of publication.

F: female; FISH: fluorescence in situ hybridization; IS: immunosuppressive; M: male; n.a.: not available; nb: number; Ref: reference; SSU: small subunit

specific care. All those for whom data were available (1 missing data) were cured.

The source of contamination could not be identified for any of the cases. Two patients had recently travelled to the tropics before reporting symptoms (case #7 lived in Guyana and case #8 returned from a trip to Mali).

According to ITS genotypes defined by Xiao et al. [3], *E. hellem* isolates from cases 4, 6, 8 and 11 belong to genotype 1 (Figure 1, A); from case 2 to genotype 2B; from cases 1, 3 and 5 to genotype 2C. Isolates from cases #7 and 10 were identical to a strain previously reported in Hummingbirds (AF272836) and closely related to genotype 1. Isolate from case #9 was identical to the PV7/95 (AY171241) strain isolated from an HIV patient, and related to genotype 2.

## Discussion

*E. hellem* is essentially encountered in birds, even though it was also detected in mammalian [3]. In humans, *E. hellem* was rarely reported to be responsible for intestinal microsporidiosis (cases reviewed in Table 2). These previous cases involved mainly HIV/AIDS patients and/or those who had visited countries with a low sanitary level [5–13]. Furthermore, few clinical data are available in previous

studies, making it impossible to conclude whether *E. hellem* infection is restricted to the intestinal tract.

We describe here for the first time a cases series of delineated intestinal infections caused by *E. hellem*. In our study, these infections only occurred in immunocompromised patients but no patient was HIV-seropositive. The overrepresentation of SOT patients reflects the immunocompromised population currently at risk for intestinal microsporidiosis in France. We recognize that it would have been necessary to search for *E. hellem* in other specimens than stool to assess intestinal delineated infection, but none of patients presented extra intestinal symptoms justifying urinary or respiratory samplings, by example. One patient (case #8) benefited from an extension assessment with microsporidia search in two different urine samples which were negative. Interestingly, all samples positive for *E. hellem* which have been referred to the NRC for microsporidiosis since 2018 were these 11 cases. So, extra intestinal infections that were reported in the literature can probably be considered as extremely rare events, and/or, that non-HIV immunocompromised subjects are less frequently at risk of extra-intestinal infections. Moreover, as diagnosis of the 11 cases reported here were performed in different laboratories, the PCR techniques were not the same and some have identified the

presence of *E. intestinalis*. Indeed, we have previously demonstrated that *E. hellem* is misidentified as *E. intestinalis* with some current commercial or in-house PCRs assay [14]. So we hypothesized that the number of *E. hellem* intestinal infection cases has been underestimated until now. Since 2018, the French NRC for microsporidiosis recorded 12 cases of *E. intestinalis* infections (confirmed by ITS sequencing), making *E. hellem* as frequent as *E. intestinalis* for *Encephalitozoon*-associated intestinal microsporidiosis.

We also explored the hypothesis of particular *E. hellem* genotypes that could be involved in delineated intestinal infections. Indeed, several *E. hellem* genotypes have been previously described based on the rRNA ITS sequence [15, 16]. However, among the 11 new cases we reported, we identified five different ITS genotypes, some of them being also reported from extra-intestinal infections in the literature [17].

In summary, this study highlights that *E. hellem* may be a cause as frequent as *E. intestinalis* for delineated intestinal microsporidiosis in immunocompromised patients in France.

## Disclosure statement

No potential conflict of interest was reported by the author(s).

## Funding

This work was supported in part by the “Santé Publique France” and by the “Direction de la Recherche Clinique et de l’Innovation” of the University Hospital of Clermont-Ferrand (France).

## ORCID

Céline Nourrisson  <http://orcid.org/0000-0002-4003-805X>  
Philippe Poirier  <http://orcid.org/0000-0001-9173-2634>

## References

- [1] Han B, Pan G, Weiss LM. Microsporidiosis in humans. *Clin Microbiol Rev.* 2021 Dec 15;34(4):e0001020.
- [2] Katzwinkel-Wladarsch S, Lieb M, Helse W, et al. Direct amplification and species determination of microsporidian DNA from stool specimens. *Trop Med Int Health TM IH.* 1996;1(3):373–378. doi:10.1046/j.1365-3156.1996.d01-51.x
- [3] Xiao L, Li L, Moura H, et al. Genotyping *Encephalitozoon hellem* isolates by analysis of the polar tube protein gene. *J Clin Microbiol.* 2001;39(6):2191–2196. doi:10.1128/JCM.39.6.2191-2196.2001
- [4] Kumar S, Stecher G, Tamura K. Mega7: molecular evolutionary genetics analysis version 7.0 for bigger datasets. *Mol Biol Evol.* 2016;33(7):1870–1874. doi:10.1093/molbev/msw054
- [5] Hinney B, Sak B, Joachim A, et al. More than a rabbit’s tale – *Encephalitozoon* spp. in wild mammals and birds. *Int J Parasitol Parasites Wildl.* 2016;5(1):76–87. doi:10.1016/j.ijppaw.2016.01.001
- [6] Nevez G, Le Gal S, Quinio D, et al. *Encephalitozoon hellem* in a patient with CD4+ T-cell prolymphocytic leukemia: case report and genomic identification. *Diagn Microbiol Infect Dis.* 2015;83(3):245–247. doi:10.1016/j.diagmicrobio.2015.07.015
- [7] Sokolova OI, Demyanov AV, Bowers LC, et al. Emerging microsporidian infections in Russian HIV-infected patients. *J Clin Microbiol.* 2011;49(6):2102–2108. doi:10.1128/JCM.02624-10
- [8] Shehab AY, Moneer EA, Allam AF, et al. Intestinal microsporidia infection in leukemic children: microscopic and molecular detection. *Acta Parasitol.* 2021;66(2):346–353. doi:10.1007/s11686-020-00283-2
- [9] Lono AR, Kumar S, Chye TT. Incidence of microsporidia in cancer patients. *J Gastrointest Cancer.* 2008;39(1–4):124–129. doi:10.1007/s12029-009-9065-z
- [10] Müller A, Bialek R, Kämper A, et al. Detection of microsporidia in travelers with diarrhea. *J Clin Microbiol.* 2001;39(4):1630–1632. doi:10.1128/JCM.39.4.1506-1509.2001
- [11] Graczyk TK, Johansson MA, Tamang L, et al. Retrospective species identification of microsporidian spores in diarrheic fecal samples from human immunodeficiency virus/AIDS patients by multiplexed fluorescence in situ hybridization. *J Clin Microbiol.* 2007;45(4):1255–1260. doi:10.1128/JCM.01975-06
- [12] Wang Z, Orlandi PA, Stenger DA. Simultaneous detection of four human pathogenic microsporidian species from clinical samples by oligonucleotide microarray. *J Clin Microbiol.* 2005;43(8):4121–4128. doi:10.1128/JCM.43.8.4121-4128.2005
- [13] Chabchoub N, Abdelmalek R, Mellouli F, et al. Genetic identification of intestinal microsporidia species in immunocompromised patients in Tunisia. *Am J Trop Med Hyg.* 2009;80(1):24–27. doi:10.4269/ajtmh.2009.80.24
- [14] Tavalla M, Mardani-Kateki M, Abdizadeh R, et al. Molecular identification of *Enterocytozoon bienewsi* and *Encephalitozoon* spp. in immunodeficient patients in Ahvaz, Southwest of Iran. *Acta Trop.* 2017;172:107–112. doi:10.1016/j.actatropica.2017.04.015
- [15] Moniot M, Nourrisson C, Bonnin V, et al. Evaluation of the bio-evolution microsporidia generic and typing real-time PCR assays for the diagnosis of intestinal microsporidiosis. *Parasite Paris Fr.* 2022;29:55. doi:10.1051/parasite/2022055
- [16] Mathis A, Tanner I, Weber R, et al. Genetic and phenotypic intraspecific variation in the microsporidian *Encephalitozoon hellem*. *Int J Parasitol.* 1999;29(5):767–770. doi:10.1016/S0020-7519(99)00025-9
- [17] Haro M, Del Aguila C, Fenoy S, et al. Intraspecies genotype variability of the microsporidian parasite *Encephalitozoon hellem*. *J Clin Microbiol.* 2003;41(9):4166–4171. doi:10.1128/JCM.41.9.4166-4171.2003