



HAL
open science

Simultaneous occurrence of insulin-derived amyloidosis and acanthosis nigricans at the abdominal site of insulin injection

Chloe Vuillamy, Jean-Philippe Arnault, Christophe Attencourt, Ali Dadban, Camille Joachim, Guillaume Chaby, Catherine Lok

► **To cite this version:**

Chloe Vuillamy, Jean-Philippe Arnault, Christophe Attencourt, Ali Dadban, Camille Joachim, et al.. Simultaneous occurrence of insulin-derived amyloidosis and acanthosis nigricans at the abdominal site of insulin injection. *JAAD Case reports*, 2022, 19, pp.94-96. 10.1016/j.jdcr.2021.11.003 . hal-04466347

HAL Id: hal-04466347

<https://u-picardie.hal.science/hal-04466347v1>

Submitted on 22 Jul 2024

HAL is a multi-disciplinary open access archive for the deposit and dissemination of scientific research documents, whether they are published or not. The documents may come from teaching and research institutions in France or abroad, or from public or private research centers.

L'archive ouverte pluridisciplinaire **HAL**, est destinée au dépôt et à la diffusion de documents scientifiques de niveau recherche, publiés ou non, émanant des établissements d'enseignement et de recherche français ou étrangers, des laboratoires publics ou privés.

Copyright

Simultaneous occurrence of insulin-derived amyloidosis and acanthosis nigricans at the abdominal site of insulin injection

❖ Authors:

Chloe Vuillamy, MD, *Centre Hospitalier Universitaire Amiens-Picardie, Amiens, France.*

Jean-Philippe Arnault, MD, *Centre Hospitalier Universitaire Amiens-Picardie, Amiens, France.*

Christophe Attencourt, MD, *Centre Hospitalier Universitaire Amiens-Picardie, Amiens, France.*

Ali Dadban, MD, *Centre Hospitalier Universitaire Amiens-Picardie, Amiens, France.*

Camille Joachim, MD, *Centre Hospitalier Universitaire Amiens-Picardie, Amiens, France.*

Guillaume Chaby, MD, *Centre Hospitalier Universitaire Amiens-Picardie, Amiens, France.*

Catherine Lok, PhD, *Centre Hospitalier Universitaire Amiens-Picardie, Amiens, France.*

❖ Word count: 791

❖ Number of references: 10

❖ Number of figures: 5

❖ The authors report no conflicts of interest. For this work, we had no funding sources.

❖ Correspondant: Chloe Vuillamy

Appartement 51B

Avenue du maréchal Lyautey

59130 Lambersart

France

Tel: 0033652277755

Email: chloevuillamy@hotmail.fr

1 Introduction

2 The most common complications of subcutaneous insulin injection are lipoatrophy,
3 lipohypertrophy, and localized allergic reactions. More rarely, skin abscesses, insulin edema,
4 insulin allergy, **acanthosis nigricans (AN)**, and insulin-derived amyloidosis have been reported
5 at insulin injection sites(1). **We report a patient** with concomitant insulin-derived amyloidosis
6 and **AN** at the abdominal site of insulin injection.

7 Case report

8 A 68-year-old female patient with a history of hypertension, liver transplant for nonalcoholic
9 steatohepatitis cirrhosis and 30-year history of type 2 diabetes presented with growing
10 asymptomatic plaques on the abdomen. Her anti-rejection treatment consisted of
11 mycophenolate mofetil and tacrolimus. Insulin glargine and insulin lispro were started 10 years
12 before the visit. **Abdominal plaques appeared at injection sites but treatment was continued 1.5**
13 **years prior to presentation when treatment was changed to insulin glargine and insulin aspart**
14 **due to worsening blood glucose control.**

15 Physical examination showed 2 **large** hyperkeratotic, hyperpigmented and **indurated** plaques
16 symmetrically located on either side of the umbilicus. No masses were palpable. **Along the**
17 **superior edge**, the plaques were confined by the liver transplantation scar (Figure 1a).
18 Examination of the back of the neck and armpits revealed **AN**.

19 Histologic examination of the abdomen showed hyperkeratosis and papillomatosis with mild
20 acanthosis, confirming **AN** (Figure 2a). Examination of the dermis revealed masses of
21 eosinophilic and amorphous material. The deposit stained orange-red with Congo red (Figure
22 2b) and showed green birefringence under polarized light (Figure 2c) that is diagnostic for
23 amyloidosis. The amyloid deposit showed positive staining with anti-insulin and anti-serum
24 amyloid A (SAA) antibodies.

25 Based on these findings, a diagnosis was made of insulin-derived amyloidosis associated with
26 **AN** at the site of insulin injection.

27 **Surgical excision was considered, but not considered feasible in view of the absence of a**
28 **palpable mass. Clobetasol propionate cream applied once daily resulted in no clinical change.**
29 **Topical adapalene 0,1% resulted in significant reduction in appearance of clinical plaques.**
30 **Induration however persisted** (Figure 1b).

31 Discussion

32 **Amyloid deposition** at the injection site of porcine insulin was described for the first time in
33 1988 by Dische *et al.* (2). Since then, at least 86 cases of insulin-derived amyloidosis have been
34 reported (3). Any type of insulin can cause insulin amyloidosis (3).

35 The usual clinical presentation is a rigid subcutaneous mass at the site of insulin injection.
36 Nagase *et al.* reported 2 cases of insulin-derived amyloidosis without a palpable mass,
37 suggesting that its incidence may be underestimated(4).

38 Patients often show poor glycemic control because of local degradation of insulin in amyloid
39 or trapping of insulin in amyloid fibrils after injection(5). Patients may also present with severe
40 hypoglycemia due to erratic absorption from the affected site.

41 Diagnosis is confirmed by histopathology with the presence of amyloid positively stained by
42 an antibody against insulin(6).

43 Lipohypertrophy is the most common differential diagnosis(6). This localized reaction site is
44 less firm and solid than an amyloid tumor and regresses after cessation of insulin injections.

45 The treatment for insulin-derived amyloidosis is to avoid the injections at the sites of
46 amyloidosis or surgery(6). Surgical excision can result in improved glycemic control in cases
47 of localized amyloid tumors.

48 AN at the site of insulin injection is another rare complication of insulin injection, with a dozen
49 cases reported(7). The patients are mostly men. The abdomen is the most commonly affected
50 site. For 2 patients, plaques disappeared after rotating the injection site. The pathophysiology
51 remains unknown, but may be the same as in benign AN. High concentrations of insulin in the
52 epidermis may bind to IGF-1 (insulin-like growth factor 1) receptors on keratinocytes,
53 stimulating proliferation and inducing hyperkeratosis(8).

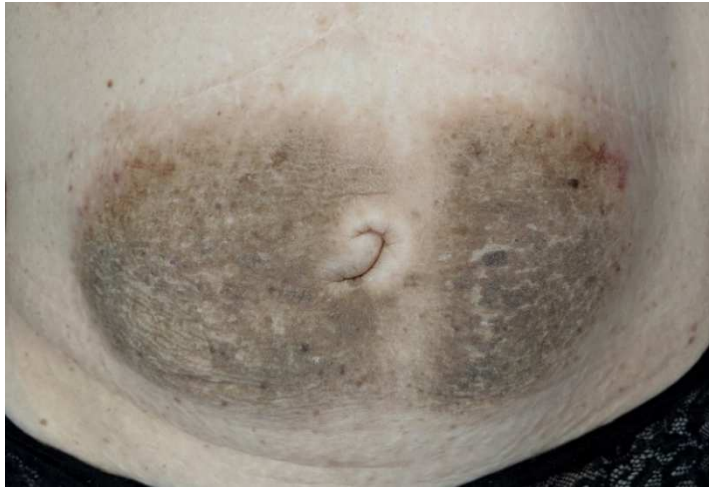54 To our knowledge, this is the third reported case of a simultaneous occurrence of insulin-
55 derived amyloidosis and AN at the site of insulin injection. The first case reported a 59-year-
56 old man whose dermatosis was located on the abdomen and was secondary to the use of human
57 insulin(9). The second case, published in 2014, reports on a 54-year-old man, and the
58 dermatosis also located on the abdomen. The insulin used was recombinant human insulin
59 without further details(10). The clinical presentation was similar to our patient.

60 Because our patient was seen many years after occurrence of AN and insulin-derived
61 amyloidosis, it is difficult to know which pathology occurred first. We offer two hypotheses as
62 to why these two conditions might co-occur. Firstly, it is possible that the presence of
63 induration from amyloid led to more superficial insulin injection, with higher concentrations
64 of insulin in the epidermis resulting in AN. Another possibility is that amyloid hindered
65 absorption of insulin and poorer glycemic control, requiring increased doses of insulin and
66 development of AN.

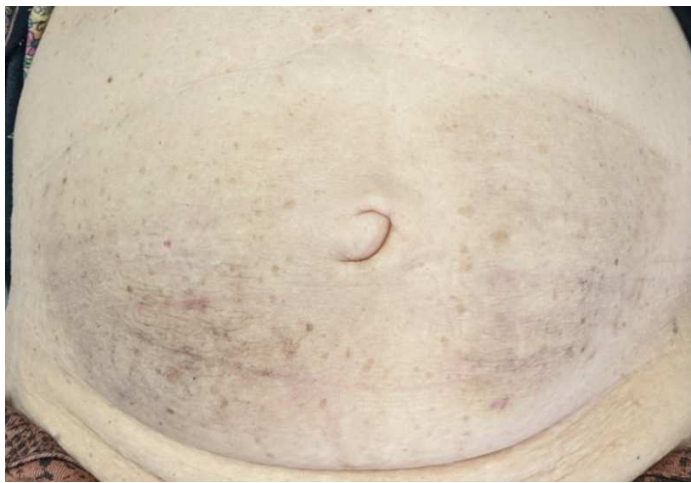67 Conclusion

68 Although insulin-derived amyloidosis and AN are uncommon complications of insulin
69 injection, dermatologists must be aware of them. Prevention of these complication can be
70 achieved by rotating insulin injection sites, self-monitoring, and use of fine needles.

71

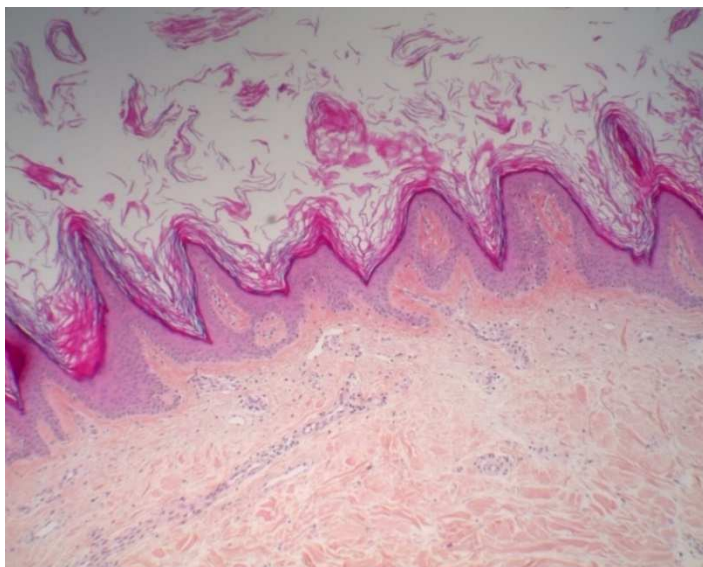


80 Figure 1a: Hyperkeratotic plaques located on either side of the umbilicus

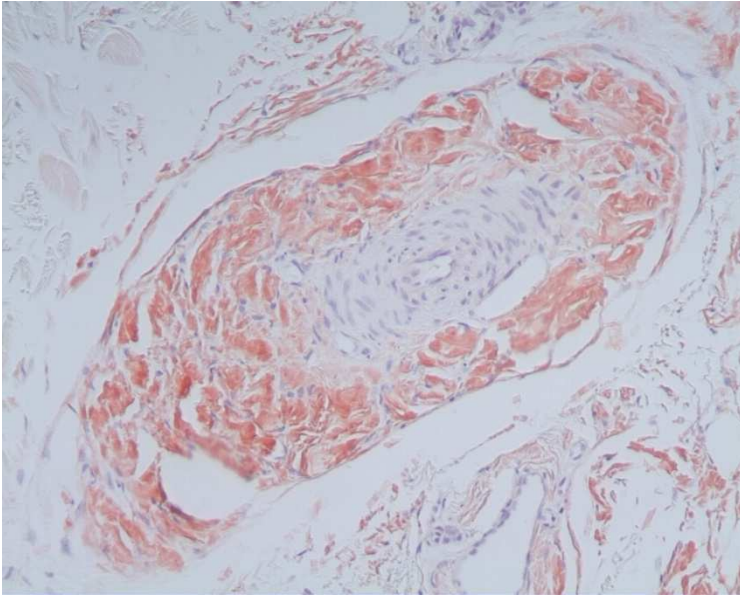


81

82 Figure 1b: Improvement after 4 months of topical retinoid treatment



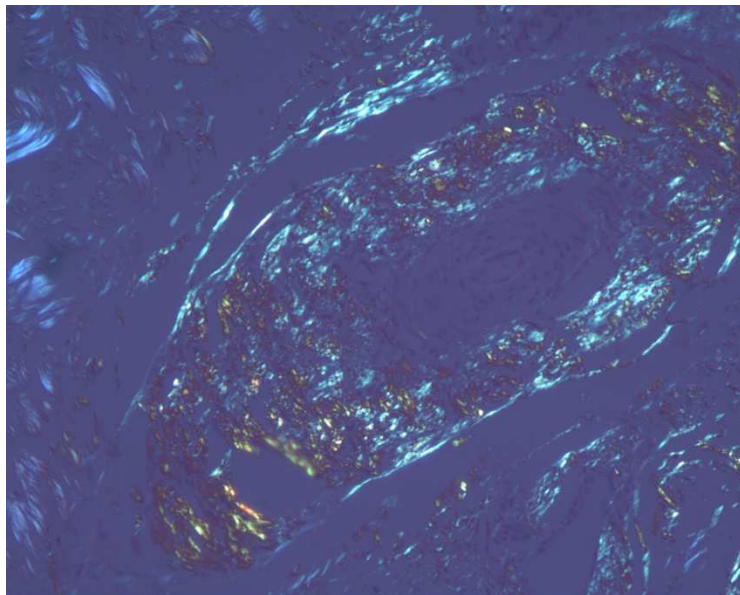
93 Figure 2a: Hyperkeratosis and papillomatosis (HES, x6,5)



104 Figure 2b: Cutaneous amyloidosis : amyloid deposits Congo red positive (x15)

105

106



117 Figure 2c: Cutaneous amyloidosis : apple-green birefringence in polarized light (x15)

1. Richardson T, Kerr D. Skin-Related Complications of Insulin Therapy: Epidemiology and Emerging Management Strategies. *Am J Clin Dermatol*. 2003;4(10):661–7.
2. Insulin as an amyloid-fibril protein at sites of repeated insulin injections in a diabetic patient. :4.
3. Nilsson MR. Insulin amyloid at injection sites of patients with diabetes. *Amyloid*. 2016 Jul 2;23(3):139–47.
4. Nagase T, Iwaya K, Kogure K, Zako T, Misumi Y, Kikuchi M, et al. Insulin - derived amyloidosis without a palpable mass at the insulin injection site: A report of two cases. *J Diabetes Investig*. 2020 Jul;11(4):1002–5.
5. Nagase T, Iwaya K, Iwaki Y, Kotake F, Uchida R, Oh-i T, et al. Insulin-derived Amyloidosis and Poor Glycemic Control: A Case Series. *Am J Med*. 2014 May;127(5):450–4.
6. Gupta Y, Singla G, Singla R. Insulin-derived amyloidosis. *Indian J Endocrinol Metab*. 2015;19(1):174.
7. Bomar L, Lewallen R, Jorizzo J. Localized Acanthosis Nigricans at the Site of Repetitive Insulin Injections. :3.
8. Pal R, Bhattacharjee R, Chatterjee D, Bhadada SK, Bhansali A, Dutta P. Exogenous Insulin-Induced Localized Acanthosis Nigricans: A Rare Injection Site Complication. *Can J Diabetes*. 2020 Apr;44(3):219–21.
9. Kudo-Watanuki S, Kurihara E, Yamamoto K, Mukai K, Chen KR. Coexistence of insulin-derived amyloidosis and an overlying acanthosis nigricans-like lesion at the site of insulin injection: Coexistence of amyloidosis and acanthosis nigricans-like lesion at the site of insulin injection. *Clin Exp Dermatol*. 2013 Jan;38(1):25–9.
10. Nandeesh B, Rajalakshmi T, Shubha B. Cutaneous amyloidosis at the site of insulin injection with coexistence of acanthosis nigricans. *Indian J Pathol Microbiol*. 2014;57:127-9