



HAL
open science

Genome sequencing identify chromosome 9 inversions disrupting ENG in 2 unrelated HHT families

M. Tusseau, M. Eyries, N. Chatron, F. Coulet, A. Guichet, E. Colin, B. Demeer, H. Maillard, J. Thevenon, C. Lavigne, et al.

► To cite this version:

M. Tusseau, M. Eyries, N. Chatron, F. Coulet, A. Guichet, et al.. Genome sequencing identify chromosome 9 inversions disrupting ENG in 2 unrelated HHT families. *European Journal of Medical Genetics*, 2024, 68, pp.104919. 10.1016/j.ejmg.2024.104919 . hal-04473768

HAL Id: hal-04473768

<https://u-picardie.hal.science/hal-04473768>


Submitted on 24 May 2024

HAL is a multi-disciplinary open access archive for the deposit and dissemination of scientific research documents, whether they are published or not. The documents may come from teaching and research institutions in France or abroad, or from public or private research centers.

L'archive ouverte pluridisciplinaire **HAL**, est destinée au dépôt et à la diffusion de documents scientifiques de niveau recherche, publiés ou non, émanant des établissements d'enseignement et de recherche français ou étrangers, des laboratoires publics ou privés.



Distributed under a Creative Commons Attribution - NonCommercial 4.0 International License



Genome sequencing identify chromosome 9 inversions disrupting *ENG* in 2 unrelated HHT families

M. Tusseau^{a,b}, M. Eyries^{c,d}, N. Chatron^{a,b}, F. Coulet^{c,d}, A. Guichet^e, E. Colin^e, B. Demeer^{f,g}, H. Maillard^h, J. Thevenon^b, C. Lavigneⁱ, V. Saillour^d, C. Paris^b, J.M. De Sainte Agathe^{c,d}, M. Pujalte^{a,b}, A. Guilhem^a, S. Dupuis-Girod^a, G. Lesca^{a,b,*}

^a Hospices Civils de Lyon, Department of Medical Genetics and National HHT Reference Center, University Hospital of Lyon, Lyon, France

^b Laboratoire AURAGEN, Lyon, France

^c Department of Medical Genetics, AP-HP Sorbonne University, Paris, France

^d Laboratoire Multisites SeqOIA, Paris, France

^e Service de Génétique Médicale, CHU D'Angers, Angers, France

^f Genetics Department, CLAD Nord de France, CHU Amiens, France

^g CHIMERE, UR UPJV 7516, Université Picardie Jules Verne, Amiens, France

^h Department of Internal Medicine and Clinical Immunology, Referral Centre for Rare Systemic Autoimmune Diseases for North and North-West France (CeRAINO), CHU Lille, 59000, Lille, France

ⁱ Department of Internal Medicine and Clinical Immunology, Angers University Hospital, Angers, France

ARTICLE INFO

Handling Editor: A. Verloes

Keywords:

HHT
Genome sequencing
Inversion

ABSTRACT

Hereditary hemorrhagic telangiectasia (HHT), also known as Rendu-Osler-Weber disease, is a dominant inherited vascular disorder. The clinical diagnosis is based on the Curaçao criteria and pathogenic variants in the *ENG* and *ACVRL1* genes are responsible for most cases of HHT.

Four families with a negative targeted gene panel and selected by a multidisciplinary team were selected and whole-genome sequencing was performed according to the recommendations of the French National Plan for Genomic Medicine. Structural variations were confirmed by standard molecular cytogenetic analysis (FISH).

In two families with a definite diagnosis of HHT, we identified two different paracentric inversions of chromosome 9, both disrupting the *ENG* gene. These inversions are considered as pathogenic and causative for the HHT phenotype of the patients.

This is the first time structural variations are reported to cause HHT. As such balanced events are often missed by exon-based sequencing (panel, exome), structural variations may be an under-recognized cause of HHT. Genome sequencing for the detection of these events could be suggested for patients with a definite diagnosis of HHT and in whom no causative pathogenic variant was identified.

1. Introduction

HHT (hereditary hemorrhagic telangiectasia), also called Rendu-Osler-Weber disease is an autosomal dominant vascular disease characterized by mucocutaneous telangiectases and frequent epistaxis. Visceral complications may include pulmonary, hepatic, or central nervous system arteriovenous malformations. The penetrance is high and the expressivity is highly variable.

The clinical diagnosis, as defined by the Curaçao criteria (Shovlin et al., 2000), is based on the following four criteria: family history (at least a first-degree relative diagnosed with HHT based on these criteria),

recurrent and spontaneous epistaxis, characteristic mucocutaneous telangiectases, and visceral arteriovenous malformations. The diagnosis is considered definite, possible or unlikely, if respectively three, two or less than two criteria are present.

Disease-causing variations of *ENG*, which encodes endoglin (OMIM #187300), and *ACVRL1*, which encodes ALK1 (OMIM #600376), are responsible for around 80–90% of all cases (Lesca et al., 2006). Besides, *SMAD4* that encodes smad4 was also associated with HHT but appeared to be rarely causal (less than 2%) (Gallione et al., 2004) and responsible for a slightly different phenotype of juvenile polyposis/HHT overlap syndrome (JP-HHT, OMIM #175050). Finally, *GDF2* was published in

* Corresponding author. Hospices Civils de Lyon, Department of Medical Genetics and National HHT Reference center, University Hospital of Lyon, Lyon, France.
E-mail address: gaetan.lesca@chu-lyon.fr (G. Lesca).

<https://doi.org/10.1016/j.ejmg.2024.104919>

Received 25 July 2023; Received in revised form 5 January 2024; Accepted 4 February 2024

Available online 12 February 2024

1769-7212/© 2024 The Authors. Published by Elsevier Masson SAS. This is an open access article under the CC BY-NC license (<http://creativecommons.org/licenses/by-nc/4.0/>).

2013 as a new genetic cause of HHT, but considering the few reports ever since, its prevalence in HHT cohort is probably rare (Balachandar et al., 2022; Topiwala et al., 2020).

Accordingly, the strategy for genetic analysis includes a targeted gene panel analysis as a first line. Diagnostic performance of such panels is high and strongly influenced by clinical, as more than 97% of patients with a definite clinical diagnosis have a causal or likely causal variant in *ENG*, *ACVRL1*, or *SMAD4* (McDonald et al., 2020). For years, in-depth analysis of these genes has led to additional rare variants identified in *ENG* promoter or in introns with splicing impact (Damjanovich et al., 2011; Ruiz-Llorente et al., 2019; Albiñana et al., 2017; Wooderchak-Donahue et al., 2018). New sequencing technologies such as genome sequencing (GS) could be used to further investigate these genes concerning complex structural variants.

In France and since 2020, patients with a negative targeted gene panel and selected by a multidisciplinary team have access to genomic sequencing as part of the French National Plan for Genomic Medicine (PFMG). Four families have thus benefited from clinical genome sequencing, revealing in two of them a structural variation (SV) disrupting the *ENG* gene and explaining the HHT phenotype.

2. Materials and methods

2.1. Patients

Each year in France, more than 250 probands with an unlikely, possible or definite diagnosis of HHT according to the Curaçao criteria are tested for HHT with a targeted gene panel and approximately half of them receive a molecular diagnosis.

Four families were selected at a national level by a multidisciplinary team to benefit from genome sequencing in the AURAGEN laboratory (South and Est of France) or in the SeqOIA laboratory (North and North-West). All families have been previously analyzed by a targeted gene panel sequencing that covers at least coding regions of *ENG*, *ACVRL1*, *SMAD4*, *RASA1*, *EPHB4*, *GDF2*, promoters of *ENG* and *ACVRL1*, and introns of *ACVRL1*.

A signed informed consent form was obtained from all the patients.

2.2. Genome sequencing

For families A and B, genome sequencing was performed at the AURAGEN laboratory (LBMMS Auragen, Auvergne Rhône-Alpes) following the recommendations of the PFMG. Whole-blood extracted genomic DNA was sequenced according to standard procedures for a PCR-free genome on a NovaSeq6000 instrument (Illumina). Sequencing data were aligned to the GRCh38p13 full assembly using bwa 0.7+. Variants were called by several algorithms, including GATK4+, Bcftools1.10+, Manta1.6+, CNVnator0.4+, and annotated using the variant effect predictor. Detected variants were prioritized using in-house procedures. Further details are available upon request on the website of the AURAGEN platform (<https://www.auragen.fr>).

Genome sequencing was performed at the SeqOIA laboratory (LBMS SeqOIA, Paris, France) using the same protocols for families C and D. FASTQ files were obtained from the bcl2fastq demultiplexing tool (v2.20.0.422, Illumina) and aligned to the GRCh38.92 genomic reference using BWA-MEM (v0.7.15). Haplotype Caller, GATK (v4.1.7.0) was used to call the SNV and delins (<50bp); variants were annotated by SNPEff (v4.3t). Structural variants were detected by ClinSV (v1.0.1) and WiseCondor (v1.2.4). The resulting SV were then annotated with AnnotSV (v3.0.7) (<https://academic.oup.com/bioinformatics/article/34/20/3572/4970516>). GLEAVES (v3.3.23, in-house software) was used for the variant interpretation and reporting. Further details are available on the website of the LBMS SeqOIA platform (<https://lab-oratoire-seqoia.fr/>).

2.3. Molecular cytogenetic analysis

For patient 1 of family B, metaphase chromosome spreads were prepared from cultured lymphocytes by standard methods before FISH analysis. FISH was performed with a subtelomeric probe for the long arms of chromosome 9 (Cytocell) and with BAC clones either fluorescein labeled by nick-translation (RP11-19J3, 9q22.31) or commercially available (RP11-890G24, 9q33.1, RainbowFISH probe), following standard FISH protocols. Slides were counterstained with DAPI and analyzed with a Zeiss Axio Imager. Z2 microscope. Cell images were captured with Isis software (MetaSystems). Thirty metaphases were analyzed.

For patient 1 of family C, BAC clones were commercially available (RP11-67K19, spectrum orange, 9q33.1 and RP11-165P4 spectrum green, 9q33.2) (RainbowFISH probe), following standard FISH protocols. Slides were counterstained with DAPI and analyzed with an Olympus BX51 microscope. Cell images were captured with Isis software (MetaSystems). Ten metaphases were analyzed.

3. Results

Genome sequencing was performed in four families. First, the diagnosis was unlikely according to the Curaçao criteria in one patient (Family A) with early onset and very severe diffuse pulmonary arteriovenous malformations. Two families (B and C) had a definite diagnosis and in family D, the diagnosis was only possible according to these criteria. Their clinical data are shown in Table 1.

The study of structural variants revealed two inversions involving the *ENG* gene in the two families with a definite clinical diagnosis. In both cases, balanced rearrangements were identified, affecting the orientation of the chromosomal segment without changing the copy number. In family B, we observed a paracentric inversion on chromosome 9 (seq [GRCh38] inv (Albiñana et al., 2017) (q21.33; q34.11) NC_000009.12:g.87,592,471_127847590inv), whose breakpoint interrupts the first intron of *ENG* and another gene, *DAPK1*, which has not been related to a human disease. In terms of disease mechanism, this inversion disrupting *ENG* is responsible for the HHT phenotype in the family. However, this cannot explain the neurodevelopmental disorder in Pt2, as Pt1 and her father were unaffected. Notably, no other pathogenic variations were present in the genome of Pt2.

In family C, another paracentric inversion (seq [GRCh38] inv (Albiñana et al., 2017) (q32; q34.11) (NC_000009.12:g. [113,278,984, 127833381inv, 127833382G > A]) was identified, disrupting intron 2 of *ENG* and exon 3 of *PRPF4*. This gene encodes a spliceosomal protein called HPrp4, which is associated with retinitis pigmentosa 70 (OMIM #615922). The inheritance of the disease is dominant and the variants described (one promoter deletion and two missense) are responsible for either haploinsufficiency or a dominant negative effect (Chen et al., 2014; Linder et al., 2014). However, the medical records of Family C did not mention such a disease, but they were not examined by an ophthalmologist.

Both inversions were confirmed by FISH analysis and can be considered as pathogenic and responsible for the phenotype of the patients (Fig. 1).

In the two remaining families, genomic analysis was inconclusive. In particular, no single nucleotide variants, including deep intronic variations and copy number variation (CNV) were observed in the genes responsible for HHT.

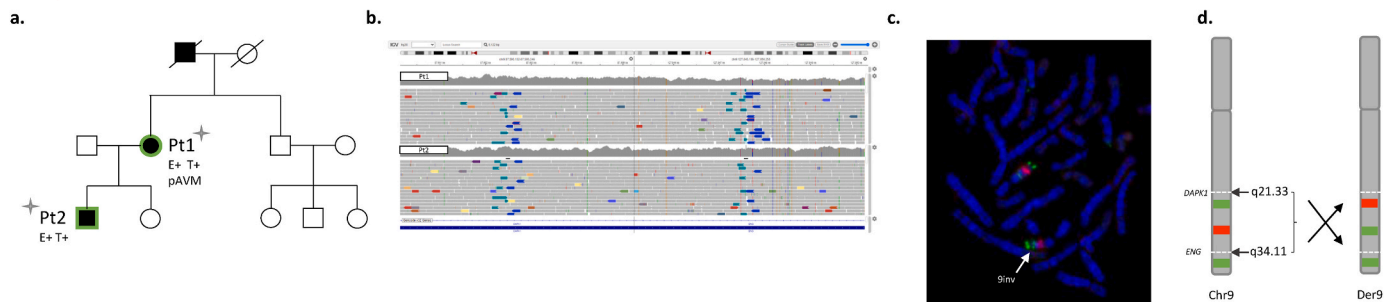
4. Discussion

After a negative HHT gene panel, four families were analyzed by genome sequencing. In two families with a definite diagnosis of HHT, the genome showed a balanced chromosomal rearrangement involving the *ENG* gene. The size of the inverted regions differed, but both breakpoints disrupt the *ENG* gene. Considering the haploinsufficiency

Table 1
Clinical data table of the patients who benefited from genome sequencing.

	Family A, Pt1	Family B, Pt 1	Family B, Pt 2 (son of Pt1)	Family C, Pt1	Family C, Pt2 (daughter of Pt1)	Family D, Pt1	Family D, Pt2 (sister of Pt1)
Age when GS was performed (years)	19	74	47	62	34	45	39
Curaçao criteria							
Epistaxis	No	Frequent - have required iron replacement therapy	Daily	Yes	Frequent (3 times a month)	Only during childhood and adolescence	No
Telangiectases	Absence	Multiple, diffuse (fingers, lips, tongue), sometimes hemorrhagic	Multiple (lips, tongue, palate)	Yes	Yes (tongue)	Multiple (fingers, face, lips, tongue)	Multiple (fingers, face, lips, tongue)
Visceral lesions	Multiple pulmonary arteriovenous malformations diagnosed at the age of 2, treated with 5 embolizations and a lobectomy	Multiple pulmonary arteriovenous malformations requiring embolization	No	Pulmonary and hepatic arteriovenous malformations	Pulmonary and hepatic arteriovenous malformations	Hepatic arteriovenous malformations	Hepatic arteriovenous malformations
Family history of HHT	No	Yes	Yes	Yes	Yes	Yes (sister, father with possible HHT)	Yes (sister, father with possible HHT)
Diagnosis of HHT	Unlikely	Definite	Definite	Definite	Definite	Possible	Possible
Additional features	Seizures	No	Neurodevelopmental disorder	No	No	No	Left thigh arteriovenous fistula
GS result	Negative	NC_000009.12:g.87,592,471_127847590inv		NC_000009.12:g.[113,278,984,127833381inv,127833382G > A]		Negative	

Family B



Family C




Fig. 1. a. Pedigrees of families B and C; carriers of chromosome 9 inversions are represented with a cross; patients with a definite HHT diagnosis are represented in black, patients with isolated epistaxis in gray; patients who benefited from genome sequencing are outlined in green. E+/T+/pAVM or hAVM is indicated in the presence of epistaxis, telangiectases or pulmonary or hepatic arterio-venous malformations, respectively. b. Alignments using Integrative Genomics Viewer (IGV) at the position of both breakpoints. c. For family B: FISH analysis with RP11-19J3 (9q22.31 in green), RP11-890G24 (9q33.1 in red) and subtelomeric probe 9q in green; for Family C: FISH analysis with RP11-165P4 (3q33.1 in green) and RPP1-67K19 (9q33.1 in orange); derivative chromosomes are indicated with an arrow. d. Schematic representation of the chromosome 9 inversions showing the two breakpoints located in q34.11 disrupting ENG, and in 9q21.33 (family B) or 9q31.11 (family C), the derivative chromosome and resulting positions of FISH probes.

mechanism, these inversions can be considered pathogenic and responsible for the HHT phenotype.

In the first family, the inversion at the other breakpoint disrupted a gene, *DAPK1*. This gene encodes a kinase that plays an important role in apoptotic pathways, including neuronal cell death. *DAPK1* is not currently associated with any human genetic disorder, although it is predicted to be intolerant to loss of function variants ($pLi = 1$). However, the phenotype of the family with this inversion was consistent with a diagnosis of typical HHT, with no other associated features that the *ENG* disruption could not explain. In the second family, the second disrupted gene is *PRPF4*, published in 2014 as being responsible for a retinitis pigmentosa (RP) phenotype (OMIM #615922) (Chen et al., 2014; Linder et al., 2014). Patients in this family did not show any ocular phenotypes, suggesting that the penetrance may be incomplete in the case of haploinsufficiency or that another mechanism is responsible for the development of RP (deletion, missense). Since 2014, no other publications have confirmed the association between *PRPF4* and RP.

To our knowledge, this is the first time a structural variation has been reported to cause HHT. Structural variations have been reported in patients with other diseases that share features with HHT, such as dominant inheritance, specific clinical signs and limited or absent genetic heterogeneity. For example, reciprocal translocations have been reported in Marfan syndrome (Pagnamenta et al., 2023; Schnause et al., 2021).

This report highlights the interest of genome sequencing, and particularly the detection of structural variations that are not detectable by a gene panel approach for patients with a definite diagnosis of HHT. These abnormalities could have been missed with standard karyotyping (no visible change in bands), and are inaccessible to MLPA (Multiplex Ligation-dependent Probe Amplification) or array-CGH (because there is no loss of genetic material). This result further confirms the great genetic homogeneity of HHT and the major implication of *ENG* and *ACVRL1* in the disease.

Beyond HHT molecular diagnosis, the identification of such balanced structural variants is important as they could get imbalanced during meiosis and generate much severe phenotypes, thus making genetic counselling much more complex, as it will deal both with a monogenic disorder known to the family, and an unexpected chromosomal problem. However, the probability of an unbalanced karyotype appearing in the next generation is minimal and due to the generation of dicentric and acentric fragments, which may be associated with fertility issues (Anton et al., 2005).

Genome sequencing was negative in two of the four families, but this does not necessarily mean there is no genetic etiology for the disorder. First, interpretation of variations located in non-coding regions is challenging. Besides, another genetic mechanism for the disorder could be involved. We can raise the possibility of mosaic mutations confined to affected tissues that are not detectable when examining DNA extracted from blood leukocytes. This may be the case in family A, Pt1, which has isolated lung involvement. For families with no defined diagnosis for any known genetic condition, other genes may be involved with different mechanisms that were not able to be selected as candidate genes at this stage. Finally, although bioinformatic pipelines have made progress in detecting SVs and CNVs, their sensitivity is not perfect and some CNVs may go undetected by currently used methods, also non-coding CNVs affecting regulatory regions could be involved.

In conclusion, this case report emphasizes the importance of in-depth genetic research in families with a definite diagnosis of HHT but no pathogenic variant in common causing genes found, investigating a wide range of genetic disease mechanisms to find the causal one.

Declaration of conflict of interest

The authors declare no conflict of interest.

CRedit authorship contribution statement

M. Tusseau: Formal analysis, Writing – original draft, Writing – review & editing. **M. Eyries:** Formal analysis. **N. Chatron:** Formal analysis. **F. Coulet:** Formal analysis, Supervision. **A. Guichet:** Formal analysis. **E. Colin:** Resources. **B. Demeer:** Resources. **H. Maillard:** Resources. **J. Thevenon:** Data curation. **C. Lavigne:** Resources. **V. Sailour:** Data curation. **C. Paris:** Data curation. **J.M. De Sainte Agathe:** Data curation. **M. Pujalte:** Formal analysis. **A. Guilhem:** Formal analysis. **S. Dupuis-Girod:** Supervision. **G. Lesca:** Formal analysis, Supervision.

Data availability

The data that has been used is confidential.

Acknowledgment

This research was made possible through access to the data generated by the France Genomic Medicine Plan 2025.

References

- Albiñana, V., Zafra, M.P., Colau, J., Zarrabeitia, R., Recio-Poveda, L., Olavarrieta, L., et al., 2017. Mutation affecting the proximal promoter of Endoglin as the origin of hereditary hemorrhagic telangiectasia type 1. *BMC Med. Genet.* 18 (1), 20.
- Anton, E., Blanco, J., Egozcue, J., Vidal, F., 2005. Sperm studies in heterozygote inversion carriers: a review. *Cytogenet. Genome Res.* 111 (3–4), 297–304.
- Balachandar, S., Graves, T.J., Shimonty, A., Kerr, K., Kilner, J., Xiao, S., et al., 2022. Identification and validation of a novel pathogenic variant in GDF2 (BMP9) responsible for hereditary hemorrhagic telangiectasia and pulmonary arteriovenous malformations. *Am. J. Med. Genet.* 188 (3), 959–964.
- Chen, X., Liu, Y., Sheng, X., Tam, P.O.S., Zhao, K., Chen, X., et al., 2014. PRPF4 mutations cause autosomal dominant retinitis pigmentosa. *Hum. Mol. Genet.* 23 (11), 2926–2939.
- Damjanovich, K., Langa, C., Blanco, F.J., McDonald, J., Botella, L.M., Bernabeu, C., et al., 2011. 5'UTR mutations of ENG cause hereditary hemorrhagic telangiectasia. *Orphanet J. Rare Dis.* 6, 85.
- Gallione, C.J., Repetto, G.M., Legius, E., Rustgi, A.K., Schelley, S.L., Tejpar, S., et al., 2004. A combined syndrome of juvenile polyposis and hereditary haemorrhagic telangiectasia associated with mutations in MADH4 (SMAD4). *Lancet* 363 (9412), 852–859.
- Lesca, G., Burnichon, N., Raux, G., Tosi, M., Pinson, S., Marion, M.J., et al., 2006. Distribution of ENG and ACVRL1 (ALK1) mutations in French HHT patients. *Hum. Mutat.* 27 (6), 598.
- Linder, B., Hirmer, A., Gal, A., Rütger, K., Bolz, H.J., Winkler, C., et al., 2014. Identification of a PRPF4 loss-of-function variant that abrogates U4/U6.U5 tri-snRNP integration and is associated with retinitis pigmentosa. *PLoS One* 9 (11), e111754.
- McDonald, J., Bayrak-Toydemir, P., DeMille, D., Wooderchak-Donahue, W., Whitehead, K., 2020. Curaçao diagnostic criteria for hereditary hemorrhagic telangiectasia is highly predictive of a pathogenic variant in ENG or ACVRL1 (HHT1 and HHT2). *Genet. Med. Off. J. Am. Coll. Med. Genet.* 22 (7), 1201–1205.
- Pagnamenta, A.T., Yu, J., Evans, J., Twiss, P., 2023. Conclusion of diagnostic odysseys due to inversions disrupting GLI3 and FBNI. *J. Med. Genet.* 60 (5), 505–510, 1.
- Ruiz-Llorente, L., McDonald, J., Wooderchak-Donahue, W., Briggs, E., Chesnutt, M., Bayrak-Toydemir, P., et al., 2019. Characterization of a family mutation in the 5' untranslated region of the endoglin gene causative of hereditary hemorrhagic telangiectasia. *J. Hum. Genet.* 64 (4), 333–339.
- Schnause, A.C., Komlosi, K., Herr, B., Neesen, J., Dremsek, P., Schwarz, T., et al., 2021. Marfan syndrome caused by disruption of the FBNI gene due to a reciprocal chromosome translocation. *Genes* 12 (11), 1836.
- Shovlin, C.L., Guttmacher, A.E., Buscarini, E., Faughnan, M.E., Hyland, R.H., Westermann, C.J.J., et al., 2000. Diagnostic criteria for hereditary hemorrhagic telangiectasia (Rendu-Osler-Weber syndrome). *Am. J. Med. Genet.* 91 (1), 66–67.
- Topiwala, K.K., Patel, S.D., Nouh, A.M., Alberts, M.J., 2020. Novel GDF2 gene mutation associated with pulmonary arteriovenous malformation. *J. Stroke Cerebrovasc. Dis. Off. J. Natl. Stroke Assoc.* 29 (12), 105301.
- Wooderchak-Donahue, W.L., McDonald, J., Farrell, A., Akay, G., Velinder, M., Johnson, P., et al., 2018. Genome sequencing reveals a deep intronic splicing ACVRL1 mutation hotspot in Hereditary Haemorrhagic Telangiectasia. *J. Med. Genet.* 55 (12), 824–830.