



HAL
open science

Ampullary tumors: French Intergroup Clinical Practice Guidelines for diagnosis, treatments and follow-up (TNCD, SNFGE, FFCD, UNICANCER, GERCOR, SFCD, SFED, ACHBT, AFC, SFRO, RENAPE, SNFCP, AFEF, SFP, SFR)

Vincent Hautefeuille, Nicolas Williet, Anthony Turpin, Bertrand Napoleon, Aurélien Dupré, Florence Huguet, Anne Laure Bignon, Marine Camus, Jean-Baptiste Chevaux, Romain Coriat, et al.

► **To cite this version:**

Vincent Hautefeuille, Nicolas Williet, Anthony Turpin, Bertrand Napoleon, Aurélien Dupré, et al.. Ampullary tumors: French Intergroup Clinical Practice Guidelines for diagnosis, treatments and follow-up (TNCD, SNFGE, FFCD, UNICANCER, GERCOR, SFCD, SFED, ACHBT, AFC, SFRO, RENAPE, SNFCP, AFEF, SFP, SFR). Digestive and Liver Disease, 2024, 56 (9), pp.1452-1460. 10.1016/j.dld.2024.04.027 . hal-04603000

HAL Id: hal-04603000

<https://u-picardie.hal.science/hal-04603000v1>

Submitted on 24 Sep 2024

HAL is a multi-disciplinary open access archive for the deposit and dissemination of scientific research documents, whether they are published or not. The documents may come from teaching and research institutions in France or abroad, or from public or private research centers.

L'archive ouverte pluridisciplinaire **HAL**, est destinée au dépôt et à la diffusion de documents scientifiques de niveau recherche, publiés ou non, émanant des établissements d'enseignement et de recherche français ou étrangers, des laboratoires publics ou privés.



Guidelines

Ampullary tumors: French Intergroup Clinical Practice Guidelines for diagnosis, treatments and follow-up (TNCD, SNFGE, FFCD, UNICANCER, GERCOR, SFCD, SFED, ACHBT, AFC, SFRO, RENAPE, SNFCP, AFEF, SFP, SFR)



Vincent Hautefeuille^{a,*}, Nicolas Williet^b, Anthony Turpin^c, Bertrand Napoleon^d, Aurélien Dupré^e, Florence Huguet^f, Anne Laure Bignon^g, Marine Camus^h, Jean-Baptiste Chevauxⁱ, Romain Coriat^j, Jérôme Cros^k, Julien Edeline^l, Stéphane Koch^m, Cindy Neuzilletⁿ, Géraldine Perkins^o, Jean Marc Regimbeau^p, David Sefrioui^q, Carole Vitellius^r, Marie-Pierre Vullierme^s, Olivier Bouché^t, Sébastien Gaujoux^{u,1}, on behalf of the Thésaurus National de Cancérologie Digestive (TNCD), Société Nationale Française de Gastroentérologie (SNFGE), Fédération Francophone de Cancérologie Digestive (FFCD), Fédération Nationale des Centres de Lutte Contre le Cancer (UNICANCER), Groupe Coopérateur multidisciplinaire en Oncologie (GERCOR), Société Française de Chirurgie Digestive (SFCD), Société Française d'Endoscopie Digestive (SFED), Association de Chirurgie Hépato-Bilio-Pancréatique et Transplantation (ACHBT), Société Française de Pathologie (SFP), Société Française de Radiothérapie Oncologique (SFRO), Réseau National de Référence des Tumeurs Rares du Péritoine (RENAPE), Société Nationale Française de Colo-Proctologie (SNFCP), Association Française pour l'Étude du Foie (AFEF), Société Française de Radiologie (SFR)

^a Department of Gastroenterology and Digestive Oncology, Amiens University Hospital – Amiens, France

^b Department of Hepato-gastroenterology and Gastrointestinal Oncology, University Institute of Cancerology and Hematology of Saint-Etienne (ICHUSE)

^c Department of Oncology, Lille University Hospital; CNRS UMR9020, INSERM UMR1277, University of Lille, Institut Pasteur, Lille, France

^d Department of Digestive Endoscopy, Jean Mermoz Hospital, Ramsay Sante, Lyon, France

^e Department of Surgical Oncology, Centre Léon Bérard – Lyon, France

^f Department of Radiation Oncology, Tenon Hospital, AP-HP, Sorbonne University, Paris, France

^g Department of Gastroenterology and Digestive Oncology, Caen University Hospital – Caen, France

^h Sorbonne University CRSA & APHP Saint Antoine Hospital, Endoscopy Center, 184 rue du Faubourg St Antoine, 75012 Paris, France

ⁱ Department of Gastroenterology, Brabois University Hospital, Nancy, France

^j Gastroenterology and digestive oncology Unit, Hôpital Cochin, GH APHP Centre, université Paris Cité, Paris, France

^k Université Paris Cité, Department of Pathology, Beaujon/Bichat University Hospital (APHP), Clichy/Paris, France

^l INSERM, Univ Rennes, Department of Medical Oncology, CLCC Eugène Marquis, COSS (Chemistry Oncogenesis Stress Signaling) – UMR_S 1242, Rennes, France

^m Endoscopy and Gastroenterology Unit, Besançon University Hospital, Besançon, France

ⁿ GI Oncology, Department of Medical Oncology, Institut Curie, Versailles Saint-Quentin University – Paris Saclay University, Saint Cloud, France

^o Department of Gastroenterology, Pontchaillou University Hospital, Rennes, France

^p Department of Digestive Surgery, Amiens University Hospital – Amiens, France

^q Normandie University, UNIROUEN, Inserm U1245, IRON group, Department of Hepatogastroenterology, Rouen University Hospital, Rouen, France

^r Department of Gastroenterology and Digestive Oncology, Angers University Hospital – Angers, France

^s Department of Medical Imaging, Université Paris-Cité, Annecy Genevois Hospital (CHANGE), Annecy, France

^t Department of Gastroenterology and Digestive Oncology, CHU Reims, Reims, France

^u Department of HPB and Endocrine surgery; Pitié Salpêtrière Hospital; Paris, France

* Corresponding author: Department of Gastroenterology and Digestive Oncology, Amiens University Hospital, 80054, Amiens, France.
E-mail address: hautefeuille.vincent@chu-amiens.fr (V. Hautefeuille).

¹ Equally contributed.

ARTICLE INFO

Article history:

Received 19 February 2024

Accepted 24 April 2024

Available online 6 June 2024

Keywords:

Ampullary tumors

Chemotherapy

Endoscopy

French intergroup clinical practice guidelines

Prognosis

Surgery

ABSTRACT

Background: Management of ampullary tumors (AT) is challenging because of a low level of scientific evidence. This document is a summary of the French intergroup guidelines regarding the management of AT, either adenoma (AA) or carcinoma (AC), published in July 2023, available on the website of the French Society of Gastroenterology (SNFGE) (www.tncd.org).

Methods: A collaborative work was conducted under the auspices of French medical, endoscopic, oncological and surgical societies involved in the management of AT. Recommendations are based on recent literature review and expert opinions and graded in three categories (A, B, C), according to quality of evidence.

Results: Accurate diagnosis of AT requires at least duodenoscopy and EUS. All patients should be discussed in multidisciplinary tumor board before treatment. Surveillance may only be proposed for small AA in familial adenomatous polyposis. For AA, endoscopic papillectomy is the preferred option only if R0 resection can be achieved. When not possible, surgical papillectomy should be considered. For AC beyond pT1a N0, pancreaticoduodenectomy is the procedure of choice. Adjuvant monochemotherapy (gemcitabine, 5FU) may be proposed. For aggressive tumors (pT3/T4, pN+, R1, poorly differentiated AC, pancreatobiliary differentiation) with high risk of recurrence, 6 months polychemotherapy (CAPOX/FOLFOX for the intestinal subtype and mFOLFIRINOX for the pancreatobiliary or the mixed subtype) may be a valid alternative. Clinical and radiological follow up is recommended for 5 years.

Conclusions: These guidelines help to homogenize and highlight unmet needs in the management of AA and AC. Each individual case should be discussed by a multidisciplinary team.

© 2024 The Author(s). Published by Elsevier Ltd on behalf of Editrice Gastroenterologica Italiana S.r.l. This is an open access article under the CC BY license (<http://creativecommons.org/licenses/by/4.0/>)

1. Introduction

This present article summarizes the French intergroup guidelines published in July 2023 on the French Gastroenterology Society SNFGE website (www.tncd.org) [1]. These guidelines are a collaborative work written by a multidisciplinary committee originating from several societies involved in the management of ampullary tumor (AT) patients (SNFGE, FFCD, UNICANCER, GERCOR, SFCD, SFED, ACHBT, AFC, SFRO, RENAPE, SNFCP, AFEF, SFP, SFR), i.e. gastroenterologists, gastrointestinal endoscopists, digestive surgeons, oncologists, radiation oncologists, radiologists and pathologists involved in the management of AT. The initial document was reviewed and modified after further evaluation by a review committee, and the last version received final validation from the steering committee of the *Thésaurus National de Cancérologie Digestive* (TNCD). These guidelines are an up-to-date comprehensive overview of definition, pre-therapeutic examinations, endoscopic management, surgical strategies, an overview of adjuvant chemotherapy according to tumors' characteristics and proposition for management of advanced ampullary cancers and molecular testing. Recommendations were graded in 3 categories (grades A, B, and C) according to the level of evidence. Expert opinion (agreement or not, grade D) was noted when no/poor scientific evidence was available [Table 1].

2. General considerations

2.1. Definition

The frequently used term “ampulloma” is not accurate enough as it encompasses different histological entities from GISTs to neuroendocrine tumors, adenomas and invasive carcinomas. The present guideline will focus on epithelial lesions (adenomas/adenocarcinomas). As in the NCCN guidelines, it has to be replaced by “ampullary adenoma” (AA) and “ampullary carcinoma” (AC) terminology to avoid confusion [2]. Staging system for these guidelines will be the 8th AJCC classification published in 2017 [3].

2.2. Epidemiology and associated disease

AT are rare (0.06 % to 0.2 % in autopsy series). According to the SEER database, annual incidence is 0.59 per 100,000 inhabi-

tants per year, with a slight increase over time (+0.9 % per year). It mainly occurs after 50 years (median age at diagnosis: 71 years), with a male predominance.

Familial adenomatous polyposis (FAP) is the most common genetic disease associated with AT, often associated with duodenal polyposis. Duodenal cancer is the second leading cause of death of FAP patients. Duodenal assessment in FAP may start around 12–15 years. Contrary to sporadic AA, FAP AA are mostly benign and AA under 1 cm may be monitored. Above 1 cm, AA should be endoscopically removed (AC occurring in lesion > 1 cm in the study by Latchford et al.) [4], unless duodenal involvement warrants a pancreatoduodenectomy. To help decision making and follow-up, clinicians should use the Spigelman classification [5] and consider surgery if duodenal involvement is not manageable with endoscopic treatment.

Very few data are available for other genetic syndromes. In Lynch syndrome, a series by Hammoudi et al. evaluating duodenal cancer risk in 154 Lynch patients found only one ampullary lesion [6], in line with the low prevalence of MSI high / deficient mismatch repair (dMMR) in these cancers. Data are even scarcer for other genetic syndromes involving the duodenal region, such as MUTYH-associated polyposis. In an international prospective cohort by Thomas et al., reported rate of AT was 1.8 % [7].

2.3. Histological and molecular characteristics

The ampulla of Vater is a complex anatomical site, involving 3 different epithelia: the duodenal mucosa, the pancreatic duct and the biliary tract epithelia, and lesions ranging from dysplasia to invasive cancer. This explains why the diagnosis and determination of the phenotype of AT may be challenging for pathologists. Clinical and morphological evaluation is crucial, to avoid overdiagnosis of AA or underdiagnosis of AC. Indeed, endoscopic biopsies may show a dystrophic aspect of the mucosa that may be confused with dysplasia. In two retrospective cohorts, 13–15 % of endoscopically resected ampullas did not show either adenoma or adenocarcinoma. In case of suspected gallstone migration, the ampulla may appear inflammatory or pseudotumoral, and a second look may be useful 6 to 12 weeks later to confirm the diagnosis.

The eighth version of the AJCC classification published in 2017 defines pT1a AC (carcinoma limited to the mucosa) and pT1b AC

Table 1
Grade of recommendations according to the GRADE system.

Grade	Quality of evidence	Definition
A	High	Strongly recommended based on highly robust scientific evidence (e.g. several randomized controlled trials/meta-analysis). Further research is very unlikely to change our confidence in the estimate of effect
B	Moderate	Usually recommended based on scientific presumption (e.g. one randomized controlled trial). Further research is likely to have an important impact on our confidence in the estimate of effect and may change the estimate
C	Low	Option based on weak scientific evidence (e.g. one or several non-randomized trials). Further research is very likely to have an important impact on our confidence in the estimate of effect and is likely to change the estimate
D	Very low	Expert opinion (agreement or not). Any estimate of effect is very uncertain

Table 2
TNM and Stage classification for Ampullary Carcinoma according to the AJCC 8th version (2017).

1a – TNM classification			
T	Primary tumor		
Tx	Primary tumor cannot be assessed		
T0	No evidence of primary tumor		
Tis	Carcinoma in situ		
T1	Tumor limited to Ampulla of Vater of sphincter of Oddi or tumor invades beyond the sphincter of Oddi (perisphincteric invasion) or into the duodenal submucosa		
	<ul style="list-style-type: none"> • T1a: tumor limited to Ampulla of Vater or sphincter of Oddi • T1b: tumor invades beyond the sphincter of Oddi (perisphincteric invasion) or into the duodenal submucosa 		
T2	Tumor invades into the muscularis propria of the duodenum		
T3	Tumor directly invades into the pancreas (up to 0.5 cm) or tumor extends more than 0.5 cm into the pancreas or extends into peripancreatic or periduodenal tissue or duodenal serosa without involvement of the celiac axis or superior mesenteric artery		
	<ul style="list-style-type: none"> • T3a: tumor directly invades the pancreas (up to 0.5 cm) • T3b: tumor extends more than 0.5 cm into the pancreas or extends into peripancreatic tissue or periduodenal tissue or duodenal serosa without involvement of the celiac axis or superior mesenteric artery 		
T4	Tumor involves the celiac axis, superior mesenteric artery or common hepatic artery, irrespective of size		
N	Regional lymph nodes		
Nx	Regional lymph nodes cannot be assessed (No regional lymph node metastasis and number < 12 lymph node analyzed)		
N0	No regional lymph node involvement		
N1	Metastasis to one to three regional lymph nodes		
N2	Metastasis to four or more regional lymph nodes		
M	Distant metastasis		
M0	No distant metastasis		
M1	Distant metastasis		
1b – Stage classification			
Stage	T	N	M
0	Tis	N0	M0
IA	T1a	N0	M0
IB	T1b-T2	N0	M0
IIA	T3a	N0	M0
IIB	T3b	N0	M0
IIIA	T1a-T1b-T2-T3	N1	M0
IIIB	any T	N2	M0
	T4	any N	M0
IV	any T	any N	M1

(involvement of the submucosa), which is a major threshold for lymph node risk assessment [3]. This classification, detailed in Table 2, should be preferred over the previous ones.

Determination of intestinal (INT), pancreatobiliary (PB) or mixed type (MT) subtypes may be helpful to assess prognosis and risk of recurrence, as INT subtype shows more favorable outcome compared to PB and MT subtype [8]. It may help clinicians for the choice of adjuvant chemotherapy. Distinction between histological subtypes is difficult in approximately 1/4 of AC [9]). PB subtype seems to be the most frequent (45–60 %), INT and MT accounting for 30–40 % and 10–20 % of AC respectively [10,11]. In order to better characterize AC subtypes, immunostaining for CDX2, MUC1 and MUC2, CK20 may help [9], even if their true clinical impact is uncertain [12]. Though its utility is not properly demonstrated in a prospective randomized trial, the determination of histological subtype is also recommended by the NCCN [2].

Determination of mismatch repair (MMR) protein expression by immunohistochemistry (grade C) may be of interest but is not mandatory, as a dMMR tumor may suggest the presence of a Lynch syndrome. A dMMR status is found in 2–18 % of AC, more frequently in the INT subtype [11,13,14]. In dMMR AC, immune checkpoint inhibitors (ICI) may therefore be considered for the treatment of advanced AC, after confirmation by a molecular technique of MSI testing (MSI-high AC).

2.4. Recommendation for pathological report

For AA, the factors influencing management are: familial history of FAP, the size of AA, the possible RO resection by either endoscopic or surgical papillectomy.

Recommendation: endoscopy and pathology report should therefore precise:

- The size of the adenoma
- Involvement of the duodenum by other polyps or lateral spreading on the duodenum
- The R0/R1 resection margin (both lateral and profound resection margin)
- The grade of dysplasia

For AC, the main prognostic factors are: involvement of the submucosa (AC pT1a vs AC \geq pT1b), lymph node involvement, risk factors of poor prognosis detailed below.

Recommendation: Imaging and pathology report should therefore be precise (grade A):

- TNM classification according to AJCC 2017 (8th edition)
- R0/R1 resection margin
- Differentiation of the AC
- Pathological subtype: intestinal (INT), pancreatobiliary (PB), mixed (MT) or undetermined (UN) morphology
- Lymphovascular or perineural involvement, tumor budding
- Immunohistochemistry: CDX2, CK20, MUC1 in case of difficult determination of INT / PB / MT phenotype

Option:

- MSI status: immunohistochemistry for MMR proteins (grade C)
- Molecular screening may be performed for advanced AC: immunohistochemistry for Her2, next generation sequencing for usual digestive cancers panel (expert agreement)

3. Diagnosis and pre-therapeutic explorations

3.1. Tumor markers

CEA and CA19.9 serum dosage are not recommended in AA (expert agreement). For AC, both markers can be useful for their prognostic value [15], for treatment efficacy monitoring, and to detect residual disease after surgery or relapse during the follow-up period (grade C).

Recommendation:

- No recommendation

Option:

- For AA, no dosage of tumor markers (expert agreement)
- For AC, CEA and CA19.9 serum dosage (after biliary drainage) may be useful for treatment monitoring and to detect residual disease or relapse (grade C)

3.2. Initial endoscopy

Initial endoscopic assessment includes esophagogastroduodenoscopy to visualize any associated duodenal involvement of the AT or other duodenal polyps, side-view duodenoscopy to visualize the major papilla and minor papilla. If necessary, a transparent cap is useful. Biopsies of an AT is recommended, and the medical history has to be taken into account, i.e. history of lithiasis or pancreatitis, as the risk of a suspected AA with false positive biopsies is significant. If any doubt, control esophagogastroduodenoscopy is recommended 6 to 12 weeks later. Management and major or minor papilla should follow the same guidelines (expert agreement).

Initial endoscopic ultrasound (EUS) diagnosis (with water instillation in the duodenal lumen to facilitate evaluation) to assess tumor stage is required. In case of jaundice due to ampullary tumor and early stage tumor, EUS may allow upfront endoscopic papillectomy rather than stent placement and further papillectomy. In the literature, EUS has a good diagnostic accuracy: sensitivity of 77 % and specificity of 78 % for usT staging; sensitivity of 70 % and

specificity of 74 % for the usN staging [16], but accuracy may be lower in real life.

Endoscopic retrograde cholangiopancreatography (ERCP) may help to determine the extent of the tumor in the bile duct and identifies diffuse involvement of the common bile duct, when EUS is uncertain. For sphincterotomy or biliary stenting, the role of ERCP in the diagnosis of an AT is classical and meets those of pancreatobiliary cancers (cholangitis, total bilirubin $>$ 200 μ M, time to surgery $>$ 3 months, palliative AT or indication of prior chemotherapy for borderline or locally advanced AC). In the case of cholangitis on AA, a plastic biliary stent without sphincterotomy is preferable so as not to interfere with the monobloc endoscopic resection which will be planned at a later stage.

Because of possible association of AT with colorectal lesions, colonoscopy was previously recommended in the initial assessment of AT, but there are conflicting results from retrospective studies. Some studies show no systematic benefit from colonoscopy [17,18], while others suggest a difference in the frequency of colonic polyps between patients with AT versus the general population [19]. Colonoscopy may be indicated in certain cases, such as associated duodenal adenomas, age \geq 50 years, history of family polyps or digestive cancers, MSI/dMMR tumors, and the presence of usual digestive alarm signs.

3.3. Morphological and nuclear medicine imaging

For AA, endoscopic evaluation is sufficient and no further morphological evaluation is needed. MRI can be useful to better assess ductal anatomy before papillectomy. For AC, contrast enhanced thoraco-abdominopelvic CT-scan at baseline is mandatory before considering surgery, duodenal water contrast might be useful for a better visualization of the lesion. As for pancreatic cancer, liver MRI with gadolinium-enhanced and diffusion-weighted sequences before surgery of an AC is recommended to discard liver metastasis. Systematic 18 Fluorodeoxyglucose (FDG)-PET is not recommended but is useful to characterize suspect lesions of other organs or when distant metastatic lymph nodes are suspected (expert agreement).

3.4. Recommendation for the initial diagnosis of AT

Recommendation (expert agreement):

- Esophagogastroduodenoscopy +/- duodenoscopy with biopsies for diagnosis and to assess size and duodenal involvement of AT
- EUS to determine pancreatic and bile duct involvement for AT, and to determine usT and usN staging for localized AC
- For AA:
 - CT-scan and MRI imaging are not recommended
- For AC:
 - Contrast enhanced thoraco-abdominopelvic CT-scan at diagnosis
 - Liver MRI before surgery to rule out liver metastases
 - MRI or 18 FDG-PET is not recommended in case of obvious metastases

Option (expert opinion):

- Colonoscopy to rule out colorectal polyps in case of:
 - Familial history of polyps or FAP or Lynch syndrome
 - Duodenal adenomas
 - dMMR/MSI-high AT or AC
 - Usual worrisome signs of colorectal disease
- 18 FDG-PET:
 - If case of suspected metastases with unclear CT-scan or MRI

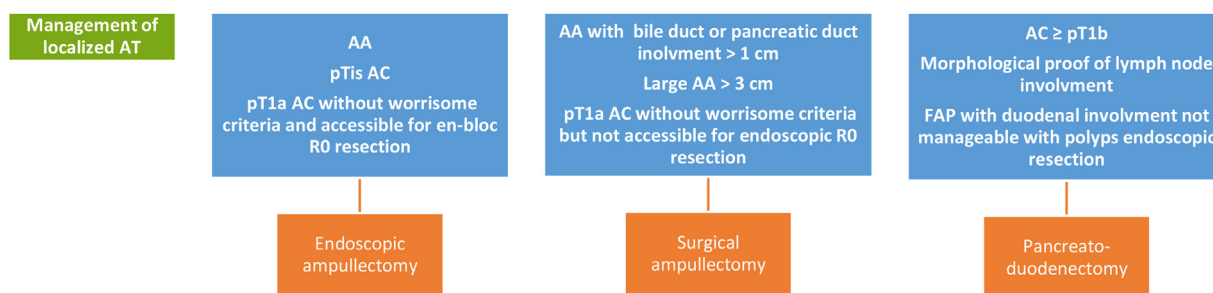


Fig. 1. Management of localized AT. AT: ampullary tumor. AA: ampullary adenoma. AC: ampullary carcinoma.

4. Management of AA and localized AC

4.1. Rationale for endoscopic or surgical treatment

Management of AA and localized AC are summarized in Fig. 1. Recommendations for en-bloc R0 endoscopic removal of AA are in line with the ESGE consensus [20], low grade and high grade dysplastic AA under 3 cm being the optimal situation for endoscopy, with high rate (above 80–90 %) of success in recent series [21–23], and is considered curative when R0 resection of the AA is achieved [24]. It might also be sufficient for pTis AC and for pT1a AC not suitable for surgery, the latter having a very low risk of lymph node metastasis when harboring no other risk factors (well differentiated, R0 resection, no lymphovascular involvement or tumor budding). Endoscopic re-resection or more frequently surgical resection is needed if initial resection is not R0.

For AA with a contraindication for endoscopic papillectomy (i.e. duodenal diverticulum, major duodenal involvement, AA > 3 cm) or after a R1 resection, surgical papillectomy may be considered. Best indications for surgical papillectomy are AA > 3 cm, AA with contraindication for endoscopic removal, AA with initial risk of a R1 resection, relapse after endoscopic papillectomy not manageable with endoscopic re-resection). For patients with AA and R1 endoscopic resection not fit enough for salvage surgery, endobiliary radiofrequency ablation for eradication of residual adenoma after endoscopic papillectomy may be a reasonable option as suggested by a prospective study [25].

Over pT1a AC or AC with histological worrisome features (poor differentiation, lymphovascular involvement, high budding tumor) or in case of R1 resection not manageable with surgical papillectomy or lymph node involvement after the initial evaluation (EUS, CT-scan or MRI), pancreatoduodenectomy is mandatory for fit patients.

Finally, pancreatoduodenectomy is the reference surgery for FAP patients with AA > 1 cm and “Spigelman high” duodenal involvement.

4.2. Recommended management for AA and localized AC

Recommendation (expert agreement):

- Surveillance
 - AA < 1 cm with low grade dysplasia in FAP patients
- Endoscopic papillectomy
 - AA without biliary tract or pancreatic involvement
 - AA with biliary tract or pancreatic involvement < 1 cm and R0 resection
 - AA > 1 cm or high grade dysplasia for FAP patients with a manageable endoscopic duodenal involvement
 - pTis and R0 AC
- Surgical papillectomy
 - Technical contraindication for endoscopic en-bloc resection of AA:

- AA > 3 cm
- or presence of a duodenal diverticulum
- or AA with a major duodenal spread
- AA with an endoscopically non resectable biliary tract or pancreatic duct involvement
- AA with R1 endoscopic resection
- Local relapse of an endoscopically resected AA not manageable with endoscopic re-resection
- Pancreaticoduodenectomy (Whipple procedure)
 - pT1b or higher stage AC
 - pT1a AC with worrisome features:
 - with suspected lymph node involvement (EUS, CTscan, MRI)
 - or with R1 resection
 - or with risk factors for lymph node involvement or metastasis: poor differentiation, lymphovascular involvement, high tumor budding
 - AA in FAP patients with an endoscopically non manageable duodenal involvement (Spigelman stage IV)

Option (expert opinion):

- Endobiliary radiofrequency ablation for eradication of residual AA after endoscopic papillectomy in patients not fit for surgery (grade C)
- Papillectomy:
 - When evaluation of the nature of the ampullary tumor or the T stage is unclear (macrobiopsy) to better determine further treatment (need for surgery, type of surgery)
 - pT1a AC and R0 resection (either endoscopic or surgical) without worrisome features and no fit enough for pancreaticoduodenectomy

5. Adjuvant chemotherapy (AC)

5.1. Rationale for adjuvant chemotherapy

There is limited data demonstrating utility of adjuvant chemotherapy in resected AC. In pancreatic and biliary tract cancers, adjuvant chemotherapy is recommended regardless of the stage. Conversely, adjuvant chemotherapy is recommended in colorectal cancers regarding stage of each cancer [26]. As AC seem to have a high rate of recurrence and a rather poor prognosis, it is reasonable to consider adjuvant chemotherapy.

There are only two randomized studies that explore adjuvant chemotherapy in AC. However, they both include AT and periampullary carcinoma, making interpretation of the results difficult. In the ESPAC-3 phase III trial, gemcitabine showed significant improvement of overall survival (OS) versus observation whereas 5FU did not [27]. In the ASCOT trial that included Asian patients, subgroup analysis of 73 AC found a non-significant trend for OS in favor of the S-1 arm versus surveillance [28]. Overall, these two

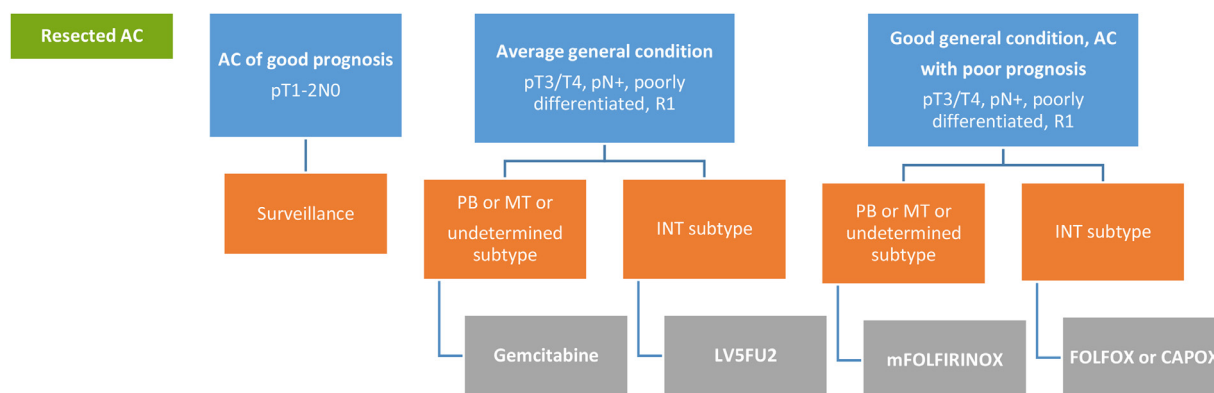


Fig. 2. Indication for adjuvant chemotherapy for resected AC. AC: ampullary carcinoma. PB: pancreatobiliary subtype. INT: intestinal subtype. MT: mixed subtype.

studies support the use of adjuvant monotherapy, but as a weak standard of treatment.

Prognosis of early stage of AC (i.e. pT1-T2 N0 AC) is excellent, with 5-year OS around 80 % and benefit of adjuvant chemotherapy in this subgroup is unclear [29,30]. Several retrospective data support the use of adjuvant chemotherapy in the high-risk group of AC. Bias are numerous in these studies and details of administered chemotherapy regimen are often not available. However, it seems to be a trend in favor of adjuvant chemotherapy for high-risk AC. In the study by Nassour et al., there was a benefit for OS for pT3/T4 AC, pN+ AC and poorly differentiated AC [31]. In the 2 studies by Moekotte et al. [32,33], benefit was significant for high-risk AC only with similar risk factors (tumor differentiation, R0/R1 status, T and N status), the age status being more controversial for the evaluation of recurrence. Finally, a same trend was observed in the French AGE0 cohort by Colussi et al., showing some benefit of adjuvant chemotherapy for high-risk AC (age \geq 75 years, stage, performance status and differentiation) [34]. Randomized clinical trials to demonstrate the utility of adjuvant chemotherapy is a high unmet need for patients with a resected AC.

5.2. Recommendation for adjuvant chemotherapy of AC

The recommendation of a specific regimen (Fig. 2) is difficult, due to the limitations of the literature. Adjuvant chemotherapy should be discussed with the patient as the level of evidence is low.

Recommendation:

- Adjuvant chemotherapy should be administered to fit patients, with a high risk of recurrence (pT3/T4 or pN+ or poor differentiation or R1 AC) and with a strict management of toxicities (expert agreement).
- Adjuvant monotherapy for 6 months (gemcitabine or simplified LV5FU2 or capecitabine) has the highest level of evidence (grade B) and is therefore the standard treatment for adjuvant chemotherapy.
- The choice of the chemotherapy regimen may be guided by histological subtype (expert opinion):
 - gemcitabine for PB or MT subtype
 - 5FU or capecitabine for INT subtype

Option:

- pT1-T2 N0 AC:
 - Although based on limited evidence, simple surveillance without adjuvant chemotherapy is recommended for low risk (pT1-T2 N0) AC (grade C).

- Given retrospective published data, a 6-month poly-chemotherapy is a possible option in high risk resected AC (expert opinion, no agreement):

- As the prognosis of INT subtype is better, FOLFOX or CAPOX is preferred for INT subtype
- mFOLFIRINOX (irinotecan 150 mg/m²) is preferred for PB and MT subtype.

5.3. Adjuvant radiotherapy

Role of adjuvant chemoradiation in AC has not been properly demonstrated. In two randomized controlled phase III studies that included pancreatic cancers, periampullary cancers and AC [35,36], chemoradiotherapy failed to improve overall survival. These results are in line with retrospective data from the SEER database [37].

Recommendation:

- Chemoradiation is not recommended for adjuvant treatment of resected AC (grade C).

6. Surveillance after initial management

6.1. Endoscopic follow up of resected AA

The recurrence rate after endoscopic resection of ampullary adenomas is 12 %, with a median time to recurrence of 14 months [38,39]. Surveillance should take into account any genetic predisposing conditions.

Endoscopic surveillance is recommended, ideally with a high definition duodenoscopy and biopsies of the scar and any endoscopic abnormalities. Chromoendoscopy with methylene blue may improve detection. The ESGE guidelines propose an initial control endoscopy at 3 months to allow early assessment and removal of any pancreatic stent. Subsequent surveillance is recommended 6 and 12 months later, then annually for 5 years after resection (expert opinion).

Endoscopic ultrasound has not shown any benefit for surveillance [21]. CT scan is also not recommended for resected AA [40].

Recommendation

- No recommendation

Option (expert agreement):

- Duodenoscopy with biopsy of the scar and suspect lesions
- Initial control endoscopy at 3 months, then 6 and 12 months later, then annually for 5 years after resection (expert opinion)

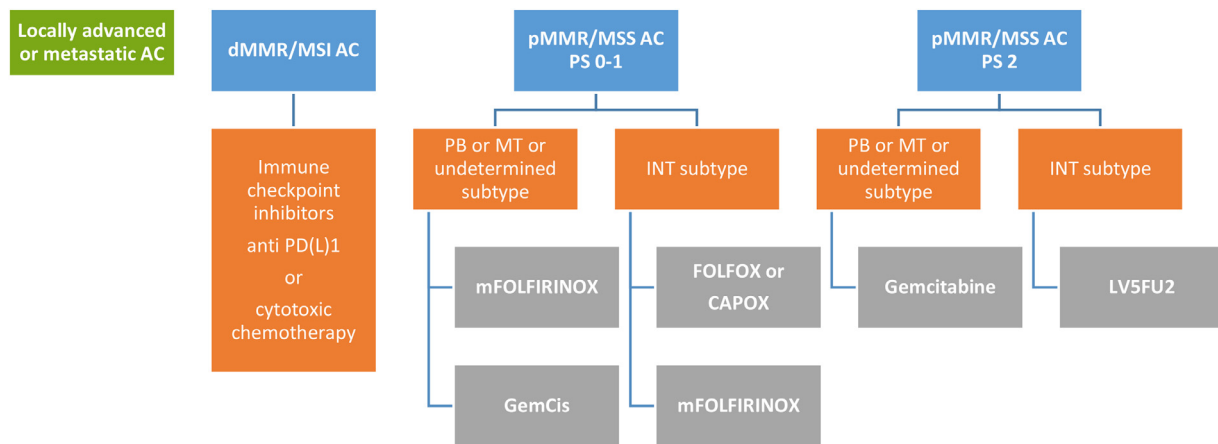


Fig. 3. First line chemotherapy of advanced and metastatic AC. AC: ampullary carcinoma. PB: pancreatobiliary subtype. INT: intestinal subtype. MT: mixed subtype.

6.2. Follow up of operated AC

As for colorectal cancer where CEA surveillance during follow-up does not improve survival [41], systematic dosage of CEA or CA19.9 for operated AC is not recommended. It may be useful in case of appearance of new symptoms or if assessment of recurrence by morphological imaging (CT-scan or MRI) is doubtful.

Contrast enhanced CT scan is recommended every 6 months for 5 years (expert agreement) to detect recurrence and to discuss palliative chemotherapy. Abdominal ultrasonography may be sufficient for follow-up, as relapse is usually not curable. Of note, benefit of this active surveillance has not properly been evaluated.

Recommendation:

- No recommendation

Option:

- Contrast enhanced CT scan every 6 months for 5 years (expert agreement)

7. Management of locally advanced and metastatic AC

7.1. Biliary drainage

The indications for biliary drainage are the same as for pancreatobiliary tumors: symptomatic cholestasis (pruritus, jaundice, cholangitis), before palliative chemotherapy and if life expectancy > 3 months.

7.2. First-line chemotherapy

Very few prospective data (all non-randomized and with small sample size) are published to draw solid conclusions for choosing first line chemotherapy regimen. The only available phase II trial studied first-line CAPOX regimen (capecitabine 750 mg/m²/12h D1-D14 and oxaliplatin 130 mg/m² on D1, D21=D1) in 25 metastatic patients (but only 12 were AC, the other patients being small intestine carcinoma). The objective response rate was 50 %, median progression-free survival was 9.4 months, and median OS was 15.5 months [42].

By analogy with pancreatic cancers [43], FOLFIRINOX could constitute a valid option to treat advanced and metastatic AC as well as gemcitabine [44]; the gemcitabine plus cisplatin combination [45] showed similar efficacy compared with FOLFIRINOX in biliary tract carcinoma [46], with manageable toxicity. For dMMR/MSI-high AC, more common in the INT subtype of AC, ICI might be

the preferred first line treatment [47,48] as for treatment of dMMR metastatic colorectal carcinomas [49], though no randomized study support this proposition. Finally, there is insufficient data for the use of bevacizumab or antiEGFR therapy to recommend their use as an option. Proposition for first-line palliative chemotherapy are summarized in Fig. 3.

Recommendation:

- No recommendation

Option:

- For dMMR AC, ICI may be the preferred option (grade C). Cytotoxic chemotherapy (the same as for pMMR AC) is the best other option (expert opinion).
- For pMMR AC, first line chemotherapy may be adapted according to general condition, and INT / PB / MT subtype:
 - For INT subtype:
 - CAPOX (grade C)
 - mFOLFOX6 (expert opinion)
 - FOLFIRINOX without bolus (expert opinion)
 - FOLFIRI (expert opinion) if contraindication for oxaliplatin
 - 5FU (expert opinion) if contraindication for oxaliplatin
 - For PB or MT subtype:
 - modified FOLFIRINOX without bolus (expert opinion)
 - Gemcitabine based chemotherapy: gemcitabine +/- cisplatin (expert opinion)
 - For patients with ECOG PS > 2: best supportive care

7.3. Chemotherapy beyond first line

There is no sufficient data to suggest a second line regimen, in the absence of prospective studies. Pragmatically, it should be reserved for patients in good general condition given the lack of demonstrated clinical benefit. The regimens used can be based on 5FU, irinotecan, gemcitabine or even taxanes, taking into account the treatments previously received in first-line. A molecular screening may be performed (immunohistochemistry for Her2, Next Generation Sequencing for usual digestive cancers panel). However, druggable molecular alterations are rare (around 10–15 % of Her2 positive AC, < 5 % of FGFR alterations, < 15 % BRCA alterations, very few BRAF V600E and KRAS G12C mutations [11]).

Recommendation:

- No recommendation

Option:

- For dMMR/MSI-H AC: when not used in first line, ICI is a valid option (grade C)
- For Her2 positive AC: FOLFOX or 5FU and antiHer2 therapy (expert agreement)
- For FGFR2 translocation: FGFR2 inhibitors (expert agreement)
- For AC harboring NTRK fusions: larotrectinib or entrectinib (expert agreement)
- For other AC:
 - Mono or polychemotherapy depending on first line treatment:
 - Irinotecan based: FOLFIRI (expert opinion)
 - Gemcitabine based (expert opinion)
 - Taxane based (expert opinion) if contraindication for oxaliplatin
 - Best supportive care

Conflict of interest

VH: AAA, Amgen, Esteve, Ipsen, Deciphera, Merck, Pierre Fabre, Servier

AT: personal fees from Servier, Viartis, Incyte Bioscience, BMS, Merck and grants from AstraZeneca and MSD outside the submitted work

MC: Medtronic, Boston Scientific, Cook Medical, AMBU

CN: Honoraria / consulting: Amgen, AstraZeneca, Baxter, Bristol-Myers Squibb, Fresenius Kabi, Incyte Biosciences, Merck, MSD, Mundipharma, Novartis, Nutricia, OSE Immunotherapeutics, Pierre Fabre, Roche, Sanofi, Servier, Viartis. Research funding / clinical trials: AstraZeneca, Bristol-Myers Squibb, Fresenius Kabi, Nutricia, OSE Immunotherapeutics, Roche, Servier, Viartis.

ALB declares consulting for AstraZeneca, Servier, Ipsen and accommodations or congress registration support for Merck and Ipsen

DS: Honoraria / consulting: Amgen, Bayer, Deciphera Pharmaceutical, Ipsen, Pierre Fabre, Roche, Servier, Viartis, Travel accommodations: AstraZeneca, Ipsen, Novartis, Pfizer, Pierre Fabre, Roche, Sanofi, Servier

GP: honoraria from Servier, Roche and Sanofi

OB: honoraria from Amgen, Apmonia Therapeutics, Bayer, Deciphera, Merck KGaA, MSD, Pierre Fabre, Servier.

SG: Mylan, IPSEN

All other authors declare no conflict of interest related to this article.

Financial disclosure

These recommendations did not benefit from any financial support.

Acknowledgments

We thank the review committee: Thomas APARICIO (Paris), Thierry CONROY (Nancy), Thierry LECOMTE (Tours), Marie MULLER (Nancy), Alain SAUVANET (Paris), Benoit TERRIS (Paris), Thomas WALTER (Lyon), Jean-Baptiste BACHET (Paris), Stéphanie TRUANT (Lille), Bachir ELIAS (Le Creusot), Bogdan BADIC (Brest), Louise BARBIER (Clichy), Julien CAHAIS (Rouen), Pierre-Emmanuel HENNERESSE (Flers), Radwan KASSIR (Saint Denis), Dine KORICHE (Fontainebleau), Sophie NAMBOT (Dijon), Stéphanie TRUANT (Lille).

References

- [1] Hautefeuille V, Gaujoux S, Bignon AL, et al. Tumeurs de l'ampoule Thésaurus national de cancérologie digestive; 2023. online [<https://www.snfge.org/content/19-tumeurs-de-lampoule-de-vater>].
- [2] Chiorean E, Del Chiaro M, Tempero M, et al. Ampullary adenocarcinoma, version 1.2023, NCCN clinical practice guidelines in oncology. *J Natl Compr Canc Netw* 2023;21:753–82.
- [3] Kim SJ, An S, Kang HJ, et al. Validation of the eighth edition of the American Joint Committee on Cancer staging system for ampulla of Vater cancer. *Surgery* 2018;163:1071–9.
- [4] Latchford A, Neale K, Spigelman A, et al. Features of duodenal cancer in patients with familial adenomatous polyposis. *Clin Gastroenterol Hepatol* 2009;7:659–63.
- [5] Syngal S, Brand J, Giardiello, et al. ACG clinical guideline: genetic testing and management of hereditary gastrointestinal cancer syndromes. *Am J Gastroenterol* 2015;110:223–62.
- [6] Hammoudi N, Dhooge M, Coriat R, et al. Duodenal tumor risk in Lynch syndrome. *Dig Liver Dis* 2019;51:299–303.
- [7] Thomas L, Hurler J, Alonso Sanchez A, et al. Duodenal adenomas and cancer in MUTYH-associated polyposis: an international cohort study. *Gastroenterology* 2021;160:952–4.e4.
- [8] Shin DW, Kim S, Jung JH, et al. Impact of histopathological type on the prognosis of ampullary carcinoma: a systematic review and meta-analysis. *Eur J Surg Oncol* 2023;49:306–15.
- [9] Ang D, Shia J, Tang L, et al. The utility of immunohistochemistry in subtyping adenocarcinoma of the ampulla of Vater. *Am J Surg Pathol* 2014;38:1371–1379.
- [10] Zimmermann C, Wolk S, Aust D, et al. The pathohistological subtype strongly predicts survival in patients with ampullary carcinoma. *Sci Rep* 2019;9:12676.
- [11] Perkins G, Svrcek M, Bouchet-Doumenq C, et al. Can we classify ampullary tumours better? Clinical, pathological and molecular features. Results of an AGEO study. *Br J Cancer* 2019;120:697–702.
- [12] Reid M, Balci S, Ohike N, et al. Ampullary carcinoma is often of mixed or hybrid histologic type: an analysis of reproducibility and clinical relevance of classification as pancreatobiliary versus intestinal in 232 cases. *Mod Pathol* 2016;29:1575–85.
- [13] Agaram N, Shia J, Tang L, et al. DNA mismatch repair deficiency in ampullary carcinoma: a morphologic and immunohistochemical study of 54 cases. *Am J Clin Pathol* 2010;133:772–80.
- [14] Xue Y, Balci S, Mericco C, et al. Frequency and clinicopathologic associations of DNA mismatch repair protein deficiency in ampullary carcinoma: routine testing is indicated. *Cancer* 2020;126:4788–99.
- [15] Schiergens T, Reu S, Neumann J, et al. Histomorphologic and molecular phenotypes predict gemcitabine response and overall survival in adenocarcinoma of the ampulla of Vater. *Surgery* 2015;158:151–61.
- [16] Trikudanathan G, Njei B, Attam R, et al. Staging accuracy of ampullary tumors by endoscopic ultrasound: meta-analysis and systematic review. *Dig Endosc* 2014;26:617–26.
- [17] Olthof P, van Dam J, Groen J, et al. Screening for colorectal cancer after pancreatoduodenectomy for ampullary cancer. *Eur J Surg Oncol* 2020;46:534–538.
- [18] Schneider AR, Seifert H, Trojan J, et al. Frequency of colorectal polyps in patients with sporadic adenomas or adenocarcinomas of the papilla of Vater: an age-matched, controlled study. *Z Gastroenterol* 2005;43:1123–7.
- [19] Zhou F, He L, Tang D, et al. High frequency of colorectal neoplasia in patients with sporadic adenomas or adenocarcinomas of the papilla of Vater: the same adenoma-carcinoma sequence? *Dig Liver Dis* 2023;55:679–84.
- [20] Vanbiervliet G, Strijker M, Arvanitakis M, et al. Endoscopic management of ampullary tumors: European Society of Gastrointestinal Endoscopy (ESGE) guideline. *Endoscopy* 2021;53:429–48.
- [21] Napoléon B, Gincul R, Ponchon T, et al. Endoscopic papillectomy for early ampullary tumors: long-term results from a large multicenter prospective study. *Endoscopy* 2014;46:127–34.
- [22] Kang SH, Kim KH, Kim TN, et al. Therapeutic outcomes of endoscopic papillectomy for ampullary neoplasms: retrospective analysis of a multicenter study. *BMC Gastroenterol* 2017;17:69.
- [23] Ridditiid W, Tan D, Schmidt S, et al. Endoscopic papillectomy: risk factors for incomplete resection and recurrence during long-term follow-up. *Gastrointest Endosc* 2014;79:289–96.
- [24] Bohnacker S, Seitz U, Nguyen D, et al. Endoscopic resection of benign tumors of the duodenal papilla without and with intraductal growth. *Gastrointest Endosc* 2005;62:551–60.
- [25] Camus M, Napoléon B, Vienne A, et al. Efficacy and safety of endobiliary radiofrequency ablation for the eradication of residual neoplasia after endoscopic 566 papillectomy: a multicenter prospective study. *Gastrointest Endosc* 2018;88:511–18.
- [26] Lecomte T, Tougeron D, Chautard R, et al. Non-metastatic colon cancer – French Intergroup Clinical Practice Guidelines for diagnosis, treatments and follow-up (TNCD, SNFGE, FFCD, GERCOR, UNICANCER, SFCD, SFED, SFRO, ACHBT, SFP, AFEF, SFR). Thésaurus National de Cancérologie Digestive 2023. online [<https://www.snfge.org/content/3-cancer-du-colon-non-metastatique>].
- [27] Neoptolemos J, Moore M, Cox T, et al. Effect of adjuvant chemotherapy with fluorouracil plus folinic acid or gemcitabine vs observation on survival in patients with resected periampullary adenocarcinoma: the ESPAC-3 periampullary cancer randomized trial. *JAMA* 2012;308:147–56.
- [28] Nakashi K, Ikeda M, Konishi M, et al. Adjuvant S-1 compared with observation in resected biliary tract cancer (JCOG1202, ASCOT): a multicentre, open-label, randomised, controlled, phase 3 trial. *Lancet* 2023;401:195–203.
- [29] Ostwal V, Harris C, Sirohi B, et al. Role of adjuvant chemotherapy in T2N0M0 periampullary cancers. *Asia-Pacific J Clin Oncol* 2017;13:e298–303.

- [30] Stiles Z, Behrman S, Deneve J, et al. Ampullary adenocarcinoma: defining predictors of survival and the impact of adjuvant therapy following surgical resection for stage I disease. *J Surg Oncol* 2018;117:1500–8.
- [31] Nassour I, Hyman L, Christie A, et al. Association of adjuvant therapy with improved survival in ampullary cancer: a national cohort study. *J Gastrointest Surg* 2018;22:695–702.
- [32] Moekotte A, van Roessel S, Malleo G, et al. Development and external validation of a prediction model for survival in patients with resected ampullary adenocarcinoma. *Eur J Surg Oncol* 2020;46:1717–26.
- [33] Moekotte A, Malleo G, van Roessel S, et al. Gemcitabine-based adjuvant chemotherapy in subtypes of ampullary adenocarcinoma: international propensity score-matched cohort study. *Br J Surg* 2020;107:1171–82.
- [34] Colussi O, Voron T, Pozet A, et al. Prognostic score for recurrence after Whipple's pancreaticoduodenectomy for ampullary carcinomas; results of an AGEO retrospective multicenter cohort. *Eur J Surg Oncol* 2015;41:520–6.
- [35] Smeenk H, van Eijck C, Hop W, et al. Long-term survival and metastatic pattern of pancreatic and periampullary cancer after adjuvant chemoradiation or observation: long-term results of EORTC trial 40891. *Ann Surg* 2007;246:734–40.
- [36] Morak M, van der Gaast A, Incrocci L, et al. Adjuvant intra-arterial chemotherapy and radiotherapy versus surgery alone in resectable pancreatic and periampullary cancer: a prospective randomized controlled trial. *Ann Surg* 2008;248:1031–41.
- [37] Ecker B, Vollmer C, Behrman S, et al. Role of adjuvant multimodality therapy after curative-intent resection of ampullary carcinoma. *JAMA Surg* 2019;154:706–14.
- [38] Spadaccini M, Fugazza A, Frazzoni L, et al. Endoscopic papillectomy for neoplastic ampullary lesions: a systematic review with pooled analysis. *United European Gastroenterol J* 2020;8:44–51.
- [39] Winter JM, et al. Clinicopathologic analysis of ampullary neoplasms in 450 patients: implications for surgical strategy and long-term prognosis. *J Gastrointest Surg* 2010;14:379–87.
- [40] Sakai A, Tsujimae M, Masuda A, et al. Clinical outcomes of ampullary neoplasms in resected margin positive or uncertain cases after endoscopic papillectomy. *World J Gastroenterol* 2019;25:1387–97.
- [41] Lepage C, Phelip JM, Carry L, et al. Prognostic effect of imaging and CEA follow-up in resected colorectal cancer (CRC): final results and relapse free survival (RFS) - PRODIGE 13 a FFCO phase III trial LBA 28 presented at ESMO Paris; 2022. doi:10.1016/j.jannonc.2022.08.024.
- [42] Overman M, Varadhachary G, Kopetz S, et al. Phase II study of capecitabine and oxaliplatin for advanced adenocarcinoma of the small bowel and ampulla of Vater. *J Clin Oncol* 2009;27:2598–603.
- [43] Conroy T, Desseigne F, Ychou M, et al. FOLFIRINOX versus gemcitabine for metastatic pancreatic cancer. *N Engl J Med* 2011;364:1817–25.
- [44] Burris H, Moore M, Andersen J, et al. Improvements in survival and clinical benefit with gemcitabine as first-line therapy for patients with advanced pancreatic cancer: a randomized trial. *J Clin Oncol* 1997;15:2403–13.
- [45] Valle J, Wasan H, Palmer D, et al. Cisplatin plus gemcitabine versus gemcitabine for biliary tract cancer. *N Engl J Med* 2010;2010(362):1273–81.
- [46] Phelip JM, Desramé J, Edeline J, et al. Modified FOLFIRINOX versus CISGEM chemotherapy for patients with advanced biliary tract cancer (PRODIGE 38 AMEBICA): a randomized phase II study. *J Clin Oncol* 2022;40:262–71.
- [47] Marabelle A, Le DT, Ascierto P, et al. Efficacy of pembrolizumab in patients with noncolorectal high microsatellite instability/mismatch repair-deficient cancer: results from the phase II KEYNOTE-158 study. *J Clin Oncol* 2020;38:1–10.
- [48] Flecchia C, Auclin E, Alouani E, et al. Primary resistance to immunotherapy in patients with a dMMR/MSI metastatic gastrointestinal cancer: who is at risk? An AGEO real-world study. *Br J Cancer* 2023. doi:10.1038/s41416-023-02524-3.
- [49] Diaz L, Shiu K, Kim T, et al. Pembrolizumab versus chemotherapy for microsatellite instability-high or mismatch repair-deficient metastatic colorectal cancer (KEYNOTE-177): final analysis of a randomised, open-label, phase 3 study. *Lancet Oncol* 2022;23:659–70.